

A Clinicomycological Study of Pityriasis Versicolor with a Special Reference to the Calcofluor White Stain

JYOTI S KABBIN, D VIJAYA, MEERA D MEUNDI, B LEELAVATHY

ABSTRACT

Background: The mycological study of Pityriasis versicolor by doing Potassium hydroxide (KOH) wet mount preparations and cultures is simple, but both the techniques have their own limitations. The isolation of the organism is very difficult because it is lipophilic and it needs special media to grow, which takes time. The present study suggests that the Calcofluor white stain can be used for the preliminary identification of the fungal elements, so that clinicians can start with the treatment.

Aim: The aim of this study was to know the advantage of Calcofluor white staining versus the conventional methods which are used for the demonstration of the fungi in cases of Pityriasis versicolor.

Methods: Over a period of one year, from October 2004 to November 2005, a total of 100 clinically diagnosed cases of Pityriasis versicolor were referred from the Department of Dermatology to the Department of Microbiology, Bowring and Lady Curzon Hospital which is attached to the Bangalore Medical

College and Research Institute, Bangalore. Skin scrapings from affected lesions were processed by doing KOH preparations, Calcofluor white staining and cultures.

Results: Out of the 100 cases which were studied, the maximum number of cases were in age group of 12 to 21 yrs (51%). Males 71(71%) were affected more than females 29(29%). 98(98%) samples were positive for the fungi by Calcofluor white staining, 92(92%) by the KOH preparation and 46(46%) by culture.

Conclusion: Calcofluor white staining picked up an additional four samples which were reported as negative by the KOH preparation and the culture. Two other samples were reported to be positive by Calcofluor white staining and culture and to be negative by the KOH preparation.

Calcofluor white staining is a rapid, simple, sensitive and highly reliable method for identifying fungi, as it provides a good definition of the fine fungal structures and a better contrast from the background debris, cells and tissue fragments.

Key Words: Calcofluor white stain (CFW), Pityriasis versicolor, Potassium hydroxide (KOH) wet mount preparation

INTRODUCTION

Pityriasis versicolor is a cutaneous, superficial, fungal infection which is characterized by skin pigmentary changes due to the colonization of the stratum corneum by dimorphic, lipophilic fungi in the normal flora of the skin, which is known as *Malassezia furfur* [1]. The genus, *Malassezia*, has been recently shown to consist of seven species [2]. The one lipid independent species is *Malassezia pachydermatis* and the six lipid dependent species are *Malassezia furfur*, *Malassezia sympodialis*, *Malassezia globosa*, *Malassezia obtuse*, *Malassezia restricta*, and *Malassezia sloffiae*, which were identified by partial, ribosomal RNA sequence comparisons [3]. The aim of this study was to know the advantage of the Calcofluor white staining versus the conventional methods for the demonstration of fungi in cases of Pityriasis versicolor.

METHODS

This study was conducted over a period of one year from October 2004 to November 2005. A total of 100 clinically diagnosed cases of Pityriasis versicolor were referred from the Department of Dermatology, Bowring and Lady Curzon Hospital which is attached to the Bangalore Medical College, Bangalore. A detailed history elicitation and clinical examination were performed on each case. The affected skin area was thoroughly sponged with 70% alcohol to remove the surface contaminants. After drying, the active edges of the lesions were scraped with a flame sterilized, No. 15 scalpel

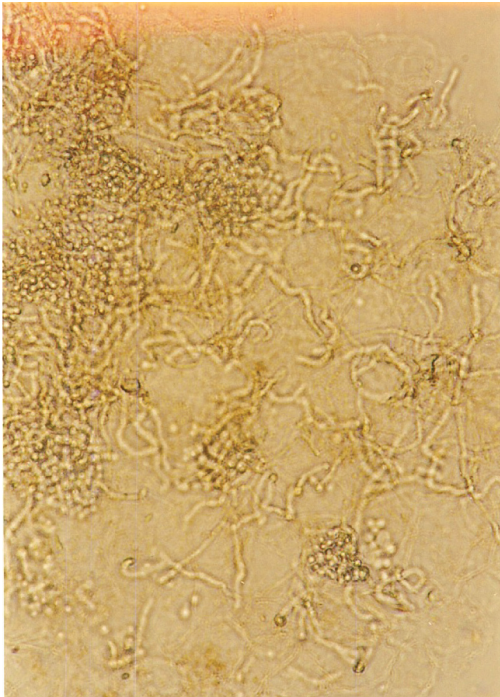
blade. The skin scrapings were processed by direct microscopic examination which included a 10% KOH preparation, a 10% KOH with Parker ink preparation, a 10% KOH with Methylene blue preparation and a Calcofluor white stain preparation. Two paired sets of Sabouraud's Dextrose Agar (SDA) with cyclohexamide, one paired set with olive oil and the other paired set without olive oil were inoculated and incubated for 2 weeks at 25°C and 37°C.

The results were compiled and statistically analyzed.


RESULTS

The study group comprised of 100 clinically diagnosed cases of Pityriasis versicolor. The ages of the study group subjects ranged from 11 to 42 years. A maximum number of patients (51%) belonged to the age group of 12-21 years. Males (71%) were affected more than the females (29%). Most of the patients were of the hypopigmented variety (67%) as compared to the hyperpigmented variety 31(31%) and 2(2%) patients were of mixed variety. The distribution of the skin lesions showed that they were seen more commonly on the chest and back [87(87%) and 13(13%)] over other sites like the face and the abdomen.

Out of the 100 suspected cases of Pityriasis versicolor, 92 (92%) were positive for the fungi by the KOH preparation, as shown in [Table/Fig-1], 98% were positive for fungi by Calcofluor white staining as shown in [Table/Fig-2] and 46(46%) were culture positive



[Table/Fig-1]: Potassium hydroxide preparation under high power showing numerous short, broad hyphae and clusters of budding cells, which have been described as having the appearance of "spaghetti & meat balls."



[Table/Fig-2]: Calcofluor white stain preparation viewed under fluorescent microscope showed apple green fluorescence of yeast cells and hyphae.

as shown in [Table/Fig-3]. Other tests which were used, that is, the Parker ink preparation and the Methylene blue preparation were similar to the KOH preparation in the detection of the organism, as shown in [Table/Fig-3].

DISCUSSION

Pityriasis versicolor is one of the most common disorders of pigmentation in the world [4]. In the tropical areas, it has been reported in 30 to 40% of the population and the incidence is lower in temperate climates (1 to 4%) [5]. The disease is usually brought to the physician's attention because of its cosmetic effects on the patient [6]. The commonest clinical species is thought to be *Malassezia furfur* [7,8]. The *Malassezia* species are fastidious fungi which require the addition of lipids to the culture media and which grow best at a temperature range of 32-37°C in an anaerobic environment [9]. Pityriasis versicolor occurs when yeast forms convert to their mycelial forms due to certain predisposing factors. The exogenous factors include heat, moisture and occlusion of the skin due to either clothing or cosmetics [2]. Occlusion results in an increased carbon dioxide concentration [10]. The endogenous factors include diseased states like seborrheic dermatitis, Cushing's syndrome, malnutrition and hyperhidrosis [11].

In our study, the lesions were most commonly seen in the age group of 12-21 (51%) years, as has been reported by other workers. Marple et al [12] found the incidence to be 49(49%) in adults, Belec et al [13] during their study, found that the maximum prevalence (23.5%) was in the age group of 15-25 years, Vijaya et al [14], found that the lesions were common in the age group of 21-30 years, (56%) and Rao et al [15] found in their study that 30% of the patients belonged to the age group of 21-30 years.

The disease may occur at any age, but it is more common during adolescence and in young adults due to an increase in the sebaceous activity [16] and hormonal changes.

The present study showed a pre-dominant involvement of males as compared to females, as in the following studies; Roberts et al [11]

Various Tests	Result	Percentage positive
CFW+ KOH mount /Methylene blue/Parker ink	48	48%
CFW+KOH/Methylene blue/Parker ink+Culture	44	44%
CFW+Culture	02	2%
CFW only	04	4%
All test Negative	02	2%
Total	100	100%

[Table/Fig-3]: Results of various tests like Calcofluor white (CFW), Potassium hydroxide (KOH) mount, Culture, Methylene blue and Parker ink of the total 100 tested

found the ratio of males to females to be about 3:2 among the patients in the United Kingdom, Kim and Suh et al [17] found it to be 2:1 among Korean patients, Belec et al [13] found that males were affected more than females, Vijaya et al [14] found more males (78%) than females (22%) among 100 patients and Rao et al [15] reported that more males (73.33%) were affected in comparison to the females (26.60%). The higher incidence of Pityriasis versicolor in males may be due to their outdoor activities [14]. The type of lesions were more hypopigmented (67%) than hyper pigmented (31%), which was similar to that which was reported in the study of Rao et al [15]. The distribution of the skin lesions commonly occurred over the chest and the upper back (87%) in our study among 100 patients. These observations were in conformity with the findings of Roberts et al, who found that 92% of the patients carried them on their trunk, Belec et al [13] who found that the lesions commonly occurred over the upper arm, and the trunk (48.6%), Vijaya et al [14], who found that the lesions were more common over the chest and the back (85%) and Rao et al [15] who found that the lesions were seen commonly over the back (70%) and the chest (58.30%). The distribution of the lesions generally parallels the density of the sebaceous gland distribution, with a greater occurrence on the chest and the back [18].

In this study, Calcofluor white staining was positive in 98(98%) patients as compared to the KOH preparation [92(92%) patients].

The causative agent was isolated in 46(46%) patients. Our results were in conformity with the findings of Maheswari et al [19], who found that 96% of the patients were positive for the KOH preparation out of 100 cases and that 70% patients were positive for culture, Shanker et al [20] who found that all their 100% cases were positive for KOH and that the culture yielded a positive growth only in 60% patients, Vijaya et al [14] in whose study, 42% out of 100 cases were positive for growth and Rao et al [15] who found 91% patients were positive for KOH and that 40% showed growth on SDA with oil. Kindo et al [21], during their study, found that 70% patients were positive KOH and that 68.75% patients showed growth on Dixon's agar.

Calcofluor white staining picked up an additional four samples which were reported as negative by KOH and culture. Two other samples were found to be positive by Calcofluor white staining and culture, which were reported as negative by the KOH preparation.

Calcofluor white staining is a rapid, simple, sensitive and a highly reliable method for identifying fungi, as it provides a good definition of the fine fungal structures and better contrast from the background debris [22], cells and tissue fragments. The disadvantage of fluorescent staining is that it requires a fluorescent microscope, expertise in reporting and is expensive. Laboratories will find that investing in a fluorescent microscope will yield better patient care [23]. To determine the clinical usefulness and characteristics of each test, Calcofluor white staining was chosen as the gold standard for statistical analysis [24].

To conclude, Calcofluor staining was found to be far superior to the conventional KOH preparation for the detection of fungi in clinical specimens.

ACKNOWLEDGMENT

The authors are thankful to the staff of the Microbiology Department, Bowring and L.C.Hospital which is attached to Bangalore Medical College, Bangalore, for their co-operation in this study.

REFERENCES

- [1] Michalwski R, Rodziewicz H. Pityriasis versicolor in children. *Br J Dermatol*. 1963;75:397-400
- [2] Chander J, Text Book of Medical Mycology, India: Mehta publishers, 2002, 2nd Edition.
- [3] Gueho E, Midgely G, Guillot J. The genus, *Malassezia* with a description of four new species. *Antonie Van Leeuwenhoek*. 1996; 69: 337-55.
- [4] Peter JS, Robert AS, Camila KJ. Tinea Versicolor. *Int J Dermatol Rev*. 1998; 37: 648-55.
- [5] Faergemann J, Aly R, Maibach HI. Other cutaneous yeast infections. Atlas of infection of the skin. Churchill Livingstone: Philadelphia. 1994:57-60.
- [6] Rippon WJ. The Pathogenic fungi and The Pathogenic Actinomycetes. *The Textbook of Medical Mycology*, London: W.B. Saunders Co. 1974: 84-7.
- [7] Kwon-Chung, Bennett J E. Infection caused by *Malassezia species*. *Textbook of Medical Mycology*, Philadelphia: Lea and Febiger. 1992: 170-82.
- [8] Laron DH. *Malassezia furfur*. Medically important fungi: a guide to their identification, 3rd Edition. Washington DC, ASM press. 1995; 83.
- [9] Anrzejewska E, Adamski Z. The mycological diagnostics of the lipophilic yeast, *Malassezia furfur*. *Postepy Dermatol (Poznan)* 1993;1223-28.
- [10] King RD, Cunico RL, Maibach HI. The effect of occlusion on carbon dioxide emission from the human skin. *Acta Derm Venereol (Stockh)* 1978;58:135-8.
- [11] Roberts SOB. Pityriasis versicolor: a clinical and mycological investigation. *British Journal of Dermatology* 1969; 81:315-26.
- [12] Marples MJ. The incidence of certain skin diseases in western Samoa; a pre-liminary survey. *Trans R Soc Trop Med Hyg* 1950; 44:319-32.
- [13] Belec L, Testa J, Bouree P. Pityriasis Versicolor in the Central African Republic; a randomized study on 144 cases. *Journal of Med Vet Mycol* 1991; 29(5):323-29.
- [14] Vijaya D, Nagarathnamma T, Anand Kumar BH, Rajesh R, Satish N, Savitha G, et al. Study of Pityriasis versicolor. *The Antiseptic* 1998; 95(4p): 133.
- [15] Rao GS, Kuruvilla M, Kumar P, Vinod V. Clinicoepidemiological studies on Tinea Versicolor. *Indian Dermatol Venereol Leprol*. 2002; 68: 208-09.
- [16] Habif TP. Clinical Dermatology. A colour guide to diagnosis and therapy. 4th edition, Philadelphia: Mosby. 2004; 451-6.
- [17] Kim HS, Suh M S. A clinical and mycological investigation on Tinea versicolor. *Korean Journal Mycol*. 1982;9:199-207.
- [18] Leeming JP, Notman FH, Holland KT. The distribution and the ecology of *Malassezia furfur* and the cutaneous bacteria on human skin. *J App Bactriol* 1989;67:47-52.
- [19] Maheswari AS. A mycological study of Tinea versicolor. *Indian J Med Res Rev* 1981;74:372-9.
- [20] Shanker Rao IV, Rajeashekar N, Lava R. Mycological study of Tinea versicolor. *Indian Journal of Dermatol Venereol Leprol* 1997;63: 168-69.
- [21] Kindo AJ, Sophia SK, Kalyani J, Anandan S. Identification of the *Malassezia species*. *Indian J of Med Microbiol*. 2004;22(3):179-81.
- [22] Koneman EW, Allen SD, Janda WM, Schreckenberger PC, Winn WC. Koneman's Colour Atlas and Textbook of Diagnostic Microbiology. 6th edition. JB Lippincot company: 26.
- [23] Jaber A, Glenn D, Robert. Direct microscopic examination of clinical specimens for the laboratory diagnosis of fungal infections. *Clinical Microbiology Newsletter*. December 1991;24:185-8.
- [24] Jeffery MW, Evelyn KK, William DT, Hillarie RT, Lily N. Comparison of the diagnostic methods which are used in the evaluation of onychomycosis. *J Am Acad Drmatol*. August 2003;49(2):193-7.

AUTHOR(S):

1. Dr. Jyoti S Kabbin
2. Dr. D Vijaya
3. Dr. Meera D Meundi
4. Dr. B Leelavathy

PARTICULARS OF CONTRIBUTORS:

1. M.D., Associate Professor
Department of Microbiology
Bowring & Lady Curzon Hospital
Bangalore- 560001.
2. M.D., Professor of Microbiology
Incharge, Departement Of Microbiology
Bowring & Lady Curzon Hospital
Bangalore- 560001.
3. M.D., Professor & HOD Department of Microbiology
Bangalore Medical College, Bangalore-560001.

4. M.D., Professor & HOD Dermatology
Bowring & Lady Curzon Hospital, Bangalore 560001.

NAME, ADDRESS, TELEPHONE, E-MAIL ID OF THE CORRESPONDING AUTHOR:

Dr. Jyoti S. Kabbin
H.No. 318, 3rd Floor
Sharavathi, B-4 Block
National Games Village
Koramangal, Bagalore-560042
E-mail: Drjyotiskabbin@gmail.com

DECLARATION ON COMPETING INTERESTS:

No competing Interests.

Date of Submission: Apr 11, 2011

Date of peer review: Aug 18, 2011

Date of acceptance: Sep 20, 2011

Date of Publishing: Nov 30, 2011