

JOURNAL OF CLINICAL AND DIAGNOSTIC RESEARCH

How to cite this article:

AMBIKA G,SHIKHA K, PREMDEEP G, VIRENDRA S. MAXILLARY OSTEOMYELITIS SECONDARY TO OSTEOPETROSIS - A RARE CASE REPORT. Journal of Clinical and Diagnostic Research [serial online] 2010 October [cited: 2010 October 31]; 4:3261-3265.

Available from

http://www.jcdr.in/article_fulltext.asp?issn=0973-709x&year=2010&volume=&issue=&page=&issn=0973-709x&id=982

CASE REPORT

Maxillary Osteomyelitis Secondary To Osteopetrosis – A Rare Case Report

AMBIKA G*, SHIKHA K**, PREMDEEP G***, VIRENDRA S****

ABSTRACT

Osteomyelitis of the mandible at a young age may occur as a complication of immunocompromised status or bone disorders. Osteomyelitis rarely occurs in the maxilla due to thin bone and collateral blood supply of the maxillary bone. We report here, a rare case of maxillary osteomyelitis that led to the diagnosis of the underlying condition of osteopetrosis. The clinical and radiographical features are being discussed here, along with the relevant review of literature.

KEY WORDS: Osteopetrosis, maxilla, osteomyelitis

*M D S, Assistant Professor, **MDS, Assistant Professor, ***MDS, Assistant Professor, ****MDS, Professor, Department of Oral and Maxillofacial Surgery, Government Dental College, Pandit BD Sharma UHS, Rohtak, Haryana, India.

Corresponding Author:

Dr. Ambika Gupta
Assistant Professor,

Department of Oral Medicine and Radiology,
Government Dental College, Pandit B.D.Sharma
U.H.S, Rohtak, Haryana, India.
E mail id- drambika79@rediffmail.com
Phone no: +91- 9315903300, +91-1262- 212614
Fax no: +91- 1262- 212648

Introduction

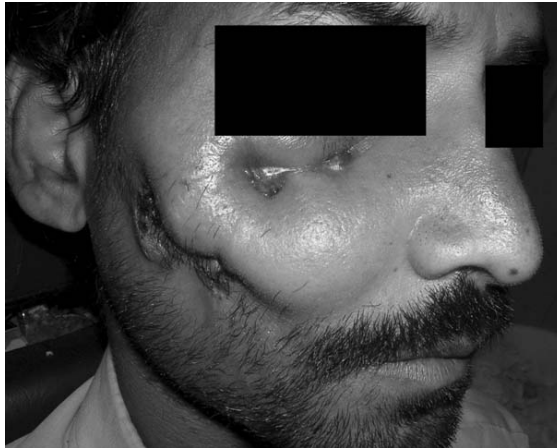Osteopetrosis, also known as Albers-Schonberg's disease or Marble bone disease, is a group of rare hereditary skeletal disorders which are characterized by a marked increase in bone density, resulting from a defect in remodeling, caused by the failure of normal osteoclast function. [1] There is overgrowth and sclerosis of the bone, causing thickening of the cortices and narrowing of the marrow spaces. The prevalence of this disorder is estimated to be 1 in 100,000 to 1 in 500,000. The disease may present clinically in a variety of subtypes. However, the two major clinical presentations are the infantile form (autosomal recessive, malignant form) and the adult form (autosomal dominant, benign form). Both forms are characterized by a decreased vascularity of the involved bones that predisposes the patient to the development of osteomyelitis. Osteomyelitis may occur as a complication to odontogenic infections in almost 10% of the cases. [2] Osteomyelitis secondary to Osteopetrosis is more common in the mandible than in the

maxilla due to thin cortical bone and a rich collateral blood supply to the maxilla. [3]

We report here, a rare case of osteomyelitis of the maxilla in a young male with osteopetrosis, that occurred secondary to the extraction of teeth.

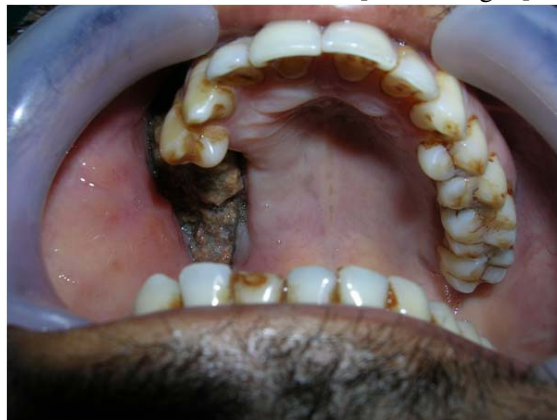Case Report

A 28 year old male reported to the department with a seven month history of a non healing wound in the maxilla. There was a history of trauma nine months ago, following which the patient had pain in the maxillary right teeth. The pain was accompanied by a swelling in the right cheek region. He went to a private dentist who extracted his maxillary right molars. The patient reported that the site of extraction did not heal even after taking repeated courses of antibiotics. Pus discharge was present extraorally from the right infraorbital and the zygomatic regions and intraorally from the right maxillary posterior region since three months.



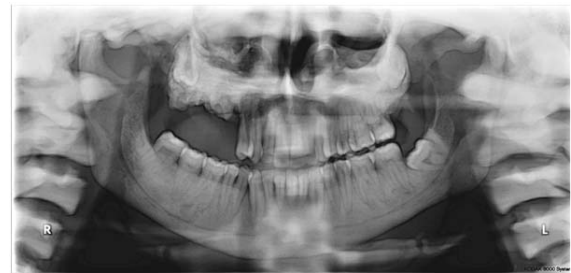[Table/Fig 1]: Extra oral view of the patient showing extent of swelling and extraoral sinuses.

The patient was a chronic tobacco chewer since five years. The medical history of the patient was non contributory and the vital signs were stable. Inspection revealed a diffuse irregular swelling on the right side of the maxilla and the zygoma, approximately 5 x 4 cm in size, with multiple discharging sinuses and erythema on the right cheek and the infraorbital region. The swelling was bony hard in consistency, with signs of inflammation. The right lower eyelid was stretched due to a puckered appearance around the infraorbital sinuses.[Table/ Fig. 1]



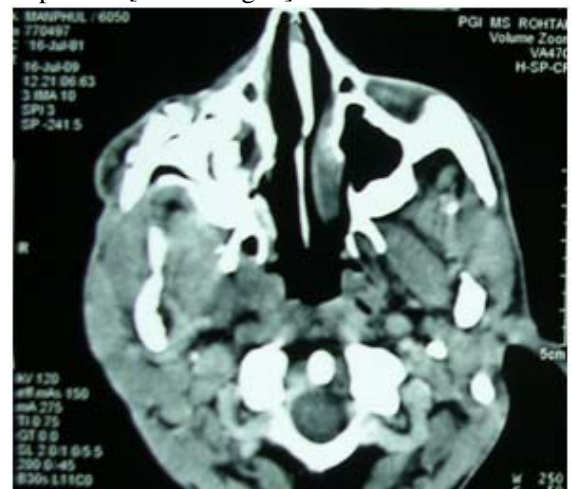
[Table/Fig 2]: Intraoral view showing the necrosed bone at the site of extraction.

Intra oral examination revealed a mucosal defect in the right maxillary molar region, with exposed necrotic bone extending upto the maxillary tuberosity. The right maxillary molars were missing. [Table/Fig.2] The radiographical examination of the jaws was done.



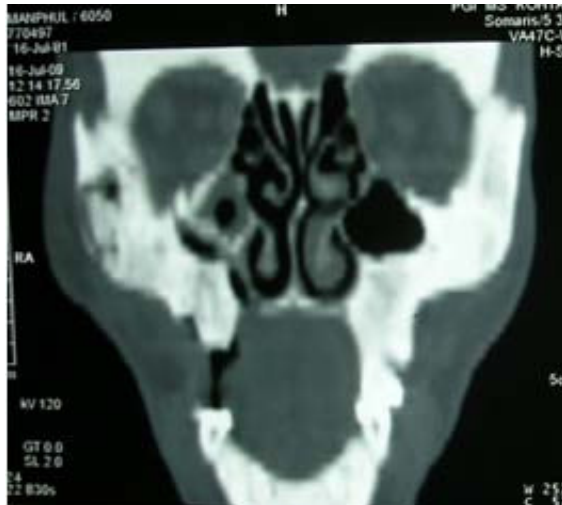[Table/Fig 3]: Pantomograph revealing increased density of maxilla and mandible with extensive osteosclerosis in right maxilla.

The trabecular architecture was fine and it was increased in number and density in both the maxilla and the mandible on pantomography. Distinct cortical outlines of the inferior and the posterior border of the mandible, the inferior alveolar canal, the maxillary antrum, the nasal cavity and the lamina dura around the teeth were not traceable. There was a generalized narrowing of the periodontal ligament spaces and the inferior alveolar canal. An increased sclerosis of bone was evident in the right maxilla with irregular ragged margins. 18, 28 and 38 were impacted. [Table/ Fig. 3]



[Table/Fig 4]: Thickened soft tissue in right maxillary alveolar region, right masticator space involving the right masseter and medial and lateral pterygoid muscles, with loss of fat planes.

The paranasal sinus view showed extensive osteosclerosis. [Table/Fig. 5] CT scan revealed a generalized increased density of the visualized skull and facial bones.



[Table/Fig 5]: Coronal CT section showing osteosclerosis of bones and obliteration of maxillary sinus.

Irregularity of bone was seen in the right maxilla with the erosion of the buccal cortex of the right maxilla, the adjacent zygomatic bone, the lateral wall of the right orbit, the antero lateral wall of the right maxillary sinus and the maxillary alveolus, causing a breach in the continuity of the maxillary alveolus in the midline. Soft tissue thickening was present in the right maxillary antrum and along the right side of the hard palate with periosteal reaction. [Table/Fig 4,5] Axial CT revealed a heterogenous enhancement of the thickened soft tissue in the right maxillary alveolar region, the right masticator space involving the right masseter and the medial and the lateral pterygoid muscles, with loss of the fat planes. [Table/Fig 4] The frontal sinus was underpneumatized for his age. On the basis of the radiographical evaluation, a diagnosis of Osteopetrosis with infective osteomyelitis of the right maxilla was given. The patient was referred for further work up.

Ultrasonography of the abdomen revealed massive enlargement of the spleen (25 cm), with mild hepatomegaly (14 cm). The routine blood tests showed alteration of haemoglobin levels (Hb-6.7gm/dl) and haematocrit was 25%. The red blood cells were microcytic and hypochromic. Other parameters were within normal limits (leukocytes: 6,800/cumm with 2% atypical cells and normal differential count; platelets: 2,34,000/cubic mm). His liver and renal function tests were normal. Bone marrow aspiration was pancellular and diluted, leading to

no further conclusion. The serum calcium, phosphorus, alkaline phosphatase and acid phosphatase levels were normal. Chest radiograph and long bone revealed a generalized increased density of the visualized bones.

A biopsy from the oral lesion revealed necrotic material with bacterial and fungal colonies, with acute and chronic inflammatory granulation tissue, with tiny strips of stratified squamous epithelium. Based on the culture sensitivity report, the patient was given oral ciprofloxacin 500 mg, twice daily for 15 days. This was followed by local debridement and sequestrectomy. Partial maxillectomy was subsequently planned for the patient. But, the patient refused any further treatment. He was asymptomatic for the next 3 months, after which he did not follow up.

Discussion

Adult osteopetrosis is usually discovered later in life than the infantile form and exhibits less severe manifestations. [1] It is usually inherited as an autosomal dominant trait. Mostly, the axial skeleton is involved. Adult osteopetrosis may exist clinically in two major variants. In Type I, cranial nerve compression is a predominant feature and in Type II, skeletal fractures occur more frequently than nerve compression. In the present case, the patient had no signs of osteopetrosis at birth or in early infancy. There was no history of recurrent bone fractures, visual or auditory disturbances, or facial palsy. The examination revealed no facial deformity or delayed tooth eruption. Therefore, a diagnosis of adult osteopetrosis was made. The clinical presentation of osteomyelitis at the site of extraction was the first manifestation of his disease.

Radiographical examination plays a vital role in the diagnosis of Osteopetrosis. There is an increased radiopacity of the entire skeleton, resulting in diffuse, homogenous and sclerotic bones. The normal trabecular pattern may not be visualized due to the excessive density of the bones. The normal landmarks of the skull are lost. There is narrowing of the foramina of the skull, leading to the compression of the cranial nerves and blood vessels. On dental radiographs, the morphology of the roots is obscured due to the presence of dense bones. Lamina dura

around the teeth is not traceable. Other dental findings include the delayed eruption of teeth, early tooth loss, impacted teeth, malformed teeth, partial anodontia, enamel hypoplasia, abnormal pulp chambers and a tendency for the early decay of teeth.[4] In the present case, there was extensive osteosclerosis of the entire skeleton. The inferior alveolar canal was narrowed. However, the patient had no signs of paraesthesia or anaesthesia. The lamina dura was not traceable around the teeth. Thickening of the adjacent soft tissue and loss of the muscle planes and the periosteal reaction were suggestive of an infective aetiology. Osteopetrosis may be differentiated from other bone diseases like polyostotic fibrous dysplasia, Paget's disease, infantile cortical hyperostosis, pyknodysostosis and florid cemento- osseous dysplasia by the fact that osteopetrosis usually involves the entire skeleton. Skeletal fluorosis and secondary hyperparathyroidism may also result in a similar radiographical appearance. The presence of osteosclerosis and pathological fractures on radiograph have been reported to be sufficiently characteristic of Osteopetrosis. [5] The structural weakness associated with poorly organized bone and the persistent accumulation of immature bone and calcified cartilage have been postulated as the possible reason behind the pathological fractures. [6] The compromised vascularity of the bones and the decreased amount of intraosseous haematopoietic marrow that causes anaemia and neutropaenia may predispose the patient to osteomyelitis. [7] Both these findings were positive in our case, which could have predisposed to the development of osteomyelitis after the extraction. The incidence of osteomyelitis in the jaws increases with the presence of odontogenic infections and surgical intervention.

The serum levels of calcium, phosphorus and alkaline phosphatase are usually within the normal limits. The serum acid phosphatase levels are commonly elevated in the infantile, intermediate and the adult type II forms of the disease. In the present case, the serum levels of calcium, phosphorus, alkaline phosphatase and acid phosphatase were normal.

Although the diagnosis of Osteopetrosis is easy to make, the real challenge lies in the treatment

of this disease. Bone marrow transplantation is the only hope for the permanent cure of Osteopetrosis. Other treatment modalities like interferon gamma -1b and calcitriol have shown some benefits in reducing the bone mass, thereby preventing other complications like osteomyelitis and nerve compression. Other therapeutic avenues like corticosteroids, parathormone, macrophage colony stimulating factor, erythropoietin and dietary calcium restriction have also been suggested to play some roles. [8-11]

Osteomyelitis is a well recognized complication of Osteopetrosis. In some cases, osteomyelitis may be the first presentation of this disease, as was present in our case. [12] Osteomyelitis secondary to Osteopetrosis is mostly refractory to various treatment modalities like incision and drainage, antibiotic therapy and surgical procedures such as sequestrectomy, saucerization and decortication. High dose and prolonged systemic antibiotic therapy with fluoroquinolones and lincomycin are considered to be helpful. [13,14] The only methods that have proved to be helpful are the resection of the jaws and hyperbaric oxygen. The surgical defect is filled by the fabrication of the obturators.[5] Bone grafts and myo-osseous flaps are not feasible in such cases because of the compromised vascular supply and the lack of suitable donor sites.[15] Surgical intervention is limited to necessary extraction with antibiotic coverage, incision and drainage and possible palliative debridement. [7] The Pubmed search of English literature revealed different therapeutic modalities for the management of Osteopetrosis induced osteomyelitis, with variable outcomes. [Table/Fig 6]

AUTHORS	THERAPY	OUT COME OF THERAPY
Itzen-Toller M et al [16]	Systemic sulfamucillin 750 mg and omidazole 500 mg BD, followed by sequestrectomy, saucerization and closure of osseous opening.	Successful. No recurrent infections during the follow-up of 2 years.
Opashri RK et al [17]	Sinus tract excision and curettage of lesion	Not mentioned
Chattopadhyay P et al [18]	Systemic antibiotic therapy with sequestrectomy and saucerization. Sinus tract was also excised and the jaw remodelled.	Successful. No recurrence of the sinus two months postoperatively.
Eriz R et al [19]	Case 1- Systemic cefazolin and metronidazole followed by debridement and decontamination. Case 2- Systemic cefazolin and metronidazole. Tooth extraction, incision and drainage of the abscess, debridement, and decontamination performed. Topical phenytoin was given on relapse.	Case 1- Relapse in the same side and disease progression in another side of the mandible. Case 2- Relapse after 5 months. No signs and symptoms of infection after treatment of relapse.
Thuka C et al [7]	Case 1- Blood transfusion with systemic antibiotic (amoxicillin and clavulanic acid) and corticotomy. Case 2- Intravenous cefotaxime along with sequestrectomy.	Case 1- Uneventful healing in one month post operative follow up. Case 2- Asymptomatic for 1 year.

With the availability of newer and better antibiotics, the incidence of osteomyelitis has been reduced dramatically, even in the elderly. The presence of osteomyelitis in a young healthy patient should prompt the clinician to look for some underlying bony pathosis or predisposing immunocompromised status.

References

- [1] Waldron CA. Bone pathology. In : Neville BW, Damm DD, Allen CM, Bouquot JE, editors. Oral and maxillofacial pathology. 2nd ed. Philadelphia: Saunders; 2002. p. 535-7.
- [2] Johnston C, Lavy N, Lord T, Vellios F, Merritt AD, Deiss WP. Osteopetrosis: a clinical, genetic, metabolic, and morphologic study of the dominantly inherited, benign form. *Medicine* 1968; 47: 149-67.
- [3] Barry CP, Ryan CD. Osteomyelitis of maxilla secondary to osteopetrosis: report of a case. *Oral Surg Oral Med Oral Pathol Oral Radiol Endod* 2003; 95: 12-5.
- [4] Emmering TE, Wood NK. Generalized radiopacities. In: Wood NK, Goaz PW. Differential diagnosis of Oral and Maxillofacial lesions. 5th ed. St. Louis: Mosby 1997. p. 512-6.
- [5] Crockett DR, Stanley RB, Lubka R. Osteomyelitis of the maxilla in a patient with osteopetrosis (Albers-Schonberg disease). *Otolaryngol Head Neck Surg* 1986; 95: 117-21.
- [6] Kovanlikaya A, Loro ML, Gilsanz V. Pathogenesis of osteosclerosis in autosomal dominant osteopetrosis. *Am J Roentgenol* 1997; 168: 929- 32.
- [7] Krithika C, Neelakandan RS, Sivapathasundaram B, Koteeswaran D, Rajaram PC, Shetkar GS. Osteopetrosis associated osteomyelitis of the jaws: a report of 4

cases. *Oral Surg Oral Med Oral Pathol Oral Radiol Endod* 2009; 108: e56-e65.

- [8] Key LL, Ries WL. Osteopetrosis: the pharmacophysiologic basis of therapy. *Clin Orthop* 1993; 294: 85-9.
- [9] Juggins KJ, Walton GM, Patel M. Osteomyelitis complicating osteopetrosis: a case report. *Dent Update* 2001; 28:509-11.
- [10] Key LL Jr. Osteopetrosis: a genetic window into osteoclast function. In: Jackson DA, Editor. Cases in metabolic bone disease, New York: Triclinica Communications; 1987.p.1.
- [11] Key LL, Rodriguez RM, Willi SM, Wright NM, Hatcher HC, Eyre DR et al. Long-term treatment of osteopetrosis with recombinant human interferon gamma. *N Engl J Med* 1995; 332:1594-9.
- [12] Hanada T, Furuta S, Moriyama I, Hanamura Y, Miyahara T, Ohya M. Maxillary osteomyelitis secondary to osteopetrosis. *Rhinology* 1996; 34: 242-44.
- [13] Er N, Kasaboglu O, Atabek A, Oktemer K, Akkocaoglu M. Topical phenytoin treatment in bimaxillary osteomyelitis secondary to infantile osteopetrosis: report of a case. *J Oral Maxillofac Surg* 2006; 64:1160-4.
- [14] Von Rosenstiel N, Adam D. Quinolone antibacterials: an update of their pharmacology and therapeutic use. *Drugs* 1994; 47: 872-901.
- [15] Bakeman R, Abdelsayad R, Sutley S, Newhouse R. Osteopetrosis: a review of the literature and report of a case complicated by osteomyelitis of the mandible. *J Oral Maxillofac Surg* 1988; 56: 1209-13.
- [16] Oğütten-Toller M, Tek M, Sener I, Bereket C, Inal S, Özden B. Intractable bimaxillary osteomyelitis in osteopetrosis: review of the literature and current therapy. *J Oral Maxillofac Surg.* 2010; 68:167-75.
- [17] Roopashri RK, Gopakumar R, Subhas BG. Osteomyelitis in infantile osteopetrosis: a case report with review of literature. *J Indian Soc Pedod Prev Dent.* 2008;26 Suppl 3:S 125-8.
- [18] Chattopadhyay P, Kundu AK, Saha AK, Karthak RO. Mandibular osteomyelitis and multiple skeletal complications in Albers-Schönberg disease. *Singapore Med J.* 2008 ;49:e229-33.
- [19] Tabrizi R, Arabi AM, Arabion HR, Gholami M. Jaw osteomyelitis as a complication in osteopetrosis. *J Craniofac Surg.* 2010 ; 21:136-41.
- [20] Barbaglio A, Cortelazzi R, Martignoni G, Nocini PF. Osteopetrosis complicated by osteomyelitis of the mandible: a case report including gross and microscopic findings. *J Oral Maxillofac Surg.* 1998;56:393-8.
- [21] Trivellato AE, Ribeiro MC, Sverzut CE, Bonucci E, Nanci A, de Oliveira PT. Osteopetrosis Complicated by Osteomyelitis of the Maxilla and Mandible: Light and Electron Microscopic Findings *Head and Neck Pathol* .2009; 3:320-326.