

Bilateral Adrenal PNET: A Rare Presentation

SANTOSH KUMAR¹, VIJAYANT GOVINDA², SHRAVAN KUMAR SINGH³, JYOTSANA SINGH⁴

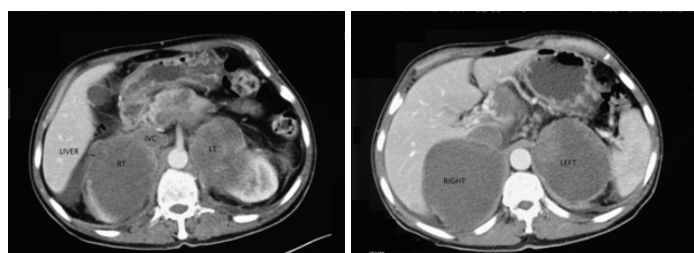
ABSTRACT

Primitive neuroectodermal tumours or PNET's are rare, malignant tumours with aggressive course and extremely poor prognosis. They have no sex preference. They arise mostly in the second decade of life. They are believed to be of neural crest origin and carry the name primitive because majority of the neuronal cells in these tumours appear undifferentiated. Solid organ origin is very rare and tumours arising from the adrenals are very infrequent. We report a case of metastatic bilateral adrenal PNET in a 45-year-old man. We believe this to be the first such case reported in the urological literature.

Keywords: Adrenal tumour, Neural crest origin, Primitive neuroectodermal tumour

CASE REPORT

A 45-year-old male patient reported to the emergency department with complaints of abdominal pain of 5 weeks duration. The pain was constant, dull aching and localized to the upper abdomen. He had associated complaints of increasing lower limb edema since 2 weeks and significant weight loss. Examination findings were essentially normal except for cachexia. On investigation urine examination was normal with no microscopic haematuria. Ultrasonography revealed bilateral large heteroechoic masses which could not be definitively localized to the renal/suprarenal origin. Contrast Enhanced Computed Tomography was performed which revealed bilateral large heterogenous, well circumscribed, capsulated, enhancing, non calcified, solid lesions. Adrenals were not separately visualized [Table/Fig-1]. The right side lesion measured 9.6X9.4x9.3cm with liver infiltration and the left side lesion measured 8.8x8.6x7.6 cm without adjacent organ infiltration. There was bilateral extension of the tumour into the adrenal veins with the right sided lesion extending into the IVC. Multiple enlarged lymph nodes were seen in the retroperitoneal and peripancreatic regions. On CECT imaging of the chest, multiple enhancing lung nodules were seen. These lesions were not biopsied because of the poor general condition of the patient. Biochemical evaluation of the patient for Adrenal Cortical Carcinoma/Pheochromocytoma, which included serum cortisol, Urinary VMA and fractionated metanephrines, was negative. From bilateral lesions an ultrasonographically directed core cut biopsy was obtained. The biopsy microscopically showed small blue cells arranged in nests and Homer Wright rosettes which on immunohistochemistry showed positivity for Neuron Specific Enolase and CD99. Also the staining for cytokeratin was negative [Table/Fig-2]. Diagnosis of PNET was obtained and after retrospective review of literature, a bone scan and central nervous system imaging (which were negative) was obtained to confirm the adrenal as the primary site for the tumour.

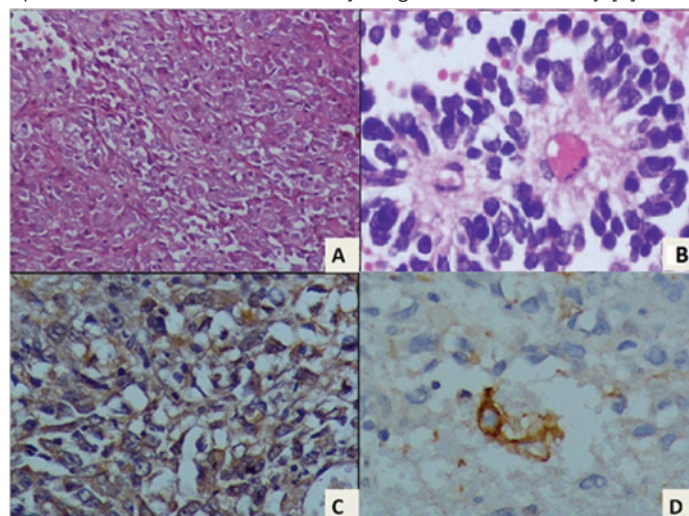


[Table/Fig-1]: Computed Tomography showing liver, Inferior Vena Cava (IVC) and Right (R) and Left (L) lesions replacing the adrenals.

DISCUSSION

Bilateral adrenal PNET has never been reported in literature before. PNET arising from the adrenal are rare entities with very limited mature literature describing them or their management. Even though PNET have been described with equal gender predisposition, there is age preponderance for younger age groups [1]. Very few cases are reported for older age groups. Our case of adrenal PNET is the oldest reported according to our knowledge and review of literature.

Diagnosis of adrenal PNET is usually a diagnosis of exclusion. Because of the rarity of the disease few even think of the diagnosis in the differential let alone actively seek it. In our case also we pursued the more common entities of adrenocortical carcinoma and pheochromocytoma until the histopathology evidence directed us otherwise. PNET was first described by Stout in 1918 [2] and is a histopathological diagnosis. It belongs to the family of Ewing Sarcoma with both tumours showing positivity for CD99 but only PNET show positivity for NSE [3]. Criteria are not well defined but majority concur that the presence of small blue cells arranged in nest and rosettes with positivity for atleast CD99 and Neuron Specific Enolase to be sufficiently diagnostic of the entity [4].



[Table/Fig-2]: Photomicrographs of the tumour showing A) medium sized round to oval tumour cells arranged in nests having moderate amount of pale eosinophilic cytoplasm and finely dispersed nuclear chromatin. (H&E, X240), B) High power photomicrograph show tumour cells arranged in rosettes. (H&E, X500) C) Photomicrograph of the tumour to show cytoplasmic staining for Neuron specific enolase. (Peroxidase anti-peroxidase X500). D) Photomicrograph of the tumour to show many tumour cells exhibiting cytoplasmic staining for CD99. (Peroxidase anti-peroxidase, X500).

Radiological features are also not well defined but on retrospective evaluation, our case carries most of the features of PNET described on Tomography. Large size, presence of heterogeneity, heterogenous enhancement, with organ and vascular invasion and absence of calcification and internal septations and cysts concur with published literature on this subject [5].

Since adrenal PNET is a rare diagnosis with very few cases reported, there is lack of a robust treatment protocol. The same treatment regimes as employed for Ewings Sarcoma (VAC alternated with IE) are employed but the aggressive course and presence of metastasis at presentation limit clinical utility [6]. Our case presented with very advanced disease and palliative chemotherapy regimen is being tried.

CONCLUSION

Even though adrenal PNET is a very rare diagnosis and bilateral presentation is even rarer, it should be kept in the differential diagnosis of adrenal masses.

REFERENCES

- [1] Dutta D, Shivaprasad K, Das R, Ghosh S, Chowdhury S. Primitive neuroectodermal tumour of adrenal: Clinical presentation and outcomes. *J Can Res Ther.* 2013;9(4):709.
- [2] Nirmal T, Kumar R, Kekre N, Phukan C. Peripheral primitive neuroectodermal tumour of the adrenal gland: A rare entity. *Indian Journal of Urology.* 2013;29(4):357.
- [3] Jürgens H, Etspüler G, Göbel U, Bier V, Brandeis W, Harms D, et al. Malignant peripheral neuroectodermal tumours. A retrospective analysis of 42 patients. *Cancer.* 1988;61(2):349-57.
- [4] Demir A, Gunluoglu M, Dagoglu N, Turna A, Dizdar Y, Kaynak K, et al. Surgical Treatment and Prognosis of Primitive Neuroectodermal Tumours of the Thorax. *Journal of Thoracic Oncology.* 2009;4(2):185-92.
- [5] Zhang Y, Li H. Primitive Neuroectodermal tumours of adrenal gland. *Jpn J Clin Oncol.* 2010;40:800-04.
- [6] Kim M, Kim B, Park C, Song S, Lee E, Park N, et al. Radiologic Findings of Peripheral Primitive Neuroectodermal Tumour Arising in the Retroperitoneum. *American Journal of Roentgenology.* 2006;186(4):1125-32.

PARTICULARS OF CONTRIBUTORS:

1. Assistant Professor, Department of Urology, PGIMER, Chandigarh, India.
2. Senior Resident, Department of Urology, PGIMER, Chandigarh, India.
3. Professor, Department of Urology, PGIMER, Chandigarh, India.
4. Clinical Attaché, Department of Urology, PGIMER, Chandigarh, India.

NAME, ADDRESS, E-MAIL ID OF THE CORRESPONDING AUTHOR:

Dr. Santosh Kumar,
Advanced Urology Centre, Department of Urology, PGIMER, Chandigarh, India.
E-mail: santoshp1967jaimatadi@yahoo.co.in

Date of Submission: **Mar 16, 2014**

Date of Peer Review: **Jun 07, 2014**

Date of Acceptance: **Dec 21, 2015**

Date of Publishing: **Sep 01, 2016**

FINANCIAL OR OTHER COMPETING INTERESTS: None.