

# Insulinoma Causing Prolonged Hypoglycaemic Coma

PRABHAT KUMAR<sup>1</sup>, AJAY CHAUHAN<sup>2</sup>, JUHI DIXIT<sup>3</sup>, JYOTSANA<sup>4</sup>, HARISH GUPTA<sup>5</sup>

## ABSTRACT

Insulinoma is a rare pancreatic endocrine tumour with an incidence of four cases per million per year. A recurrent episode of fasting hypoglycaemia is the most common manifestation of these tumours. Diagnosis is often delayed due to varied presentation but once diagnosed, prognosis is often good after surgical resection of the lesion. Severe hypoglycaemia in insulinoma causing coma and death is rare. We report a case of hypoglycaemic coma secondary to an insulinoma in an elderly man which proved fatal.

**Keywords:** C-peptide, Nesidioblastosis, Whipple's triad

## CASE REPORT

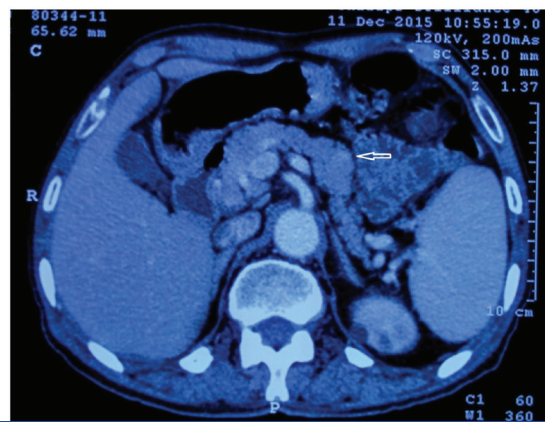
A 70-year-old gentleman came to visit his dentist in OPD without having his breakfast and while waiting for his turn he developed palpitations, sweating followed by confusion and altered sensorium. He was immediately rushed to the emergency department. He had one similar episode about a month back when he had kept fast on a festival day and was taken to a nearby hospital where his symptoms improved after intravenous glucose administration. He was not taking any medications for diabetes or hypertension and was a non smoker and non alcoholic.

On physical examination, he had BMI of 23.5 kg/m<sup>2</sup>, pulse rate was 110/minute, blood pressure in supine position was 140/90 mmHg and had respiratory rate of 20/minute. He was drowsy and was not arousable to deep painful stimuli. Blood sugar measured by glucometer was 40 mg/dl, to confirm a blood sample was also sent to the laboratory which showed blood sugar levels of 30 mg/dl. A sample for serum insulin levels and C-peptide levels were also drawn simultaneously and sent to the institute laboratory. He was administered 25 percent dextrose solution and his symptoms resolved immediately. His other investigations like haemogram, kidney function tests, liver function tests and serum electrolytes were absolutely normal. His plasma C-peptide level was 11.25 ng/ml (Normal-0.8 to 3.85 ng/ml) and plasma insulin level was 6.2 mU/ml (Normal-3 to 25 mU/ml). Serum cortisol and TSH levels were within normal limits and urine for sulfonylurea screen was negative.

An ultrasound of abdomen was done which revealed a hypoechoic lesion in the tail of pancreas with dilated main pancreatic duct (4.5mm). Contrast Enhanced Computed Tomography (CECT) of abdomen showed bulky tail of pancreas with focal contour bulge on the superior margin which appeared mildly hyperenhancing than normal parenchyma, suggestive of islet cell tumour [Table/Fig-1].

A diagnosis of insulinoma was made and the patient was advised surgical resection of the tumour. He was unwilling for surgery and did not give consent for the procedure. He was discharged from the hospital and was explained risk of hypoglycaemia in future. He was also advised to take food at regular intervals and not to assume fast for prolonged hours.

After two weeks, he was found unconscious in his room by his family members in the wee hours. According to them, he had fight with someone a day before and had gone to sleep without taking his dinner. They even tried to feed him in unconscious state but there was no improvement in his condition. He was then brought to the emergency department of our hospital. He was assessed in emergency department and was found to be having a GCS of 3. His pulse rate was 130/minute, blood pressure was 150/80 mmHg and



**[Table/Fig-1]:** CECT Abdomen showing bulky tail of pancreas with an enhancing lesion on superior margin (arrow).

had respiratory rate of 26/minute. His pupils were slightly dilated and sluggishly reactive to light. There were no signs of meningeal irritation but bilateral plantar reflex were extensor. On auscultation of chest, crepitations were noted on both sides of lung field. His blood sugar level was 25 mg/dl and other blood investigations were normal. Non contrast CT scan of head was done which showed lacunar infarcts in bilateral basal ganglia and chest X ray showed opacities in bilateral middle and lower zone. EEG showed no electrical activity in brain. A diagnosis of hypoglycaemic coma with aspiration pneumonia was made and he was administered continuous dextrose solution and broad spectrum antibiotics. However, the next day he developed respiratory distress for which he was intubated and put on mechanical ventilation. He succumbed to his illness on third day of admission due to sepsis and septic shock.

## DISCUSSION

Hypoglycaemia is commonly seen in diabetic patients but is very unusual in patients who are non diabetic. Hypoglycaemia is characterized by Whipple's triad which includes a low plasma glucose levels, symptoms of hypoglycaemia and resolution of symptoms after correction. Patients who satisfy Whipple's triad for hypoglycaemia should be evaluated further to find out the underlying cause of hypoglycaemic episode. Symptoms of hypoglycaemia are divided in two categories; neuroglycopenic and neurogenic (autonomic). Neuroglycopenic symptoms are due to decreased supply of glucose to the brain and include symptoms like confusion, behavioral changes, seizures, coma and even death in severe hypoglycaemia. Neurogenic symptoms are due to sympathoadrenal discharge and symptoms like palpitations, tremors, sweating, hunger, paresthesia are seen.

Hypoglycaemia can be further classified into fasting and postprandial hypoglycaemia. The probable causes of fasting hypoglycaemia are drugs (alcohol, insulin, and insulin secretagogues), hormonal deficiency (Addison's disease, glucagon deficiency), critical illness (sepsis, hepatic and cardiac failure), non beta-cell tumours (hepatoma, lymphomas, leukaemia) and endogenous hyperinsulinemia (insulinoma, antibody to insulin and insulin receptors). Postprandial hypoglycaemia is often seen after gastric surgery and non insulinoma pancreatogenous hypoglycaemia. Reproducible fasting hypoglycaemia is serious, needs evaluation and appropriate treatment whereas postprandial hypoglycaemia is a benign condition.

Insulinoma is a rare pancreatic endocrine tumour with an incidence of four cases per million per year [1]. Almost 90% insulinomas are benign, 10% are multiple and 4-7% is associated with multiple endocrine neoplasia type I. Fasting hypoglycaemia is commonly seen in insulinoma and patients have both neuroglycopenic and neurogenic symptoms. It is not uncommon to see patients of insulinoma being treated for epilepsy, psychiatric disorder or other neurological disease before actual diagnosis of insulinoma is made [2]. Insulinoma is characterized by inability to suppress endogenous insulin secretion during an episode of hypoglycaemia. Diagnostic criteria for insulinoma includes a plasma insulin level  $\geq 3$  microU/ml, plasma C-peptide level  $\geq 0.6$  ng/ml, plasma proinsulin  $\geq 5$  pmol/l and plasma beta hydroxybutyrate  $\leq 2.7$  mmol/l at the time of hypoglycaemic episode [3]. A 72 hour supervised fast is the gold standard method for diagnosis of insulinoma. Sulfonylurea and other secretagogue induced hypoglycaemia can have similar presentation and should be ruled out before making a diagnosis of insulinoma. Our patient satisfied all the criteria for diagnosis of insulinoma.

Most of the insulinomas are small and measures less than 2cm causing considerable difficulty in localizing these lesions by imaging techniques. Transabdominal ultrasound has a sensitivity of 50% and should be the first imaging modality. Double helical contrast enhanced Computed Tomography (CT) scan has a sensitivity of almost 80-90% and intravenous gadolinium enhanced Magnetic Resonance Imaging (MRI) has sensitivity between 75-85% in localizing insulinomas [4]. In patients of insulinoma with negative non-invasive tests, invasive test like Endoscopic Ultrasound (EUS) and Selective Arterial Calcium Stimulation Test (SACST) should be done to confirm the diagnosis. EUS has better detection rate and a high sensitivity rate of almost 92%. SACST has sensitivity of 93% and can even help in differentiating insulinoma from nesidioblastosis [5]. However, in spite of having various imaging modalities almost 25% insulinomas cannot be localized and are called occult, intraoperative ultrasonography and palpation by an experienced surgeon can achieve a sensitivity of almost 96-100% [6]. Surgical resection of tumour is the treatment of choice and success rate is approximately 90%. Patients who have contraindications for surgery can be managed medically by diazoxide, octreotide, verapamil and phenytoin.

Neurological involvement in hypoglycaemia is dependent upon the level of plasma glucose levels. Neurogenic symptoms occur at blood glucose level of 68 mg/dl, neuroglycopenic symptoms

occur when blood glucose level reaches 50 mg/dl, coma ensues when blood glucose levels falls below 50 mg/dl and ultimately brain death occurs at levels below 18 mg/dl [7]. Mechanism of neuronal death due to severe hypoglycaemia is much debated issue. Hypoglycaemia causes production of glutamate and aspartate which activates glutamate receptor causing influx of sodium, calcium and water within cells leading to cellular oedema and neuronal dysfunction. Also, NMDA receptor activation by glutamate causes production of reactive oxygen which damages neuronal DNA [8]. EEG becomes isoelectric and MRI shows lesions in bilateral basal ganglia, substantia nigra, hippocampus, cerebral cortex in hypoglycaemic coma. Death due to hypoglycaemic coma per se is very rare and is generally secondary to other associated comorbidities [9]. Malouf and Brust in their study on hypoglycaemic patients showed a mortality rate of 11% but only one patient succumbed to hypoglycaemia per se [10]. Daggett and Nabarro analysed neurological manifestation in insulinoma induced hypoglycaemia and found confusion to be the most common presentation followed by coma, seizures and weakness [11]. We could find only one death due to recurrent hypoglycaemia in an insulinoma patient [12]. In our case too, patient had hypoglycaemic coma but cause of death was possibly sepsis and septic shock.

## CONCLUSION

All non diabetic patients who satisfy Whipple's triad of hypoglycaemia should be evaluated for insulinoma. Surgical resection of insulinoma is the preferred treatment and should not be delayed after diagnosis. Although rare but severe hypoglycaemia in insulinoma can prove fatal.

## REFERENCES

- [1] Service FJ, McMahon MM, O'Brien PC, Ballard DJ. Functioning insulinoma--incidence, recurrence, and long-term survival of patients: a 60-year study. *Mayo Clin Proc.* 1991;66(7):711
- [2] Service FJ, Dale AJD, Elveback LR, Jiang NS. Insulinoma: clinical and diagnostic features of 60 consecutive cases. *Mayo Clin Proc.* 1976;51:417-29.
- [3] Service FJ. Diagnostic Approach to Adults with Hypoglycaemic Disorders. *Endocrinology and Metabolism Clinics of North America.* 1999;28:519-32.
- [4] Debray MP, Geoffroy O, Laissy JP, Lebtahi R, Silbermann-Hoffman O, Henry-Feugeas MC, et al. Imaging appearances of metastases from neuroendocrine tumours of the pancreas. *Br J Radiol.* 2001;74:1065-70.
- [5] Placzkowski KA, Vella A, Thompson GB, Grant CS, Reading CC, Charboneau JW. Secular trends in the presentation and management of functioning insulinoma at the Mayo Clinic, 1987-2007. *J Clin Endocrinol Metab.* 2009;94(4):1069.
- [6] Norton JA, Cromack DT, Shawker TH, Doppman JL, Comi R, Gordon P, et al. Intraoperative ultrasonographic localization of islet cell tumours. A prospective comparison to palpation. *Ann Surg.* 1988;207(2):160-68.
- [7] Cryer PE. Hypoglycaemia, functional brain failure, and brain death. *The Journal of Clinical Investigation.* 2007;117:868.
- [8] MacDermott AB, Mayer ML, Westbrook GL, Smith SJ, Barker JL. Nmda-receptor activation increases cytoplasmic calcium concentration in cultured spinal cord neurones. *Nature.* 1986;321:519.
- [9] Fischer KF, Lees JA, Newman JH. Hypoglycaemia in hospitalized patients: causes and outcome. *N Eng J Med.* 1986;315:1245-50.
- [10] Malouf R, Brust JCM. Hypoglycaemia: causes, neurological manifestations and outcome. *Ann Neurol.* 1985;17:421-30.
- [11] Daggett P, Nabarro J. Neurological aspects of insulinomas. *Postgraduate Medical Journal.* 1984;60:577-81.
- [12] Wallis WE, Donaldson I, Scott RS, Wilson J. Hypoglycaemia masquerading as cerebrovascular disease (hypoglycaemic hemiplegia). *Ann Neurol.* 1985;18:510-12.

### PARTICULARS OF CONTRIBUTORS:

1. Senior Resident, Department of Medicine, PGIMER and Dr RML Hospital, New Delhi, India.
2. Associate Professor, Department of Medicine, PGIMER and Dr RML Hospital, New Delhi, India.
3. Postgraduate Resident, Department of Medicine, PGIMER and Dr RML Hospital, New Delhi, India.
4. Postgraduate Resident, Department of Medicine, PGIMER and Dr RML Hospital, New Delhi, India.
5. Associate Professor, Department of Medicine, PGIMER and Dr RML Hospital, New Delhi, India.

### NAME, ADDRESS, E-MAIL ID OF THE CORRESPONDING AUTHOR:

Dr. Prabhat Kumar,  
C/O Dr. Ajay Chauhan, Associate Professor, Room No. 105, Academic Block,  
PGIMER and Dr RML Hospital, New Delhi-110001, India.  
E-mail: drkumar.prabhat@gmail.com

FINANCIAL OR OTHER COMPETING INTERESTS: None.

Date of Submission: Feb 10, 2016

Date of Peer Review: Feb 29, 2016

Date of Acceptance: Mar 03, 2016

Date of Publishing: Aug 01, 2016