

# Primary Inadequate Management of Dental Trauma

ANASTASIA AGRAFIOTI<sup>1</sup>, IOANNIS N. TSATSOULIS<sup>2</sup>, STYLIANI I. PAPANAKOU-TZANETAKI<sup>3</sup>, EVANGELOS G. KONTAKIOTIS<sup>4</sup>

## ABSTRACT

Tooth fractures are common complications due to trauma in the oral cavity. Tooth fragments and foreign bodies may be embedded in soft tissues as a result of dentofacial trauma and go unnoticed in emergency situations. The inadequate management of such cases may lead to complications, such as foreign-body reaction and scarring. This report describes two cases with dental fragments embedded in the lower lip, which went unnoticed until the patients presented later for completely different treatments and emphasizes the importance of clinical and radiographic examination of soft tissues, even in cases that present late for dental trauma management.

## CASE REPORT

### Case 1

A 30-year-old female patient presented to the Postgraduate Dental Clinics at University of Athens, for restoration of the maxillary central incisors [Table/Fig-1]. The medical history was non-contributory. The patient reported that she sustained orofacial trauma with bleeding from a laceration in the lower lip, two weeks ago, due to a fall on the floor. She sought treatment at the emergency department of a hospital, where the soft tissue wound was sutured and she was advised to have the teeth restored after complete healing of the tissues.

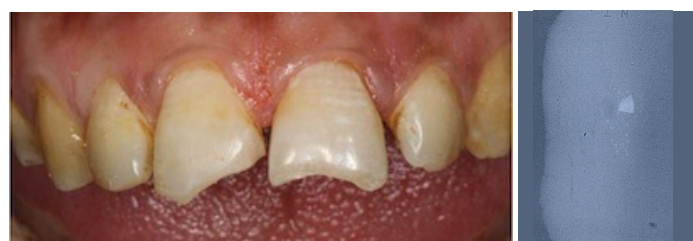A thorough intraoral examination revealed a hard mass of the lower lip during palpation. A radiograph of the soft tissues revealed a radiopaque foreign body in the lower lip tissues which could be the coronal fragment of the fractured incisors [Table/Fig-2].

The maxillary central incisors were not sensitive to air and the electrical sensitivity test revealed that they were vital. Periapical radiographs of the upper anterior teeth revealed no sign of root fracture or pathological periapical lesion. The teeth were restored with composite resin.

Afterwards, a horizontal incision was made in the lower lip under local anaesthesia, and the tooth fragment was removed surgically [Table/Fig-3]. Immediately after the surgical procedure, another soft tissue radiograph was obtained to confirm that the lower lip was free of any remaining fragments and the incision was sutured with 4-0 silk suture material. The patient was examined two weeks post-operatively and the healing of the wound was uneventful.

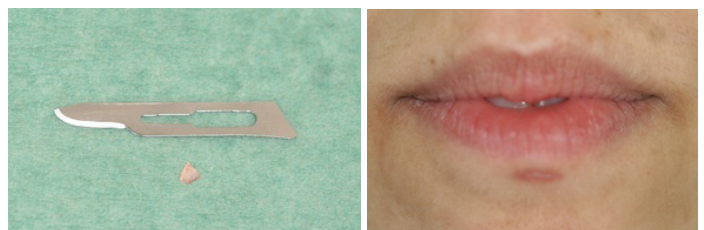
### Case 2

A 26-year-old female patient presented at the emergency room of the Department of Endodontics, School of Dentistry, University

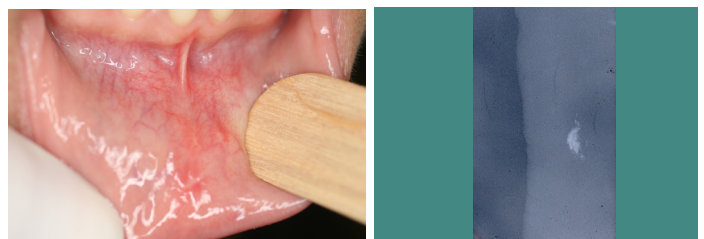

[Table/Fig-1]: Intraoral view of the fractured teeth. [Table/Fig-2]: Preoperative soft-tissue radiograph revealing tooth fragment in the lower lip.

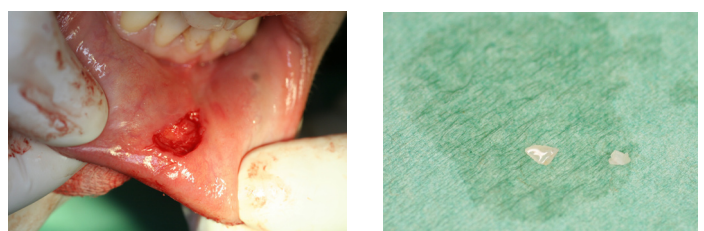
**Keywords:** Fragments, Laceration, Scar formation



[Table/Fig-3]: Tooth fragment removed from the lower lip. [Table/Fig-4]: Extraoral view of the injury showing scar.



[Table/Fig-5]: Intraoral examination of the lip showing foreign body. [Table/Fig-6]: Preoperative radiograph showing dental fragments in the lower lip.



[Table/Fig-7]: Intraoral view of the lip after the removal of the fragment. [Table/Fig-8]: Tooth fragment removed from the lip.

of Athens, complaining of pain in the area of the maxillary left central incisor. The patient reported that she had fallen while riding a bike about four months earlier and had fractured her upper central incisors with lip lacerations. She immediately visited a local dentist, who restored the teeth with composite resin. The patient did not complain of any pain or discomfort ever since, until two days back.

During the extraoral examination, a scar on the skin in the labiomental sulcus area was noticed [Table/Fig-4]. Upon palpation of the lip, the presence of a hard mass was noticed [Table/Fig-5]. Because of the facial trauma reported by the patient, a soft-tissue radiograph was obtained and some radiopaque fragments were noted in the lower lip tissues [Table/Fig-6].

The upper left central incisor did not respond to pulp sensitivity tests and was highly sensitive to percussion. Therefore, an endodontic treatment was initiated.

The patient underwent to surgical excision of the fragments under local anaesthesia [Table/Fig-7,8] and the incision was sutured with 4-0 silk suture material. The sutures were removed on the seventh post-operative day and the healing period was uneventful.

## DISCUSSION

Dental trauma is often associated with soft tissue injuries. Laceration of the lip has been reported to be the most predominant injury to structures of the oral cavity, accounting for 62.8% of the dental injuries [1]. The teeth that are most commonly affected by trauma are the maxillary central incisors, probably because of the anterior teeth projection and the inadequate protection of the labial lip [2-4].

In managing dental trauma, the clinician should always perform intraoral examination or soft tissue inspection; otherwise tooth fragments may be overlooked in soft tissues and lead to scar formation. The incorporation of foreign bodies and tooth fragments in dentofacial trauma increases the risk of infection, damaged vascular and nervous sheaths and formation of fibrous scar tissue [4].

The present case reports indicate that in emergency situations, the nature and complexity of the injuries, as well as unawareness of the staff may lead to overlooking the dental injuries. The staff of an emergency department of a hospital and a general dentist failed to notice the presence of tooth fragments in the lower lip in these cases.

In cases of dental trauma where facial injuries are also present, the clinician should examine carefully both hard and adjacent soft

tissues, even if the patient was previously treated by another health professional [5,6]. Radiographic evaluation of facial soft tissues is fundamental before starting treatment in such cases [5,7,8]. Tooth fragments and foreign bodies may be found in the oral mucosa due to accidental implantation and the surgical excision of the fragments consists the treatment of choice in these cases [5,6].

## CONCLUSION

The extreme importance of precise case history evaluation and clinical and radiographic assessment in-detail is emphasized in these case reports, even in cases that present late after dental trauma management and maybe seeking a completely different treatment. It also highlights the importance of training emergency department staff and dentists on proper examination in cases of dentofacial trauma.

## REFERENCES

- [1] O'Neil DW, Clark MV, Lowe JW, Harrington MS. Oral trauma in children: a hospital survey. *Oral Surg Oral Med Oral Pathol.* 1989;68:691-96.
- [2] Caldas AF Jr, Burgos ME. A retrospective study of traumatic dental injuries in a Brazilian dental trauma clinic. *Dent Traumatol.* 2001;17:250-53.
- [3] Schatz JP, Joho JP. A retrospective study of dento-alveolar injuries. *Endod Dent Traumatol.* 1994;10:11-14.
- [4] Andersson L, Andreasen JO. Soft tissue injuries. In: Andreasen J, Andreasen J, Andersson L, editors. Textbook and color atlas of traumatic injuries to the teeth and the mouth. Munksgaard: Blackwell 2007, 577-97.
- [5] da Silva AC, de Moraes M, Bastos EG, Moreira RW, Passeri LA. Tooth fragment embedded in the lower lip after dental trauma: case reports. *Dent Traumatol.* 2005;21:115-20.
- [6] Altundasar E, Demiralp B. The importance of soft tissue examination in post-traumatic decision-making: A case report. *Aust Endod J.* 2013;39:35-38.
- [7] Munerato MC, da Cunha FS, Tolotti A, Paiva RL. Tooth fragments lodged in the lower lip after traumatic dental injury: a case report. *Dent Traumatol.* 2008;24:487-89.
- [8] Snawder KD, Bastawi AE, O'Toole TJ. Tooth fragments lodged in unexpected areas. *JAMA.* 1976;236:1378-79.

### PARTICULARS OF CONTRIBUTORS:

1. Lecturer, Department of Endodontics, School of Dentistry, National and Kapodistrian University of Athens, Athens, Greece.
2. Consultant, Department of Endodontics, School of Dentistry, National and Kapodistrian University of Athens, Athens, Greece.
3. Postgraduate Student, Department of Paediatric Dentistry, School of Dentistry, National and Kapodistrian University of Athens, Athens, Greece.
4. Associate Professor, Department of Endodontics, School of Dentistry, National and Kapodistrian University of Athens, Athens, Greece.

### NAME, ADDRESS, E-MAIL ID OF THE CORRESPONDING AUTHOR:

Dr. Evangelos G. Kontakiotis,  
Associate Professor, Department of Endodontics, School of Dentistry, National and Kapodistrian University of Athens,  
Thivon 2, Goudi, GR-11527, Athens, Greece.  
E-mail: e-kontak@dent.uoa.gr

FINANCIAL OR OTHER COMPETING INTERESTS: None.

Date of Submission: **Mar 11, 2016**  
Date of Peer Review: **May 26, 2016**  
Date of Acceptance: **Jun 13, 2016**  
Date of Publishing: **Jul 01, 2016**