

# Clinical Evaluation of Proclination of Lower Anterior Teeth during Alignment using a Single Width Bracket-A Pilot Study

NAVEEN KUMAR KRISHNA<sup>1</sup>, AZEEM FARHAN<sup>2</sup>, RASHMI ISSAR<sup>3</sup>, SHASHIKALA SUBRAMANIAN<sup>4</sup>,  
MANJU PRASAD MUNIYAPPA<sup>5</sup>, SHASHI RANJAN<sup>6</sup>, PRIYANKAR SINGH<sup>7</sup>, KUMAR TATHAGAT SINGH<sup>8</sup>

## ABSTRACT

**Introduction:** The pre-adjusted brackets are available in various prescriptions and sizes; nevertheless there are still many controversies as to which pre-adjusted edgewise bracket offers the maximum clinical efficiency.

**Aim:** This study was conducted to determine and compare the amount of lower incisor proclination during de-crowding if any of the Mini-Uni Twin Brackets with that of the standard double width brackets.

**Materials and Methods:** A total of 20 patients i.e., 10 patients in each group both males and females were randomly selected for the study from subjects seeking treatment, the selected samples were grouped as follows. Group I – Double Width Brackets (3M Unitek Gemini Series) 0.018" slot with Roth prescription. Group

II – Mini Uni-Twin Bracket (3M Unitek) 0.018" slot with Roth prescription.

**Results:** The Mini-Uni Twin Brackets had statistically significant ( $p = 0.01$ ) amount of proclination of the lower anteriors ( $0.8^{\circ} \pm 0.3^{\circ}$ ) after de-crowding as compared to the standard Double Width Brackets and since the mean change in the Incisor Mandibular Plane Angle (IMPA) was lesser than  $1^{\circ}$ , its clinical significance could be questionable.

**Conclusion:** The Mini Uni Twin brackets are comparatively efficient in the lower anterior decrowding but further comparative clinical studies need to be performed on these Mini Uni Twin brackets, with an increase in the sample size and also the number of parameters to prove its total clinical efficiency.

**Keywords:** Incisor crowding, Incisor proclination, Interbracket span, Mini-Uni Twin brackets

## INTRODUCTION

Newer wires and innovations in the bracket systems have simplified and reduced the time span of the aligning stage. The results of the study by Schudy and Schudy showed that, to receive the greatest range or flexibility and the lightest force from a wire three conditions must be present: Large interbracket distance, small wires, and as much interbracket space [bracket wire interplay] as possible [1].

Many appliance systems are designed primarily to deal with later stages of tooth movement involving space closure and root torque. While in some cases initial alignment may be only a minor problem, with major irregularities of the teeth, the arch wire bracket system is worthy of serious consideration [2]. It has been claimed that the Mini-Uni Twin Brackets give a more rapid and a better-controlled alignment with minimal patient discomfort as the inter-bracket distance is considerably increased due to the reduced slot width [3,4].

## AIM

The present study was conducted to determine and compare the amount of lower anterior teeth proclination during de-crowding if any by the Mini-Uni Twin Brackets with that of the standard Double Width Brackets.

## MATERIALS AND METHODS

A total of 20 patients i.e., 10 patients in each group both males and females were randomly selected for the study from subjects seeking treatment at the Department of Orthodontics, Meenakshi Ammal Dental College and Hospital, Chennai, India for the present pilot study. Since it was a comparative pilot study only convenience sampling was done, patients with either Angle's Class I or Class II dento-alveolar malocclusions and between the age group of 14 – 20 years were selected.

All cases had lower incisor crowding discrepancy ranging from 4mm to 9mm (According to Little's Index) [5] with no or mild proclination. Only cases with crowding distributed evenly in the lower anterior segment were selected. All cases were planned to undergo first premolar extractions and had the first molar as an anchor unit. Cases selected were without any unfavorable inclinations of canines. Cases devoid of any pernicious oral habits, with good oral hygiene and without any malformation of the anterior teeth were included in this study. Cases with broken bands and/or attachments during the course of this study were excluded from the study.

### The selected samples were grouped as follows:

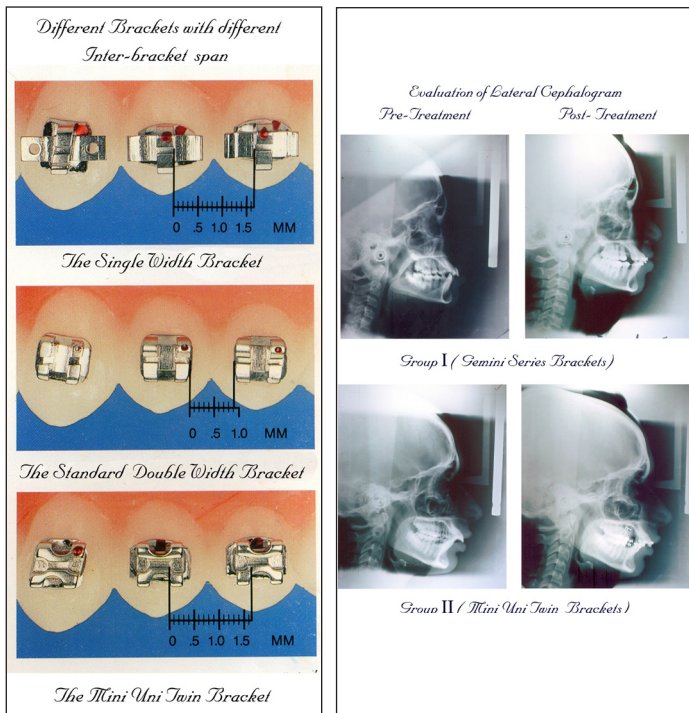
Group I – Double Width Brackets (3M Unitek Gemini Series) 0.018" slot with Roth prescription. The width of the lower central incisor bracket was 2.4mm i.e., the width of the actual slot dimension.

Group II – Mini Uni-Twin Brackets (3M Unitek) 0.018" slot with Roth prescription. The width of a lower central incisor Mini-Uni Twin bracket was 2.5mm but the precision or the working part was no greater than 1.1mm as shown in [Table/Fig-1].

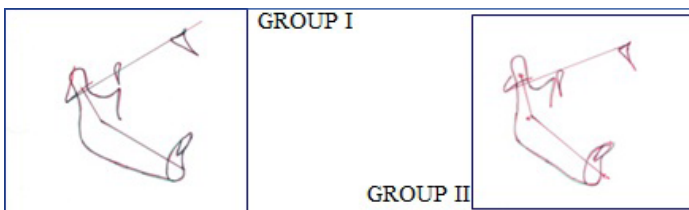
**Clinical procedure:** The clinical procedure given below was followed for standardization.

Pretreatment records for the study consisted of the following study models, photographs (intra-oral occlusal view) and lateral cephalogram; all cases were started within two days from the last extraction. Impressions and photographs of the lower arch were made after completion of the bonding procedure. Lace backs were placed in all cases using stainless steel ligature wires of 0.009" passively by the same operator and were changed during every visit of the patient [6,7].

Heat activated 0.016" NiTi ( $37^{\circ}$ ) was used. The wire was chilled before insertion and individual ligature ties were placed on each



[Table/Fig-1]: Different bracket with different interbracket span. [Table/Fig-2]: Pre & Post lateral cephalogram.



[Table/Fig-3]: Comparison of proclination of the lower anteriors between group I & group II superimposition of pre and post de-crowding. (Pre-treatment & Post-treatment).

tooth sufficiently tight to engage the wire fully into the bracket slots.

All patients were asked to report once in 30 days and were instructed to report immediately if there were any loose brackets or bands.

**Evaluation of the incisor proclination during de-crowding:**

Lateral cephalograms in centric occlusion and natural head position with lips in relaxed position were obtained before the commencement of treatment and after completion of the de-crowding.

The pre-treatment and post-treatment lateral cephalograms were traced in the usual manner [Table/Fig-2].

**The Incisor Mandibular Plane Angle (IMPA) [8]**

The angle formed by the long axis of the mandibular incisor and the mandibular plane was measured. The difference between the pre-treatment and post-treatment lateral cephalogram was calculated for the change in the axial inclination of the lower incisor during de-crowding as shown in [Table/Fig-3].

All the observations were re-evaluated thrice and the mean of the same were considered to avoid any measurement errors.

The tabulated data was analyzed statistically. Pearson's Chi Square Test was used to calculate the Probability (p) value. A p<0.05 was considered as the level of significance.

**RESULTS**

The observations of the lateral cephalogram analysis are tabulated as in [Table/Fig-4].

The mean value of the incisor inclination on the 1<sup>st</sup> day of the study and the mean value of incisor inclination after decrowding of

incisors, i.e., the pre and post treatment incisor mandibular plane angle between Group I and Group II were tabulated and compared using the Pearson's Chi Square test as shown in [Table/Fig-5].

Inference of the statistical analysis: The mean change in the IMPA in Group II (1.8°±0.9°) was statistically significantly higher than the Group I (0.8°±0.6°) (p = 0.01), i.e., Group II cases showed a higher degree of proclination (0.8°±0.3°) during de-crowding as compared to Group I cases as shown in [Table/Fig-6].

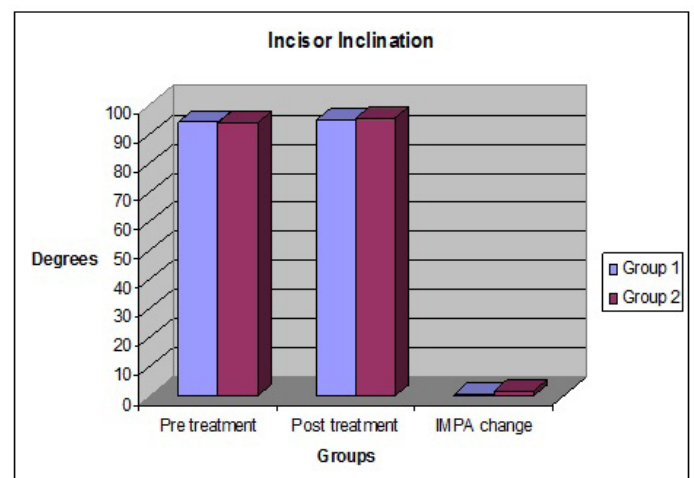
Group	Patient number	Pre-treatment IMPA	Post-treatment IMPA
I	1	96	97
I	2	94	96
I	3	92	93
I	4	93	93
I	5	91	92
I	6	95	95
I	7	97	98
I	8	95	96
I	9	93	94
I	10	97	97
II	1	92	94
II	2	94	97
II	3	92	95
II	4	96	96
II	5	93	95
II	6	96	97
II	7	97	99
II	8	95	97
II	9	94	96
II	10	91	92

[Table/Fig-4]: Comparison of pretreatment and post de-crowding incisor mandibular plane angle.

Variable	Group I	Group II	p-value *
	Mean ±S.D	Mean ± S.D	
IMPA- Pre	94.3° ± 2.1°	94.0° ± 2.0°	0.75
IMPA- Post	95.1° ± 2.0°	95.8° ± 1.9°	0.44
IMPA- Change	0.8° ± 0.6°	1.8° ± 0.9°	0.01

[Table/Fig-5]: Comparison of amount of incisor proclination after de-crowding between Group I and Group II.

\*Pearson's Chi Square Test was used to calculate the Probability (p) value.



[Table/Fig-6]: Comparison of incisor proclination after de-crowding between group I & group II.

**DISCUSSION**

Crowding of anterior teeth remains one of the most prevalent conditions, which brings the patient to the orthodontist seeking remedy because of its esthetic and functional consequences.

In nearly every patient with malaligned teeth the root apices are closer to the normal position than the crowns. To bring teeth into alignment, a combination of labiolingual and mesiodistal tipping guided by an arch wire was needed. The root movements are avoided at this stage as it causes inadvertent root resorption. Hence, wires that provide light, continuous force for the effective tooth movement were used [9].

The most important factors in determining the design of an appliance are the size and shape of the teeth, especially the mesio-distal width. These affect the inter-bracket width and which in turn affects the ability to align and level the teeth [10].

The Mini Uni-Twin bracket was neither a prescription nor a technique rather an amalgamation between the single width and the double width bracket. The Mini-Uni Twin brackets had the skeleton framework of a twin Bracket, whereas the centre of the bracket slot was not wider than that of a single width bracket. The slot then widened considerably as it moved towards the edges of the twin bracket tie wings, and this feature allowed the archwire to flex considerably, yet stay within the confines of the twin bracket [3,11].

The mandibular crowding was quantified using the Little's Irregularity Index. The Little's Index was chosen as it was the index which considered the discrepancy in the lower incisor segment (mesial surface of the canine on one side to the mesial surface of the canine on the other side) unlike the Carey's analysis which considers the discrepancy but also considers the posterior segment (mesial surface of the molar on one side to the mesial surface of the molar on the other side) and any crowding in the premolar region would alter the values of the incisor de-crowding [12].

Lateral cephalogram in centric occlusion and natural head position with lips in relaxed position were obtained to avoid any errors in standardization.

The IMPA was measured. The difference between the pre-treatment and post-treatment lateral cephalogram was calculated for the change in the axial inclination of the lower incisor during de-crowding.

[Table/Fig-6] demonstrates the mean ratios of IMPA before treatment and the IMPA after de-crowding it also demonstrates the difference in the IMPA changes after de-crowding between the two groups. Both Group I and Group II cases demonstrated an increase in the proclination of the lower anteriors during de-crowding and this was in correlation with Hocevar [13]. Though

the mean change in IMPA was comparatively greater ( $0.8\pm 0.3^\circ$ ) in Group II indicating a greater degree of proclination of the lower anteriors during de-crowding, clinically it was of lesser significance.

Further comparative clinical studies need to be performed on these Mini-Uni Twin Brackets, with an increase in the sample size of the same age and sex and also the number of parameters to prove its total clinical efficiency.

## CONCLUSION

This study was conducted to determine and compare the amount of lower incisor proclination during decrowding of the lower anteriors between the Mini Uni Twin brackets and that of the standard double width bracket. The Mini-Uni Twin brackets had statistically significant amount of proclination of the lower anteriors ( $0.8\pm 0.3^\circ$ ) after de-crowding as compared to the standard Double Width Brackets and since the mean change in the IMPA was lesser than  $1^\circ$  its clinical significance could be questionable.

To conclude, we tend to accept those mechanisms and systems in which the advantages outweigh the disadvantages. Since, we will never find a completely ideal appliance we must rely on the one that has the maximum advantages and the one that is in best harmony with the biologic requirements.

## REFERENCES

- [1] Schudy G. Schudy F.: Intra-bracket space and inter-bracket distance: critical factors in clinical orthodontics. *AJODO*. 1989;96(4):281-94.
- [2] Schudy G. Bracket design and wire flexibility. *JCO*. 1990;45: 106-14.
- [3] Creekmore TD. The importance of inter-bracket width in orthodontic tooth movement. *JCO*. 1976; 37: 530-34.
- [4] Creekmore TD. Comment reference in intra-bracket space and intra-bracket distance article. *AJODO*. 1990; 97 (4):33.
- [5] Little R.M. The irregularity index: a quantitative score mandibular anterior alignment. *American Journal of Orthodontics and Oral Surgery*. 1975; 68 (5): 554-63.
- [6] Bennett and McLaughlin: Orthodontic treatment mechanics and the preadjusted appliance. Mosby-Wolfe publication: 2002; 125.
- [7] Irvine R, Power S, McDonald F. The effectiveness of lace back ligatures: a randomized controlled clinical trial. *J Orthod*. 2004; 31(4): 303-11.
- [8] Tweed C.H. The Frankfurt mandibular plane angle in orthodontic diagnosis, classification, treatment planning and prognosis. *AJO*. 1946;32 (4):175-230.
- [9] Kusy R and Dilley G. Elastic property ratios of a triple stranded stainless steel archwire. *American Journal of Orthodontics and Oral Surgery*. 1984; 86(3): 177-88.
- [10] Alexander R. Treatment Guidelines. *AJODO*. 2007; 131(6):698.
- [11] Tidy: Frictional forces in fixed appliances. *AJODO*. 1989; 96(3):249-54.
- [12] Carey C. Linear arch dimension and toothsize. *American Journal of Orthodontics and Oral Surgery*. 1949; 35 (10):762-75.
- [13] Hocevar R. Orthodontic force systems: technical refinements for increased efficiency. *American Journal of Orthodontics and Oral Surgery*. 1982; 81 (1):1-11.

### PARTICULARS OF CONTRIBUTORS:

1. Professor, Department of Orthodontics, KGF College of Dental Sciences, Kolar, Karnataka, India.
2. Ex. Professor, Department of Orthodontics, Private Practice, India.
3. Reader, Department of Conservative Dentistry & Endodontics, Patna Dental College, Patna, Bihar, India.
4. Professor and Head, Department of Orthodontics, KGF College of Dental Sciences, Kolar, Karnataka, India.
5. Senior Lecturer, Department of Orthodontics, Vydehi Institute of Dental Sciences, Bangalore, Karnataka, India.
6. Reader, Department of Oral & Maxillofacial Pathology, Private Practice, Buddha Dental College, Patna, Bihar, India.
7. Senior Resident, Department of Oral & Maxillofacial Surgery, Indira Gandhi Institute Of Medical Sciences, Patna, Bihar, India.
8. Reader, Department of Oral & Maxillofacial Surgery, B.R.Ambedkar Institute of Dental Sciences & Hospital, Patna, Bihar, India.

### NAME, ADDRESS, E-MAIL ID OF THE CORRESPONDING AUTHOR:

Dr. Naveen Kumar Krishna,  
# 33, Nachi nilaya, Subbainapalya, Banasawadi Main Road, Bangalore-560033, Karnataka, India.  
E-mail: ananya\_dent@yahoo.com

Date of Submission: **Feb 24, 2016**

Date of Peer Review: **Mar 08, 2016**

Date of Acceptance: **May 19, 2016**

Date of Publishing: **Jun 01, 2016**

FINANCIAL OR OTHER COMPETING INTERESTS: None.