

Acute Bilateral Tuberculous Pneumonia in a Patient with Systemic Lupus Erythematosus

RAGHAVENDRA RAO¹, RAMA BHAT², NITIN BHAT³, SAVIO D'SOUZA⁴, VENKATA CHENCHIAH⁵

ABSTRACT

Pulmonary tuberculosis is a common infection associated with immunocompromised state. It usually presents with fibrosis or fibrocavitary lesions in the lung. We report a case of bilateral tuberculous pneumonia of acute presentation in a young lady who was being treated for systemic lupus erythematosus.

Keywords: Acute respiratory failure, Immunocompromised, Pulmonary manifestation

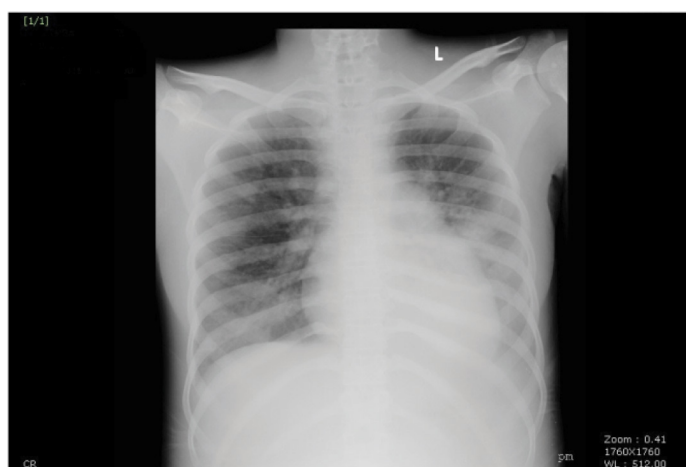CASE REPORT

A 17-year-old female who is a known case of systemic lupus erythematosus (diagnosed 1 year ago), had presented to us with history of fever and cough of 1 week duration. Sputum was whitish in colour, non-foul smelling with no haemoptysis. There was no history of chest pain or breathlessness. She was on oral prednisolone 10mg/day. She was treated with cyclophosphamide a month ago for lupus induced psychosis. On general examination there was pallor. Her pulse rate was 96/min, BP – 120/80 mmHg, respiratory rate of 22/min and temperature-100°F. There were no signs of active lupus like rash, arthralgia or oral ulcers. On systemic examination there were fine end-inspiratory crepitations in the left infra-scapular area and infra-axillary area.

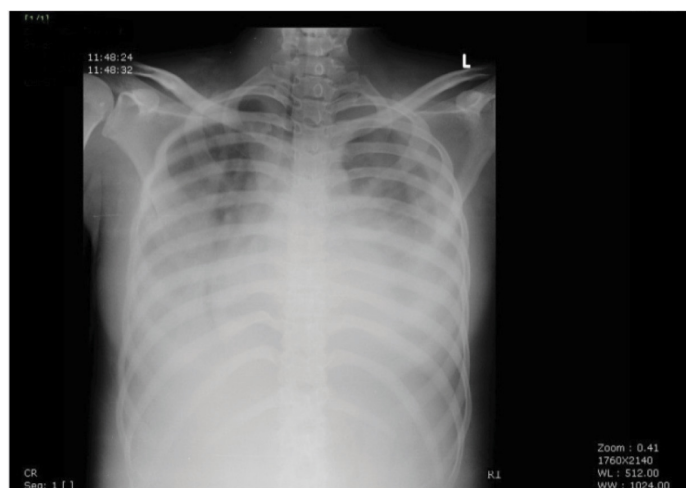
On evaluation her haemoglobin was 7.8g/dl and peripheral smear picture was suggestive of iron deficiency anaemia. Other lab reports, total leukocyte count- $4.5 \times 10^3/\mu\text{L}$, platelet count- $2.77 \text{ lac}/\mu\text{L}$, ESR- 114 mm/hr, Blood Urea-18 mg/dl, Serum Creatinine-0.5 mg/dl, AST- 25 U/L, ALT-32 U/L, CRP – 133.1mg/L, Complement level-normal, blood culture and sputum culture showed no growth of any microorganism, sputum AFB (3 samples) negative. Chest X-ray showed non-homogenous opacity in left mid and lower lung fields suggesting pneumonia [Table/Fig-1]. HIV ELISA was negative.

She was started on empirical antibiotics (piperacillin+tazobactam and azithromycin) since she had no features of lupus pneumonitis. She did not improve with antibiotics and had worsening of symptoms after 5 days of starting antibiotics. She had developed breathlessness and was tachypneic. Arterial blood gas analysis was done which was suggestive of hypoxia. Oxygen of 8L/min was started and chest x-ray was repeated, which showed bilateral pneumonia with right sided pleural effusion [Table/Fig-2]. Antibiotic was changed to meropenem with linezolid due to worsening of pneumonia. CT-thorax was not done due to financial constraints. Pleural fluid was aspirated under ultrasound guidance and sent for analysis. It showed total count- $140 \text{ cells}/\text{mm}^3$ with lymphocytes 91% and neutrophils 9%, protein-3.6g/dl, glucose-74 mg/dl (RBS-95mg/dl), LDH -413U/L (Serum LDH-514U/L), ADA -64U/L, fungal culture – no growth, pleural fluid culture –no growth, AFB – negative. PCR for *M.tuberculosis* was positive from the pleural fluid. Sputum AFB (3 samples) were sent again due to strong suspicion of tuberculosis and was found to be positive (1+).

She was started on 4 drug regimen of anti-tubercular therapy. She improved clinically with treatment and chest x-ray [Table/Fig-3] was repeated after 4 weeks of anti-tubercular therapy which was found to be normal. She was then discharged and was asked to come for follow-up.



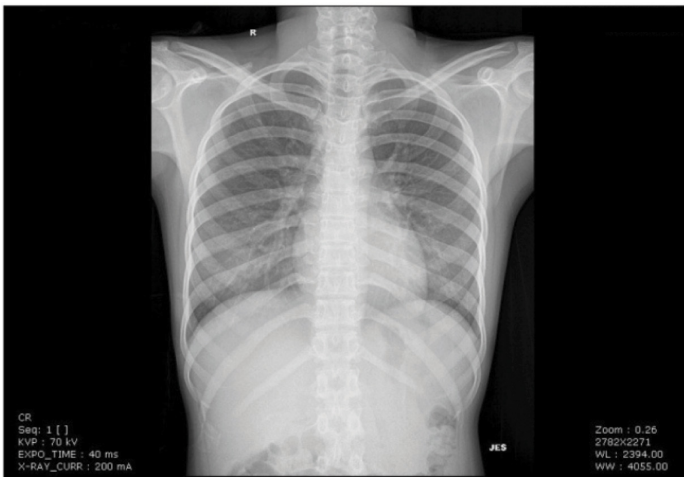
[Table/Fig-1]: CXR-PA view showing pneumonia involving the left mid and lower lung fields.



[Table/Fig-2]: CXR-PA view showing bilateral extensive pneumonia with right sided pleural effusion.

DISCUSSION

The rapid progression in patients with acute tuberculous pneumonia can mimic bacterial pneumonia. The non-classical forms of pulmonary tuberculosis, including pneumonia, are often seen in HIV-infected and immunosuppressed individuals. In a recent case series of 231 patients with pulmonary tuberculosis, 113 were HIV-infected [1]. Calix et al., characterized acute tuberculous pneumonia as consisting of symptoms of less than one month duration, fever, productive cough and physical examination demonstrating consolidation [2]. A criteria was laid



[Table/Fig-3]: CXR-PA view showing clearing of pneumonia after starting anti-tubercular therapy.

by Schwartz and Moyer in making the diagnosis of tuberculous pneumonia which is as follows [3]: 1) Presence of large confluent dense shadows on the chest x-ray involving at least one lobe; 2) High spiking fever with signs of severe toxicity; 3) Chest examination showing signs of consolidation; and 4) Sputum examination showing tubercle bacilli. Tuberculosis presenting as an acute, rapidly progressive lobar pneumonia is unusual since the tubercle bacilli multiply only once every 18 to 24 hours. It could happen if there is a massive number of tubercle bacilli in the lung or if the tuberculo-protein is aspirated, causing an acute exudative hypersensitivity reaction [4]. According to a study done by Kala et al., it was found that middle lobe is the most common site of involvement in tuberculous pneumonia [5]. Advanced age, long duration of symptoms prior to hospital admission, presence of shock and non-use of steroids influence the survival rate in patients with tuberculous pneumonia [6]. Our patient was young, duration of symptoms was 1 week and was normotensive. However, she was on steroids and had received a dose of cyclophosphamide which could have been the cause for acute massive tuberculous pneumonia in this patient. Systemic lupus erythematosus itself can present with various lung manifestations like pleuritis, pleural effusion, parenchymal lung disease, lupus pneumonitis, shrinking lung syndrome, diffuse alveolar haemorrhage, Adult Respiratory Distress Syndrome (ARDS), pulmonary hypertension, pulmonary thromboembolism and pulmonary infections. Lupus pneumonitis was ruled out since, there were no active signs of lupus and complement levels were normal. CRP levels were very high suggesting infection. Pulmonary infection in SLE has been reported in a study from Chennai as high as 20 percent [7]. All the cultures were negative in our patient including fungal culture from the pleural fluid, ruling out fungal infection and most of the bacterial infections. PCR for *M. tuberculosis* from pleural fluid being positive, lead us to a strong positive step towards the diagnosis. Repeat sputum AFB sample sent was positive which confirmed our diagnosis of tuberculous pneumonia. Many defects in host defense have been described in SLE, including defects in alveolar macrophage function, chemotactic and phagocytic activity of

neutrophils, T cell number and function, delayed hypersensitivity reactions, dendritic cell, B cell and natural killer (NK) cell function [8]. This could lead to higher incidence of infections in these patients. The occurrence of tuberculosis also correlates with steroid dosing. Several studies have demonstrated a higher cumulative dose and/or a higher mean daily dose of prednisone in SLE patients before development of tuberculosis [9,10]. There was a 23% increment in the chance of developing TB for every gram of prednisolone that was taken [9]. The effects of cortisol on the immune response to MTB antigens were studied in vitro which convincingly proved the role of steroids in increasing the risk of TB [11]. The study showed that cortisol, in its physiological concentrations inhibited mycobacterial antigen driven proliferation of cells and also the production of interferon gamma from healthy controls and TB patients. American Thoracic Society has suggested screening for latent TB prior to high dose prednisolone and other lupus drugs [12]. A study done by Hernández-Cruz B et al., showed that in endemic areas, prophylaxis with isoniazid reduced the risk of developing TB in patients taking > 15 mg/day of prednisolone [13].

CONCLUSION

Tuberculous pneumonia even of acute onset should be considered in all patients who are on high dose corticosteroids or immunosuppressive agents especially if the patients are not responding to conventional antibiotics or if the bacterial cultures are negative.

REFERENCES

- Picon PD, Caramori ML, Bassanesi SL, Jungblut S, Folgerini M, Porto Nda S, et al. Differences in the clinical and radiological presentation of intrathoracic-tuberculosis in the presence or absence of HIV infection. *J Bras Pneumol.* 2007;33(4):429-36.
- Calix AA, Ziskind MM, Leonard AJ, et al. Acute tuberculous pneumonia in the Negro. *Am Rev Tuberc.* 1953;68:382-92.
- Schwartz WS, Moyer EE. The management of massive tuberculous pneumonia. *Am Rev Tuberc.* 1951;64:41-49.
- Rich AR. The pathogenesis of Tuberculosis. Springfield, Charles C Thomas, 1944; pp. 828-30.
- Kala J, Sahay S, Shah A. Bronchial anthracofibrosis and tuberculosis presenting as a middle lobe syndrome. *Prim Care Respir J.* 2008;17(1):51-55.
- Kim YJ, Pack KM, et al. Pulmonary tuberculosis with acute respiratory failure. *Eur Respir J.* 2008;32:1625-30.
- Ramnathan P, Rathnasamy R. Infections in a rheumatology setting- Chennai experience. *Indian J Rheumatol.* 2011;6:31-35.
- Orens JB, Martinez FJ, Lynch JP. Pleuro-pulmonary manifestations of systemic lupus erythematosus. *Rheum Dis Clin North Am.* 1994;20:159-93.
- Tam LS, Li EK, Wong SM, Szeto CC. Risk factors and clinical features for tuberculosis among patients with systemic lupus erythematosus in Hong Kong. *Scand J Rheumatol.* 2002;31:296-300.
- Erdozain JG, Ruiz-Irastorza G, Egurbide MV, Martinez-BerriotxoA, Aguirre C. High risk of tuberculosis in systemic lupus erythematosus. *Lupus.* 2006;15:232-35.
- Mahuad C, Bay ML, Farroni MA, Bozza V, Del Rey A, Besedovsky H, et al. Cortisol and dehydroepiandrosterone affect the response of peripheral blood mononuclear cells to mycobacterial antigens during tuberculosis. *Scand J Immunol.* 2004;60:63946.
- American Thoracic Society/Centers for Disease Control and Prevention/Infectious Diseases Society of America: controlling tuberculosis in the United States. *Am J Respir Crit Care Med.* Vol. 172, No.9 (November 1st), pp.1169-1227.
- Hernández-Cruz B, Ponce-de-León-Rosales S, Sifuentes-Osorio J, Ponce-de-León-Garduño A, Díaz-Jouanen E. Tuberculosis prophylaxis in patients with steroid treatment and systemic rheumatic diseases. A case-control study. *Clin Exp Rheumatol.* 1999;17(1):81-87.

PARTICULARS OF CONTRIBUTORS:

- Assistant Professor, Department of Medicine, Kasturba Medical College, Manipal University, Manipal, Karnataka, India.
- Professor, Department of Medicine, Kasturba Medical College, Manipal University, Manipal, Karnataka, India.
- Assistant Professor, Department of Medicine, Kasturba Medical College, Manipal University, Manipal, Karnataka, India.
- Senior Resident, Department of Medicine, Kasturba Medical College, Manipal University, Manipal, Karnataka, India.
- Senior Resident, Department of Medicine, Kasturba Medical College, Manipal University, Manipal, Karnataka, India.

NAME, ADDRESS, E-MAIL ID OF THE CORRESPONDING AUTHOR:

Dr. Raghavendra Rao,
4-162, Raghavendra kripa, 3rd Cross, Dasharath Nagar, Manipal-576104, India.
E-mail: ragsmanipal1983@gmail.com

FINANCIAL OR OTHER COMPETING INTERESTS: None.

Date of Submission: Jan 14, 2016

Date of Peer Review: Feb 22, 2016

Date of Acceptance: Mar 28, 2016

Date of Publishing: May 01, 2016