

Adult Rhabdomyosarcoma of Ethmoid Sinus Recurring as an Orbital Mass

BAHRAM ESHRAGHI¹, KAMBIZ AMELI², PASHA ANVARI³

ABSTRACT

Alveolar rhabdomyosarcoma (RMS) is a primitive, malignant, round cell neoplasm derived from mesenchymal tissue that exhibits partial skeletal muscle differentiation. We describe a rare case of alveolar RMS of ethmoid sinus, recurring as an orbital mass. A 23-year-old man with the chief complaint of anosmia and mild proptosis was diagnosed with RMS of the left ethmoid sinus and orbit following an endoscopic biopsy of the mass. He was treated with chemotherapy and radiotherapy. At 12 months after diagnosis, while still on maintenance chemotherapy, he presented to our eye hospital with a large medial canthal mass and lateral globe displacement. Orbital computed tomography revealed an extraconal mass in the medial orbit of the left eye, extending posteriorly and compressing the medial rectus muscle. Notably, the ethmoid sinus was clear. Incisional biopsy was performed and the recurrence of alveolar RMS was confirmed. Alveolar RMS of the ethmoid sinus may recur as an orbital mass, even if the sinus where it originated is clear at the time of recurrence.

Keywords: Alveolar Rhabdomyosarcoma, Non-metastatic, Orbital tumor, Recurrence

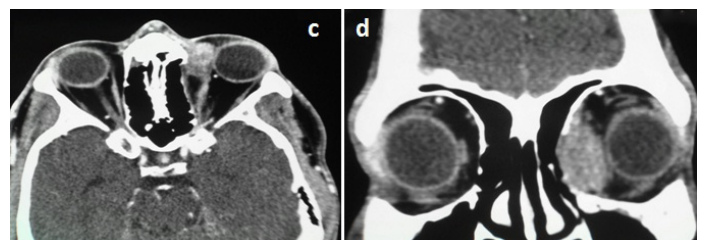
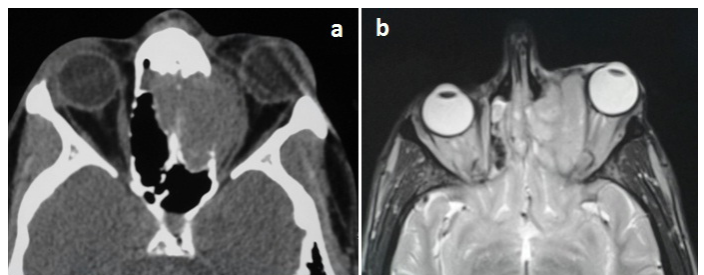
CASE REPORT

A 23-year-old man first presented to an outlying hospital with a 3-week history of anosmia and mild proptosis in his left eye. Computed tomography (CT), revealed an isodense and well-circumscribed mass arising from the left ethmoid sinus [Table/Fig-1a]. Erosions of the lamina papyracea was observed that was extending into the maxillary sinus and the left orbit while compressing the left medial rectus muscle. Extension to the crista was noted.

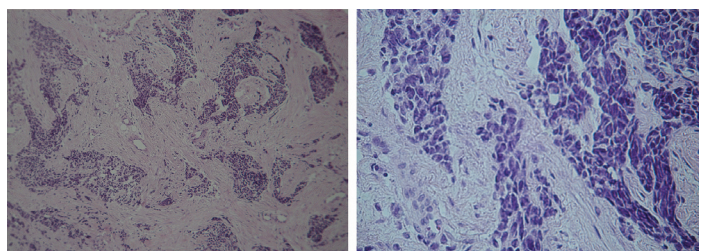
Subsequent T2-weighted magnetic resonance imaging (MRI) showed a mass in the left ethmoid sinus [Table/Fig-1b]. Alveolar rhabdomyosarcoma (RMS) was diagnosed following endoscopic biopsy by an ENT specialist, and immunohistochemistry of the mass. The patient underwent chemotherapy with vincristine, doxorubicin, and cyclophosphamide alternating with ifosfamide plus etoposide (VEC+IE), followed by 25 fractions of radiotherapy.

Maintenance chemotherapy achieved one-year remission but eventually new symptoms emerged. He was referred to our ophthalmology department. A reddish medial canthal mass was present in the left eye with periorbital puffiness, injection of the nasal conjunctiva and diffuse punctate epithelial erosions. The mass in the medial orbital wall was relatively large (30 mm in diameter), palpable, and non-mobile. The globe was displaced laterally. There was slight left gaze diplopia and limitation of abduction and adduction. Other ocular examinations were normal and his corrected visual acuity was 20/20 OU.

Spiral axial and coronal CT of the orbit [Table/Fig-1c,d] revealed an extraconal mass in the medial orbit of the left eye, extending posteriorly, causing dystopia of the globe, and compressing the medial rectus muscle. Remarkably, the ethmoid and maxillary sinuses were clear. An extensive preoperative metastatic work-up was negative. Inferior transconjunctival orbitotomy was performed to obtain an incisional biopsy. A whitish avascular tumour was found. Immunohistochemical staining for actin and myogenin was positive [Table/Fig-2]. Round myoblasts with abundant eosinophilic cytoplasm were identified. With a diagnosis of recurrence of alveolar RMS, the patient received his second round of chemoradiotherapy. At the 3-month follow-up visit, the mass was reduced in size by 80% and disappeared completely in the weeks following the treatment. However, he had developed dry eye



[Table/Fig-1a]: Axial orbital CT scan without contrast showing left ethmoidal sinus mass with extension to the orbit. **[Table/Fig-1b]:** Axial T2-weighted MRI showing ethmoidal sinus mass infiltrating to the orbit. **[Table/Fig-1c]:** 12 months after initial therapy: Axial orbital CT scan demonstrating extraconal mass in the medial orbit. **[Table/Fig-1d]:** 12 months after initial therapy: Coronal CT scan showing a left medial orbital mass and paranasal sinuses that are clear.



[Table/Fig-2]: Fibrous tissue infiltrated by sheets and nests of monomorphic round cell tumour, Hematoxylin and eosin stain (a, $\times 100$) (b, $\times 400$). (a) IHC staining for Actin shows strong diffuse cytoplasmic expression. (b) IHC staining for Myogenin shows strong positive nuclear reactivity in tumoural cells.

symptoms following radiotherapy. The patient has been recurrence-free for two years.

DISCUSSION

Rhabdomyosarcoma (RMS) is a high-grade neoplasm of mesenchymal origin that arises from primitive skeletal muscle cells [1]. It is a common soft-tissue malignancy in children and adolescents but is infrequent in adults. Alveolar RMS is an aggressive subtype with a distinct histology, comprising of small round cells and has a poor prognosis. Only a few cases of alveolar RMS of sinus and orbit have been reported in adults.

Metastasis and recurrence of adult RMS is associated with a more unfavorable prognosis. Moon et al., described a patient with alveolar RMS of the ethmoid sinus with extending to the orbit and cervical lymph node involvement, who was treated with surgery and chemoradiotherapy, but died after seven months because of metastasis that progressed to the spine [2]. Similarly, Torres-Peña et al., described two adults with alveolar RMS, one patient showed the involvement of ethmoid sinus and right orbit; in the other patient the mass was centered at the nasal cavity and infiltrated the orbit and the ethmoidal and frontal sinuses [3]. Both of the patients died because of systemic complications associated with the invasion, after two

above, where non-metastatic RMS is associated with no recurrence, our case is markedly different because our patient experienced recurrence, but did not have metastatic disease [Table/Fig-3].

Furthermore, some reports have indicated that orbital and labial RMS occurs after an injury [7] however; our patient did not have any history of prior injury.

CONCLUSION

Although the established protocols for the treatment of RMS target the pediatric population, there is a compelling need to extend and adapt the available protocols for adults. Nevertheless, our patient's response to the treatment was remarkably good and no metastasis was detected after 2-years of follow-up. The prognosis of RMS greatly depends on prompt diagnosis and treatment. We believe our case demonstrates that alveolar RMS of the ethmoid sinus may recur as an orbital mass, even if the sinus where it originated is startlingly clear at the time of recurrence.

Author	Age Sex	Location	Treatment	Recurrence	Metastasis	Outcome
Moon, 2006 [2]	48 M	Ethmoid sinus extending to the orbit	Surgery and chemoradiotherapy	No	Yes	Died after 7 months
Bagdonaite, 2013 [4]	52 M	Paranasal sinuses extending into the orbit	Chemoradiotherapy	No	No	Two years of follow-up
Sanz-Marco, 2014 [5]	25 F	Ethmoidal sinus and orbit	Chemoradiotherapy	No	No	51 months of follow-up
Parikh, 2014 [6]	40 M	Maxillary sinus extending to the left orbit, bilateral paranasal sinuses, and nasal cavity	Chemotherapy and possibly radiotherapy	No	Yes	Undergoing treatment
Torres-Peña, 2015 [3]	24 M	Ethmoid sinus and right orbit	Chemoradiotherapy	Yes	Yes	Died after 24 months
Torres-Peña, 2015 [3]	26 M	Nasal cavity, orbit, the ethmoidal and frontal sinuses.	Chemoradiotherapy	No	Yes	Died after 5 months
Current case	23 M	Ethmoid sinus, recurring as an orbital mass	Surgery and chemoradiotherapy	Yes	No	recurrence-free for two years

[Table/Fig-3]: Comparison of the outcomes in alveolar rhabdomyosarcoma patients with orbit and sinus involvement.

years and five months, respectively. Unlike the other reported cases of RMS of the orbit and sinuses, where the recurrence accompanied metastasis and mortality, the recurrence in our patient was confined to the orbit. While the initial RMS originated from the sinus, the recurrence did not affect the sinus and it remained clear.

Bagdonaite et al., described a case of nonmetastatic alveolar RMS of the paranasal sinuses extending into the orbit that was treated with chemoradiotherapy and had no recurrence after two years of follow-up [4]. Similarly, Sanz-Marco et al., described a patient with ethmoidal sinus orbital alveolar RMS that was treated with chemotherapy and radiotherapy and had no recurrence after 51 months of follow-up [5]. Parikh et al., presented a case of alveolar RMS of the maxillary sinus extending to the left orbit, bilateral paranasal sinuses, and nasal cavity, and had bilateral enlargement of the cervical lymph nodes [6]. In direct contrast to cases described

REFERENCES

- [1] Wu T-H, Huang J-S, Wang H-M, Wang C-H, Yeh K-Y. Long-term survivors of adult rhabdomyosarcoma of maxillary sinus following multimodal therapy: case reports and literature reviews. *Chang Gung Med J.* 2010;33(4):466–71.
- [2] Moon HS, Kwon SW, Lee JH. A case of alveolar rhabdomyosarcoma of the ethmoid sinus invading the orbit in an adult. *Korean J Ophthalmol.* 2006;20(1):70–5.
- [3] Torres-Peña JL, Castrillo AIR, Mencia-Gutiérrez E, Gutiérrez-Díaz E, Rodríguez-Peralto JL, Bengoa-González Á. Nasal Cavity or Alveolar Paranasal Sinus Rhabdomyosarcoma with Orbital Extension in Adults: 2 Cases. *Plast Reconstr Surg Glob Open. Wolters Kluwer Health;* 2015;3(6).
- [4] Bagdonaite L, Jeeva I, Chang BYP, Kalantzis G, El-Hindy N. Multidisciplinary Management of Adult Orbital Rhabdomyosarcoma*. *Orbit. Taylor & Francis.* 2013;32(3):208–10.
- [5] Sanz-Marco E, España E, Alamar A, Pérez-Rojas J, López-Prats MJ, Díaz-Llopis M. Orbital alveolar rhabdomyosarcoma masked by ethmoid sinusitis in a 25-year-old. *Arch la Soc Española Oftalmol. (English Ed. Elsevier;* 2014;89(5):182–5.
- [6] Parikh D, Spindle J, Linden C, Bardarov S, Shinder R. Adult Rhabdomyosarcoma of the Maxillary Sinus with Orbital Extension. *Orbit. Taylor & Francis;* 2014;33(4):302–04.
- [7] Backhouse OCE, Cove P, Bowen DI. Rhabdomyosarcoma masked by orbital trauma. *Int J Oral Maxillofac Surg. Elsevier;* 1997;26(5):374–75.

PARTICULARS OF CONTRIBUTORS:

1. Associate Professor, Department of Ophthalmology, Farabi Eye Research Hospital, Tehran University of Medical Sciences, Tehran, Iran.
2. Resident, Department of Ophthalmology, Farabi Eye Research Hospital, Tehran University of Medical Sciences, Tehran, Iran.
3. Resident, Department of Ophthalmology, Farabi Eye Research Hospital, Tehran University of Medical Sciences, Tehran, Iran.

NAME, ADDRESS, E-MAIL ID OF THE CORRESPONDING AUTHOR:

Dr. Pasha Anvari,
Farabi Eye Research Hospital, Tehran University of Medical Sciences, Qazvin Sq. Tehran, Iran.
E-mail: panvari@razi.tums.ac.ir

FINANCIAL OR OTHER COMPETING INTERESTS: None.

Date of Submission: **Nov 02, 2015**

Date of Peer Review: **Nov 17, 2015**

Date of Acceptance: **Dec 16, 2015**

Date of Publishing: **Apr 01, 2016**