

JOURNAL OF CLINICAL AND DIAGNOSTIC RESEARCH

How to cite this article:

JAIN V K, SINGH Y, SHUKLA A, MITTAL D. TUBERCULOUS OSTEOMYELITIS OF STERNUM: A CASE REPORT. *Journal of Clinical and Diagnostic Research* [serial online] 2007 June [cited: 2007 June 4]; 3:163-167

Available from

http://www.jcdr.net/back_issues.asp?issn=0973-709x&year=2007&month=June&volume=1&issue=3&page=163-167&id=60

CASE REPORT

Tuberculous Osteomyelitis Of Sternum: A Case Report

JAIN V K, SINGH Y, SHUKLA A, MITTAL D

ABSTRACT

Primary mycobacterial infection of the sternum is extremely uncommon. We present a case of tuberculous osteomyelitis of sternum successfully treated with four drug antituberculous therapy. Tuberculous sternal osteomyelitis is rare entity and one should suspect tuberculosis in a case of chronic draining sinus.

Key message

1. Tuberculous sternal osteomyelitis is an extremely rare entity.
2. It should be suspected in regions where tuberculosis is prevalent.
3. It should be treated by medical treatment with or without surgery.

Key words Sternum; Tuberculosis; Osteomyelitis

Introduction

Sternal tuberculous osteomyelitis is exceedingly rare. Kelly and Chetty reviewed the world literature till 1985 and found only 6 cases of sternal tuberculosis [1].

Through various search engines (Pubmed, Google, Embase, Altavista) we found fewer than 35 cases of sternal tuberculosis in the world English literature [2],[3],[4],[5],[6],[7],[8]. We report a case of sternal tuberculosis with draining sinus.

Case report

An 18-year-old boy from low socio economic background presented with two months history of pain and draining sinus over the sternum. The pain had started insidiously, and gradually worsened with time. The pain was dull and aching and the patient reported it as a 5 on the scale of 1-10 with 10 being the most severe. The pain was non-radiating and patient reported no pain elsewhere, the pain was relieved by anti inflammatory

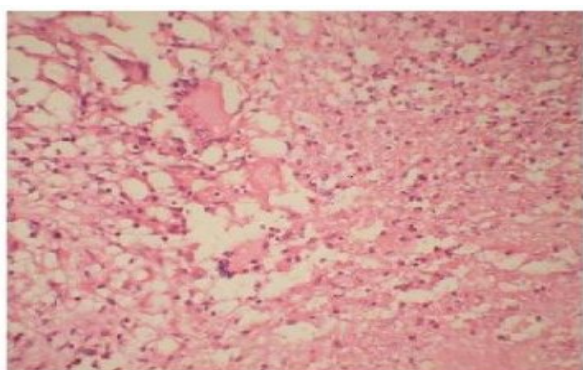
medications and was aggravated by physical activity. There was associated history of fever, weight loss, loss of appetite, night sweats, malaise and fatigue. There was no history of trauma. The patient had no history of previous illness, injuries and or surgery. His father was treated for pulmonary tuberculosis in the past. There was no history of cough or dyspnoea. On physical examination, the patient patient was ill and reported moderate to severe pain in the sternal region. Physical examination revealed sinus over the sternum. The sinus was of about less than a cm in size and draining serous material. The sinus was extended up to the bone and adhered to the underlying tissues.

On palpation and percussion, there was tenderness over sternum. However there was no tenderness over spine and para spinal muscles in the thoracic region. The range of motion of spine was within normal limits. There was no lymphadenopathy. The abdomen was soft and non tender with no organomegaly. Other systems were normal. Laboratory findings revealed elevated erythrocyte sedimentation rate (ESR) of 50 mm (Westergren method) after one hour and a positive C- reactive

Corresponding Author Dr. Jain V K., Department of Orthopaedics
Dr.RML Hospital, NewDelhi, India
Phone: 91-9968277722, E-mail : drvijay_ortho74@rediffmail.com

protein (CRP) test. A mantoux tuberculin skin test (purified protein derivative, 5 tuberculin units) was positive with 14 mm of induration observed 48 hours after administration. A plain chest radiograph posterior-anterior and lateral views, showed no lung infiltration, pleural effusion, enlargement of hilar lymph nodes and any bone involvement. A sinus tract biopsy was taken blindly under local anesthesia and histologic examination of the biopsy showed caseous necrosis with an accumulation of epithelioid cells and Langhan's giant cells, The diagnosis was compatible with tuberculosis. [Table/fig1]. Ziehl -nelsen stain was positive for Acid Fast Bacilli (AFB) and a positive culture for AFB was present on microbiologic examination.

Table/fig1

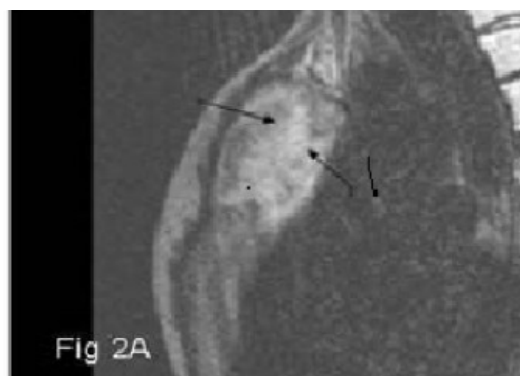

Photomicrograph shows large areas of caseous necrosis along with epithelioid cell granuloma and Langhan's giant cells, H&E x 400

On Magnetic Resonance Imaging (MRI) T2 and T2 STIR images taken in different planes showed destruction, soft tissue swelling, caseation and cold abscess formation. Soft tissue swelling and expansion were seen as T2 hyperintensity, while caseation and necrosis were seen as T2 hypointense lesion [Table/fig 2],[Table/fig 3], [Table/fig 4], [Table/fig 5].

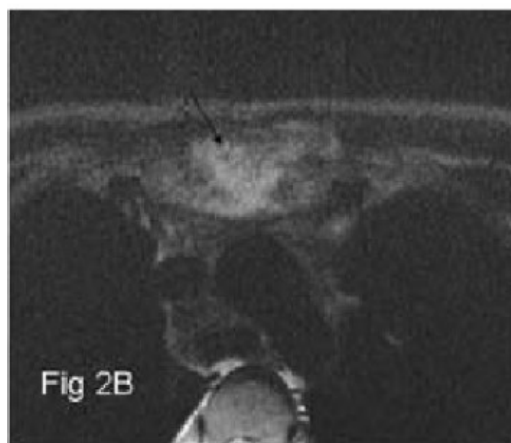
The patient received 4 months of anti-tubercular chemotherapy, consisting of four drugs (isoniazid [INH], pyrazinamide, ethambutol, and rifampicin). He was given 3 drugs (INH, rifampicin and ethambutol) in the next four months and 2 drugs (INH and rifampicin) for 10 months. His fever was subsided after 2 months of treatment and at the end of anti-tuberculous treatment, the sinus healed without any complications his appetite and growth indices improved significantly.

Table/fig 2



T2 Weighted sagittal image of sternum showing expansion with cold abscess formation and caseous necrosis (Black arrows).

Table/fig 3

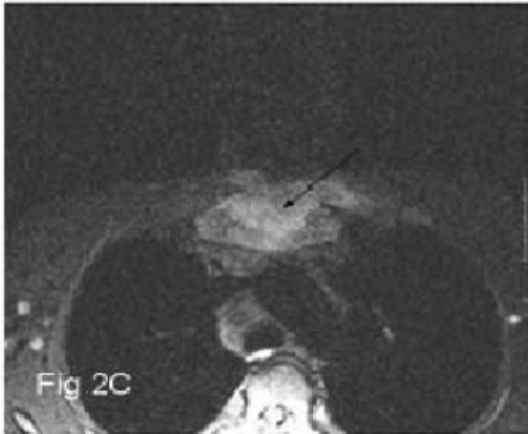


T2 Weighted axial image of sternum showing increased signal, soft tissue swelling and expansion (arrow).

Discussion

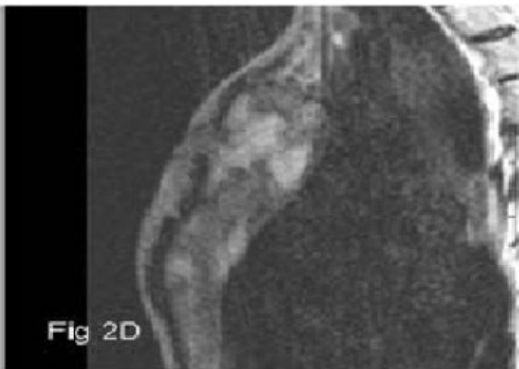
The sternum as the site of infection is infrequently encountered and tuberculous sternal osteomyelitis is even rarer. Tuberculosis of bones and joints accounts for 1–3% of patients with tuberculosis and isolated sternum tuberculosis representing less than 1% tubercular osteomyelites [9],[10]. Less than thirty five cases have been reported so far in the world literature [2],[3],[4],[5],[6],[7],[8]. In a large series from india, by Tuli and Sinha, out of 980

Table/fig 4



T2 fat suppressed image shows hyperintensity in sternal region with a hypointense centre suggesting caseation within the lesion (arrow).

Table/fig 5



T2 Weighted image shows patchy hyperintensity in sternum with expansion

cases of osteoarticular tuberculosis, 14 (1.5%) were found to be due to tuberculosis of the sternum [11] In a review of 417 tuberculosis (TB) patients, Davies et al reported only two cases of sternal tuberculosis [12]. Since 1985, sternal TB has been reported in association with spontaneous fracture of sternum, disseminated tuberculosis, diabetes mellitus and post coronary by pass surgery. Atypical mycobacteria are known to cause post operative infection [13],[14]. Sternal osteomyelitis of tuberculous origin is generally caused by reactivation of latent foci of primary

tuberculosis formed during hematogenous or lymphatic dissemination, in contrast to pyogenic osteomyelitis. Direct extension from contiguous mediastinal lymph nodes has also been described [2] The known risk factors for tuberculosis are underlying debilitating disorders, corticosteroid therapy, malnutrition, low socio-economic status, and ethanol abuse, history of exposure to tuberculosis, HIV infection and immunocompromised states [11]. Similarly the index patient also belongs to low socio-economic class. Sternal TB presents insidiously predominantly with pain and swelling. Concomitant extrasternal tuberculosis has been reported in 8 out of 20 cases reviewed by Mclellan et al [15]. Sternal TB has been predominantly described in adult patients as in our case however there are few paediatric cases in record. Sternal tuberculosis has also been reported after BCG vaccination in paediatric age group. Kato et al and corrales et al reported sternal TB in 9 month and 13 month old child respectively [16],[17]. Imaging technique as seen in index patient plays an important role in diagnosis and follow up. According to Tuli and Sinha[11], radiological signs occur much later than the presenting clinical features, and abscesses or sinuses are present much before the focus is detected radiologically, similarly in the index patient chest radiograph did not reveal any lesion. The Computed tomography (CT) scan is more sensitive for anatomical localization and in detecting osseous destruction and soft tissue abnormalities. Khalil et al reviewed the utility of CT scan findings for the diagnosis of chest wall TB and described characteristic ring enhancing hypodense soft tissue lesion [18]. Atasoy et al suggested the role of Magnetic Resonance Imaging (MRI) for detecting early marrow and soft tissue involvement due to high contrast resolution of MRI [19]. Tuberculous osteomyelitis is characterized by low signal replacement of the normal marrow fat signal on T1-weighted images, with high signal intensities on T2-weighted images and enhancement on T1-weighted images [20]. However early diagnosis is established with microbiologic and histopathologic examination. In the present case, biopsy was useful to confirm the presence of TB or exclude other conditions such as pyogenic infections and malignancy. Possible complications of sternal tuberculous osteomyelitis include secondary infection, fistula formation, spontaneous fractures of the sternum, compression or erosion of the large blood vessels, compression of the trachea and migration of tuberculous abscess

into the mediastinum, pleural cavity or subcutaneous tissues [2] similarly the index patient presented with discharging sinus due to subcutaneous extension of the tuberculous abscess. Treatment is based on long duration antituberculous multidrug therapy, however some authors believe that surgical treatment is necessary to prevent recurrence. Sarlak et al [21] treated a case of primary sternal TB with resection and rotational flap. Hajjar et al [22] did resection and reconstruction of primary sternal TB in an 81 year old man. Recently Ford et al [23] described successful management of tuberculous osteomyelitis of sternum with debridement and vacuum assisted closure. In our case we treated the patient successfully with multidrug therapy alone. Patient is doing well after one year post antituberculous therapy.

Conflict of Interest: None declared

References

- [1] Kelly CA, Chetty MN. Primary sternal osteomyelitis. *Thorax*. 1985;40(11):872-3.
- [2] Sharma S, Juneja M, Garg A. Primary tubercular osteomyelitis of the sternum. *Indian J Pediatr*. 2005;72(8):709-10.
- [3] Wang TK, Wong CF, Au WK, Cheng VC, Wong SS. Mycobacterium tuberculosis sternal wound infection after open heart surgery: a case report and review of the literature. *Diagn Microbiol Infect Dis*. 2007;12; [Epub ahead of print]
- [4] Gopal K, Raj A, Rajesh MR, Prabhu SK, Geothe J. Sternal tuberculosis after sternotomy for coronary artery bypass surgery: a case report and review of the literature. *J Thorac Cardiovasc Surg*. 2007;133(5):1365-6.
- [5] Ekingen G, Guvenc BH, Kahraman H. Multifocal tuberculosis of the chest wall without pulmonary involvement. *Acta Chir Belg*. 2006;106(1):124-6.
- [6] Zhao X, Chen S, Deanda A Jr, Kiev J. A rare presentation of tuberculosis. *Am Surg*. 2006;72(1):96-7.
- [7] Bandyopadhyay SK, Moulick A, Ghosal J, Dutta A. Pre sternal cold abscess. *J Assoc Physicians India*. 2005;53:866.
- [8] Rivas P, Gorgolas M, Gimena B, Sousa J, Fernandez-Guerrero ML. Sternal tuberculosis after open heart surgery. *Scand J Infect Dis*. 2005;37(5):373-4.
- [9] Boh JA, Janner D. Mycobacterium tuberculosis sternal osteomyelitis presenting as anterior chest wall mass. *Pediatr Infect Dis J* 1999;18:1028-29.
- [10] Watts HG, Angrles L, Lifesto RM. Current concepts review: tuberculosis of bones and joints. *J Bone Joint Surg Am* 1996; 78:288-298.
- [11] Tuli SM, Sinha GP. Skeletal tuberculosis "Unusual" lesions. *Indian Journal of Orthopaedics* 1969; 3: 5-18.
- [12] Davies PD, Humphries MJ, Byfield SP, Nunn AJ, Darbyshire JH, Citron KM et al. Bone and joint tuberculosis. A survey of notifications in England and Wales. *J Bone Joint Surg Br*. 1984 66-B: 326-330.
- [13] Samuels LE, Sharma S, Morris RJ, Solomon MP, Granick MS, Wood CA et al. Mycobacterium fortuitum infection of the sternum. Review of the literature and case illustration. *Arch Surg*. 1996;131:1344-6.
- [14] Karnak I, Akcoren Z, Gogus S, Caglar M, Tanyel FC. Granulomatous osteomyelitis of the sternum presenting with a parasternal mass: a possible relation to the bacillus Calmette-Guerin vaccine. *J Pediatr Surg*. 1999;34(10):1534-6.
- [15] McLellan DG, Philips KB, Corbett CE, Bronze MS. Sternal osteomyelitis caused by mycobacterium tuberculosis: case report and review of the literature. *Am J Med Sci*. 2000; 319(4):250-4.
- [16] Kato Y, Horikawa Y, Nishimura Y, Shimoda H, Shigeto E, Ueda K. Sternal tuberculosis in a 9-month-old infant after BCG vaccination. *Acta Paediatr*. 2000;89(12):1495-7.
- [17] Corrales IF, Cortes JA, Mesa ML, Zamora G. Sternal osteomyelitis and scrofuloderma due to BCG vaccination. *Biomedica*. 2003;23(2):202-7.
- [18] Khalil A, Le Breton C, Tassart M, Korzec J, Bigot J, Carette M. Utility of CT scan for the diagnosis of chest wall tuberculosis. *Eur Radiol*. 1999;9(8):1638-42.
- [19] Atasoy C, Oztekin PS, Ozdemir N, Sak SD, Erden I, Akyar S. CT and MRI in tuberculous sternal osteomyelitis: a case report. *Clin Imaging*. 2002;26(2):112-5.
- [20] Shah J, Patkar D, Parikh B, Parmar H, Varma R, Patankar T, Prasad S. Tuberculosis of the sternum and clavicle: imaging findings in 15 patients. *Skeletal Radiol*. 2000;29(8):447-53
- [21] Sarlak AY, Gundes H, Gundes S, Alp M. Primary sternal tuberculosis: a rare unhealed case treated by resection and local rotational flap. *Thorac Cardiovasc Surg*. 2001;49(1):58-9.

[22] Hajjar W, Logan AM, Belcher PR. Primary sternal tuberculosis treated by resection and reconstruction Thorac Cardiovasc Surg. 1996;44(6):317-8.

[23] Ford SJ, Rathinam S, King JE, Vaughan R. Tuberculous osteomyelitis of the sternum: successful management with debridement and vacuum assisted closure. Eur J Cardiothorac Surg. 2005;28(4):645-7.