

Postpartum Bilateral Sacroiliitis caused by *Brucella* Infection

MUSTAFA OZTURK¹, FERDI YAVUZ², DEMET ALTUN³, MUSTAFA ULUBAY⁴, FAHRI BURÇIN FIRATLIGIL⁵

ABSTRACT

Early diagnosis of this septic sacroiliitis is difficult because symptoms are nonspecific during the postpartum period. In this case we discuss about a patient with bilateral buttock pain unresolved with painkillers and rest, after an induction delivery. A 31-year-old woman was presented to our clinic on the second week of postpartum period with bilateral buttock pain. She was subfebrile and had no apparent abnormality on her pelvic X-ray. The pain was so severe that she was unable to walk properly. Sacroiliac MRI during the acute episode of pain showed bone marrow oedema and fluid within the bilateral sacroiliac joint. She was found seropositive for brucellosis and the patient completely recovered with antibiotherapy treatment. We stopped our patient from breastfeeding when the Rose Bengal test turned out positive. *Brucella* sacroiliitis should be considered in puerperium period women when buttock pain and difficulty in walking are present and pain is unresponsive to analgesics.

Keywords: Buttock pain, Magnetic resonance imaging, Puerperium

CASE REPORT

A 31-year-old primigravida applied to our clinics with complaints of uterine contractions at term and progressed to a spontaneous vaginal delivery simplified by a mediolateral episiotomy on the right. She was discharged on the second day postpartum and was not prescribed antibiotic treatment. On the second week postpartum, she reported mild perineal and right buttock pain, pyrexia, coxalgia, and low back pain (LBP) without systemic symptoms. She was referred to a psychiatry clinic because of her history of having panic attacks. Physiotherapy and simple analgesics were prescribed. However, her buttock pain worsened and began to radiate to her leg. The pain increased with ambulation by the 18th day postpartum. She was then admitted to clinic in a wheelchair. The pain was so severe that she was unable to walk properly. She had no apparent abnormality according to her pelvic X-ray. On admission, she had tenderness in the hip and sacral area. She had a body temperature of 38.5°C (the patient remained intermittently febrile), total white cell count of 5100/mm³, C-reactive protein (CRP) level of 73 mg/dl (N: 0-5), mild elevation of alkaline phosphatase levels (172 U/L, 38-155), and erythrocyte sedimentation rate (ESR) of 56 mm/h.

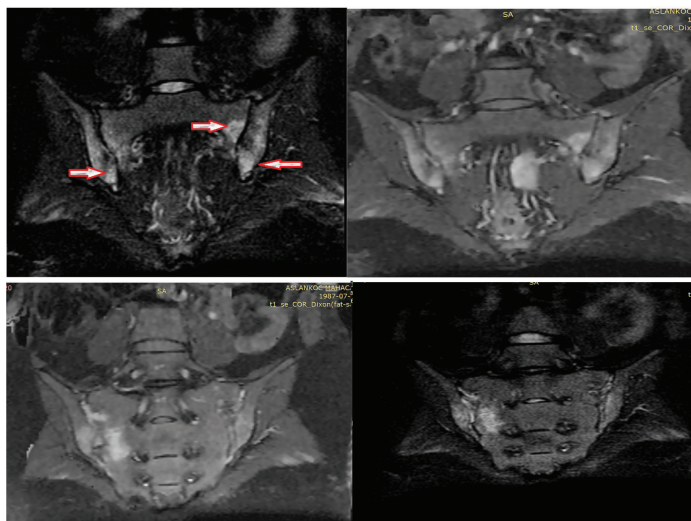
Antistreptolysin-otitre and rheumatoid factor levels were in a normal range. She was found positive for Rose Bengal and Wright agglutination tests for brucellosis. The patient was hospitalized in the infection disease clinic because of brucellosis on the 19th day postpartum. Breastfeeding was ceased. Sacroiliac magnetic resonance imaging (MRI) was consistent with bilateral sacroiliitis. Sacroiliac MRI during the acute episode of pain showed bone marrow oedema and fluid within the bilateral sacroiliac joint [Table/ Fig-1].

Initially, 1g ceftriaxone was administered intravenously. After four days of doxycycline (100 mg twice daily) and rifampin (300 mg twice daily), the patient was afebrile and a dramatic improvement in the patient's symptoms was observed. She was discharged on a six-month course of oral rifampin and doxycycline. After four months, intravenous gentamicin (320 mg) was injected once a week because of increasing pain. Although the buttock pain did not completely resolve until six months after discharge, she was doing well with normal gait pattern.

DISCUSSION

Approximately 80% to 90% of outpatients apply to clinics with the most seen complaint of LBP [1]. Sacroiliac joint disease usually presents with LBP that increases with ambulation. In the postpartum period, it may pose as a diagnostic challenge as pain in the lower back and buttocks is common and often nonspecific [2]. The pelvic ligaments relax during pregnancy, but the increased pelvic movements and subsequent microtrauma to joint surfaces make pregnant women susceptible to transient bacteraemia [3]. Although there are many *brucella* sacroiliitis cases described in the literature, being in the postpartum period is rare.

Brucella infection is prevalent among 4.8% of the general population in Turkey [4]. Animal contact and the consumption of unpasteurized milk and milk products are the common modes of transmission of the disease to humans. The incubation period of brucellosis is generally one to two months. Up to one-third of patients have musculoskeletal system involvement [5]. Back pain, fever, and constitutional symptoms are the most common manifestations. In the literature, 21%–55% of infected individuals experience involvement of the bone, mostly sacroiliitis or spondylitis [6]. Although an ESR is generally suggestive of inflammation or infection, it is only



[Table/Fig-1]: Images from a T2-weighted MRI series showing bone marrow oedema and fluid within the bilateral sacroiliac joint

elevated in 50% of patients with brucellosis [7]. In our case, ESR was markedly elevated (56 mm/h). The presence of fibrinogen, globulins, and cholesterol can increase ESR levels until the fourth week postpartum. After evaluating the CRP level, we found the CRP to be 73 mg/dl (N: 0-5).

Pain in the lower back and buttocks is common and often nonspecific during the pregnancy and postpartum. There is ongoing subfebril fever in our patients and waist and hip pain had sacroiliac region. The sacroiliitis (pyogenic; *brucella*, tuberculosis, *staphylococcus* etc), aseptic necrosis and paravertebral abscess must be considered in the differential diagnosis. When pregnant women develop sacroiliitis, the initial manifestations can be attributed to pregnancy-associated arthropathy. But this patient's pain disappeared after rest. The differential diagnosis with pyogenic sacroiliitis is very important. It is usually secondary to pelvic infections such as chorioamnionitis, postpartum endometritis. Typical radiological changes become apparent this lessons. Postpartum *brucella* sacroiliitis is rarely observed. In the literature, all cases of postpartum sacroiliitis involved one side (mostly the left side) except for two cases that showed bilateral involvement [2]. Both cases were pyogenic sacroiliitis (*streptococcus* or *staphylococcus*).

Although postpartum back pain usually depends on postpartum uterine involution, it can still be sacroiliitis although rarely. Analgesics are usually prescribed. If complaints continue, patients are referred to physical medical rehabilitation and neurology clinics. In our case, we referred the patient to the psychiatry clinic because she suffered from panic attacks. However, the patient's LBP complaint worsened, and she was admitted to our clinic in a wheelchair. Neonatal infection can be contaminated transplacentally during delivery or by breast milk. Mothers who breastfeed may transmit the infection to their infants. Thus, we stopped our patient from breastfeeding when the Rose Bengal test turned out positive. The patient at risk was treated for brucellosis, but the risk of her baby becoming infected was eliminated in three days. Third week postpartum, we evaluated the baby's Rose Bengal test and the result was negative. One week later, we again evaluated the baby's Rose Bengal test again, and the result was negative.

When we reviewed recent literatures, a six-month course of medical treatment with rifampin, doxycycline, and streptomycin is suggested

to reduce incidence of relapse in the cases of osteoarticular involvement [8]. Relapse can be seen at approximately 10.6% to 11% of patients within osteoarticular or focal involvement [6]. As replacement, streptomycin with a short course of gentamycin when administered in combination with doxycycline can be used [9]. We followed this course of treatment. We had our patient take doxycycline, rifampin, and gentamycin because of sacroiliac involvement. A combination treatment regimen consisting of rifampin and TMP-SMX may be used in breastfeeding women with brucellosis without sacroiliac involvement for whom doxycycline treatment is contraindicated. Furthermore, breastfeeding women can safely continue breastfeeding with this treatment regimen.

CONCLUSION

In the postpartum period, *brucella* sacroiliitis should be considered in women when buttock pain and difficulty in walking are present and coxalgia is unresponsive to analgesics. Moreover, infants should be evaluated for *brucella*.

REFERENCES

- [1] Gopalakrishnan N, Nadhamuni K, Karthikeyan T. Categorization of pathology causing low back pain using magnetic resonance imaging (MRI). *J Clin Diagn Res*. 2015;9(1):TC17-20.
- [2] Gordon G, Kabins SA. Pyogenic sacroiliitis. *Am J Med*. 1980;69(1):50-56.
- [3] Almoujahed MO, Khatib R, Baran J. Pregnancy associated pyogenic sacroiliitis: case report and review. *Infect Dis Obstet Gynecol*. 2003;11(1):53-57.
- [4] Cetinkaya Z, Aktepe OC, Ciftci IH, Demirel R. Seroprevalence of human brucellosis in a rural area of Western Anatolia, Turkey. *J Health Popul Nutr*. 2005;23:137-41.
- [5] Geyik MF, Gür A, Nas K, Cevik R, Saraç J, Dikici B, et al. Musculoskeletal involvement of brucellosis in different age groups: a study of 195 cases. *Swiss Med Wkly*. 2002;132(7-8):98-105.
- [6] Colmenero JD, Reguera JM, Martos F, Sanchez-De-Mora D, Delgado M, Causse M, et al. Complications associated with *Brucella melitensis* infection: a study of 530 cases. *Medicine (Baltimore)*. 1996;75(4):195-211.
- [7] Pourbagher MA, Pourbagher A, Savas L, Turunc T, Demiroglu YZ, Erol I, et al. Clinical pattern and abdominal sonographic findings in 251 cases of brucellosis in southern Turkey. *AJR Am J Roentgenol*. 2006;187(2):W191-14.
- [8] Bayindir Y, Sonmez E, Aladag A, Buyukberber N. Comparison of five antimicrobial regimens for the treatment of *brucellar* spondylitis: a prospective, randomized study. *J Chemother*. 2003;15(5):466-71.
- [9] Hasanjani Roushan MR, Mohraz M, Hajiahmadi M, Ramzani A, Valayati AA. Efficacy of gentamicin plus doxycycline versus streptomycin plus doxycycline in the treatment of brucellosis in humans. *Clin Infect Dis*. 2006;42(8):1075-80.

PARTICULARS OF CONTRIBUTORS:

1. Specialist, Department of Obstetrics and Gynecology, Etimesgut Military Hospital, Etimesgut, Ankara, Turkey.
2. Specialist, Department of Physical Medical Rehabilitation, Etimesgut Military Hospital, Etimesgut, Ankara, Turkey.
3. Specialist, Department of Pediatric, Etimesgut Military Hospital, Etimesgut, Ankara, Turkey.
4. Assistant Professor, Department of Obstetrics and Gynecology, Gulhane Military Medical Academy, Etlik, Ankara, Turkey.
5. Specialist, Department of Obstetrics and Gynecology, Gulhane Military Medical Academy, Etlik, Ankara, Turkey.

NAME, ADDRESS, E-MAIL ID OF THE CORRESPONDING AUTHOR:

Dr. Mustafa Ozturk,
Specialist, Department of Obstetrics and Gynecology, Etimesgut Military Hospital, Etimesgut-06100, Ankara, Turkey.
E-mail: drmozturk@gmail.com

Date of Submission: **Apr 26, 2015**

Date of Peer Review: **Aug 06, 2015**

Date of Acceptance: **Aug 26, 2015**

Date of Publishing: **Nov 01, 2015**

FINANCIAL OR OTHER COMPETING INTERESTS: None.