

# Pacinian Neuroma Presenting as Congenital Macroductyly: A Rare Case Report

SURYA RAO RAO VENKATA MAHIPATHY<sup>1</sup>, ALAGAR RAJA DURAIRAJ<sup>2</sup>, JAYAGANESH PARTHASARATHY<sup>3</sup>

## ABSTRACT

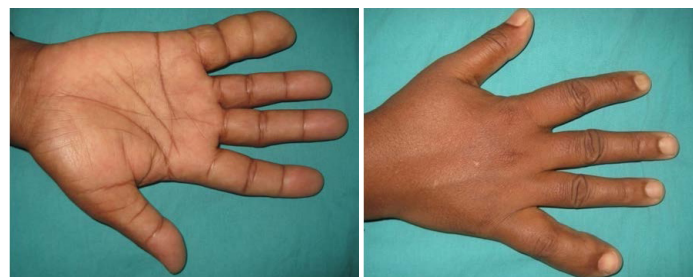Pacinian neuromas are rare benign tumours of pacinian corpuscles of the digits. They generally occur on the volar aspect of the fingertips. Pacinian corpuscles are specialised nerve endings with a lamellated structure and are regarded as pressure and vibration receptors. Here, we report a case of pacinian neuroma presenting as congenital macroductyly of the right little finger with pain for which the lesion was surgically excised.

## CASE REPORT

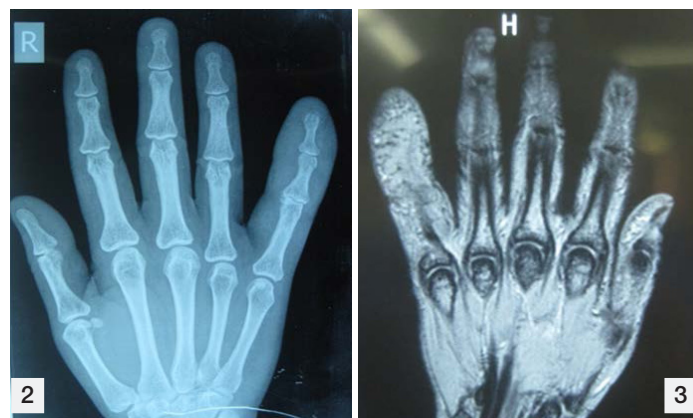A 34-year-old female patient presented to the Department of Plastic Surgery with diffuse swelling of right little finger since birth and pain in the same finger for one month duration. The swelling grew proportionately with age but there is a history of sudden increase in size for the past 6 months. On examination, there was macroductyly of the right little finger with normal skin and nail complex [Table/Fig-1a&b]. Flexor tendons were intact with no compressibility, pulsations or thrill and no distal neurovascular deficit. The swelling was soft to firm in consistency. A provisional diagnosis of a diffuse neurolipomatosis was made. Routine blood investigations, ECG, chest X-ray, X-ray of the right hand and an MRI were done.

X- ray showed a diffuse soft tissue swelling with normal bone architecture [Table/Fig-2].

MRI revealed diffuse hypertrophy of subcutaneous fat enclosing entire little finger in the palmar aspect – macrodystrophia lipomatosa, mild



[Table/Fig-1a&b]: Clinical photograph showing macroductyly of right little finger

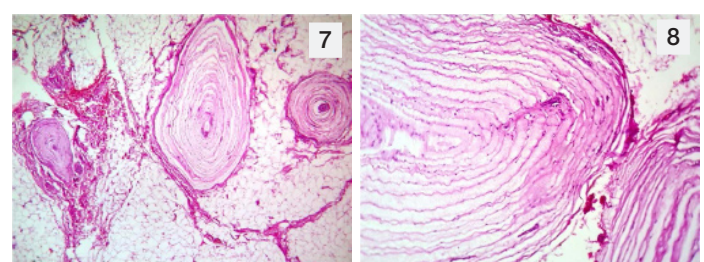
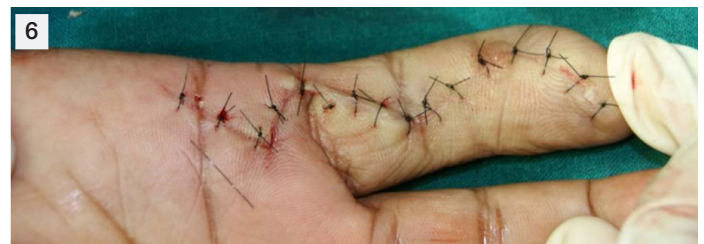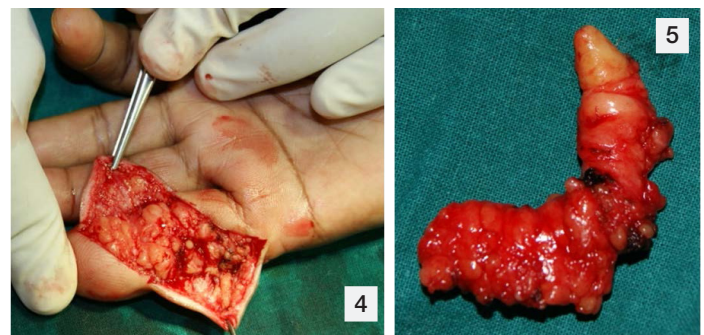


[Table/Fig-2]: X- ray showing a diffuse soft tissue swelling with normal bone architecture [Table/Fig-3]: MRI revealed diffuse hypertrophy of subcutaneous fat enclosing entire little finger in the palmar aspect – macrodystrophia lipomatosa

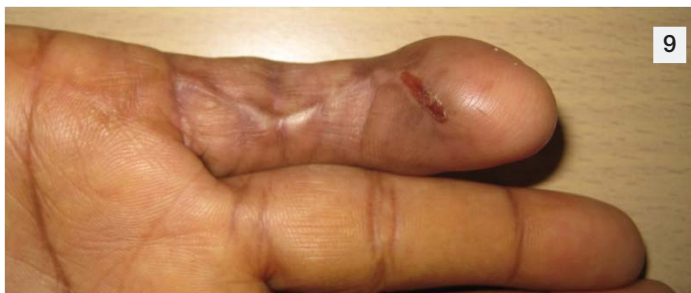**Keywords:** Benign, Digits, Pacinian corpuscles, Tumour

STIR hyperintensity in the subchondral region of articular surface of the proximal phalanx of 5<sup>th</sup> MCP joint with hyperintensity of adjacent soft tissue and the flexor tendons traversing 5<sup>th</sup> MCP joint showing inflammatory changes [Table/Fig-3].

Surgical exploration with excision of the lesion was planned. Under axillary block and tourniquet control, Bruner's incision was made [Table/Fig-4] and deepened in layers in the palmar aspect of right little finger. Lobulated fibrofatty tissue in the palmar aspect was excised including the digital neurovascular bundle on the involved side [Table/Fig-5]. Haemostasis was secured as skin closed with 5 – 0 ethilon and finger dressing applied [Table/Fig-6]. Specimen was sent for histopathological examination which showed an increased



[Table/Fig-4]: Bruner's incision made to expose lesion [Table/Fig-5]: Lesion after excision [Table/Fig-6]: Immediate postoperative picture [Table/Fig-7]: Increased number of Pacinian corpuscles separated by lobules of mature adipose tissue and areas of haemorrhage (H&E x100) [Table/Fig-8]: Increased number of Pacinian corpuscles separated by mature adipose tissue (H&E x400)



[Table/Fig-9]: A 3 month follow-up picture

number of pacinian corpuscles separated by lobules of mature adipose tissue and areas of haemorrhage-type B by Michels & Albert's classification [Table/Fig-7,8].

Postoperative period was good with some neuropraxia. Patient was discharged on the 2<sup>nd</sup> postoperative day and skin sutures were removed on the 10<sup>th</sup> postoperative day. On 3 month follow-up [Table/Fig-9], there was scar hypertrophy which was managed conservatively. Finger movements were near normal. Neuropraxia was persistent.

## DISCUSSION

Prichard and Custer in 1952 initially described Pacinian neuroma [1]. It consisted of a benign proliferation of normal or enlarged Pacinian corpuscles [1,2]. Pacinian corpuscles are tactile receptors found in the deep dermal and subcutaneous tissue [2], generally seen in palmar, plantar skin and in genitalia. On gross appearance, they resemble fat globules, but microscopically they are formed of a central un-myelinated axon with a fibrous capsule [2]. There is pericapsular fibrosis of the hyperplastic corpuscles with endoneural and perineural fibrosis [3]. Pacinian neuroma generally present in the third to fourth decade occurring in any finger, usually involving the index and middle fingers. The aetiology and pathogenesis of this rare condition is not clearly understood. However, several reports have proposed that repetitive trauma to the nerves or tendons are a precipitating factor [4-6]. Most patients complain of local tenderness [2].

Microscopically, described four neuromas have been classified into types of Pacinian four types by Rhode and Jennings [7]: a) a single individual enlarged corpuscle adherent to the epineurium of normal digital nerve; b) a grape-like cluster of normal corpuscles attached to the digital nerve by a filamentous structure; c) enlarged corpuscles arranged in a column beneath the epineurium, and;

d) multiple hyperplastic corpuscles arranged in a row along the entire length of a digital nerve. The third and fourth types (Types C and D) were clubbed together in the same category by Michel and Albert [1]. Now, Pacinian neuromas are now classified as three types. According to review of previously reported cases, the commonest type was type B [1].

In the digits, the corpuscles are close to the neurovascular bundle in the metacarpophalangeal joint and in the proximal phalangeal regions of the three central digits. The distal phalanges have more corpuscles than the middle phalanges [8]. In the hand, the lesions were intimately related to the common digital nerve of the index, middle and ring fingers [7,9] and just a few cases have been reported in the distal phalanx [10,11]. The treatment of choice is surgical excision including the deep dermis and subcutis.

## CONCLUSION

Pacinian neuromas are uncommon benign lesions and comparatively few cases have been recorded in the literature. Even though they are called neuromas, they are just a non- neoplastic hyperplasia or hypertrophy of Pacinian corpuscles, with only a few reported cases. Isolated cases of pacinian neuroma presenting as macroductyly have been reported, but here, we report a case of Pacinian neuroma, presenting as congenital macroductyly of the digit, which has not been published before.

## REFERENCES

- [1] Reznik M, Thiry A, Fridman V. Painful hyperplasia and hypertrophy of pacinian corpuscles in the hand: report of two cases with immunohistochemical and ultrastructural studies, and a review of the literature. *Am J Dermatopathol*. 1998;20:203-07.
- [2] Kenmochi A, Satoh T, Fukuyama K, Yokozeki H. Pacinian neuroma. *J Eur Acad Dermatol Venereol*. 2006;20:1384-85.
- [3] Goldman F, Garner R. Pacinian corpuscles as a cause for metatarsalgia. *J Am Podiatry Assoc*. 1980;70:561-67.
- [4] Lang-Stevenson Al. Induction of hyperplasia and hypertrophy of pacinian corpuscles. *Br Med J*. 1984;288:972-73.
- [5] Requena L, Sanguenza OP. Benign neoplasms with neural differentiation: a review. *Am J Dermatopathol*. 1995;17:75-96.
- [6] Kumar A, Darby AJ, Kelly CP. Pacinian corpuscles hyperplasia--an uncommon cause of digital pain. *Acta Orthop Belg*. 2003;69:74-76.
- [7] Rhode CM, Jennings WD Jr. Pacinian corpuscle neuroma of digital nerves. *South Med J*. 1975;68:86-89.
- [8] Stark B, Carlstedt T, Hallin RG, Risling M. Distribution of human pacinian corpuscles in the hand. a cadaver study. *J Hand Surg*. 1998;23-B:370-2.
- [9] Jones NF, Eadie P. Pacinian corpuscle hyperplasia in the hand. *J Hand Surg*. 1991;16-A:865-69.
- [10] Fletcher CDM, Theaker JM. Digital pacinian neuroma: a distinctive hyperplastic lesion. *Histopathology*. 1989;15:249-56.
- [11] Schuler FA, Adamson JE. Pacinian neuroma, an unusual cause of finger pain. *Plast Reconstr Surg*. 1978;62:576-79.

### PARTICULARS OF CONTRIBUTORS:

1. Associate Professor, Department of Plastic Surgery, Saveetha Medical College Hospital, Thandalam, Kanchipuram, India.
2. Associate Professor, Department of Plastic Surgery, Saveetha Medical College Hospital, Thandalam, Kanchipuram, India.
3. Associate Professor, Department of Pathology, Saveetha Medical College Hospital, Thandalam, Kanchipuram, India.

### NAME, ADDRESS, E-MAIL ID OF THE CORRESPONDING AUTHOR:

Dr. Surya Rao Rao Venkata Mahipathy,  
Associate Professor, Department of Plastic Surgery, Saveetha Medical College Hospital,  
Thandalam, Kanchipuram-602105, India.  
E-mail: surya\_3@hotmail.com

FINANCIAL OR OTHER COMPETING INTERESTS: None.

Date of Submission: **Apr 17, 2015**

Date of Peer Review: **Jul 16, 2015**

Date of Acceptance: **Jul 25, 2015**

Date of Publishing: **Sep 01, 2015**