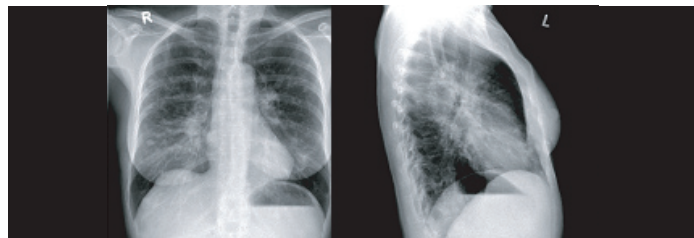

Necrotizing Sarcoid Granulomatosis (NSG): A Diagnostic Pitfall to Watch Out For!

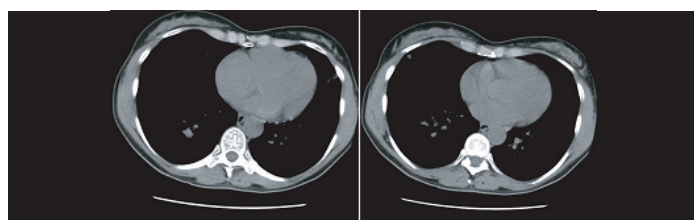
STEPHAN SCHIEKOEFER¹, CHRISTINA ZIRNGIBL², JOCHEN G. SCHNEIDER³

Keywords: Benign lung disease, Nodular infiltrates, Sarcoidosis, Systemic inflammation

Due to a 6 month history of recurrent bronchitis associated with shortness in breath a female patient in the mid-50s was referred for radiographic evaluation. The radiographic examination of chest showed rounded lesions at the level of the right central lobe and increased interstitial reticular opacity [Table/Fig-1]. The patient's history and the radiographical findings described were suspicious for malignant disease. Thus, the patient was admitted and subjected to further work-up (tumour search). A CT scan of the lungs confirmed the presence of intrapulmonary rounded nodular opacities of up to 1.5 cm in diameter corresponding to the X-ray findings [Table/Fig-2]. For histocytopathological confirmation of the origin of the nodules, a bronchoscopy was initiated. Unfortunately, the bronchoscopy with brush biopsy yielded the unspecific finding of an alveolar hyperplasia accompanied by lymphocytic and granulocytic inflammatory reaction. Finally, the patient was submitted to diagnostic partial lung resection. The histopathological evaluation of the resected, paraffin-embedded tissue revealed an overlaying, nearly confluent nodular structure of strongly hyalinized tissue with anthracotic pigmentation and peripheral accumulation of epithelioid cell granulomas accompanied by infiltration of lymphoid cells. No PAS-positive micro-organisms were detectable [Table/Fig-3a&b].

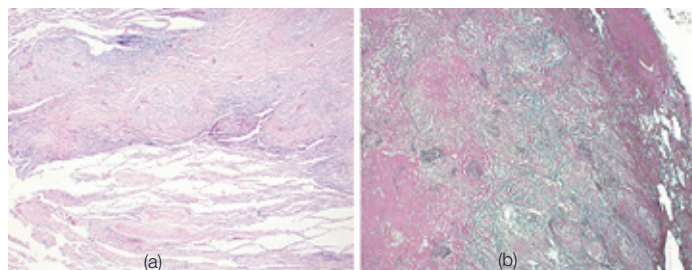


[Table/Fig-1]: Plain chest X-ray showing the presence of increased interstitial pronounced opacity (in PA and lateral view)



[Table/Fig-2]: Axial CT scan of the chest showing several rounded opacities in various sizes (up to 1.5 cm in diameter)

Necrotizing sarcoid granulomatosis (NSG) is a rare condition related to the family of sarcoidosis [1]. In imaging it can be confused with a malignant aetiology. Thus, patients may be confronted with the suspicion



[Table/Fig-3a,b]: (a) Histopathological work-up (5x) of resected lung tissue showing sterile, nodular epithelioid cell granulomas, (b) increased fibro-hyalinized tissue with anthracotic pigmentation and peripheral accumulation of inflammatory cell infiltrates

of suffering from malignant disease. Based on imaging direct referral to oncology centers and even initiating therapy might be discussed before further differential diagnoses are considered. However, not all suspicious pulmonary nodules are malignant. The diagnosis still has to be made by histopathology of cellular material from broncho-alveolar lavage (cytological examination) or trans-bronchial biopsy. Unfortunately, in our case, these procedures did not yield a clear diagnosis. A diagnostic lung resection had to be performed.

The diagnosis was Necrotizing sarcoid granulomatosis of the lungs. The patient was accordingly treated with anti-inflammatory agents (non-steroidal antirheumatic drugs) and symptoms were regressive thereafter. NSG is a rare but generally benign disease that shares similarities with pulmonary vasculitis and classical sarcoidosis [2]. It can reveal as benign cause of seemingly deleterious situation. It should always be taken into consideration, as differential diagnosis for intrapulmonary or systemic disease, alone or in association with other entities [3].

ACKNOWLEDGEMENTS

We thank Prof. Paul Schlimmer and Dr. Hans E. Blass for their scientific advice. We thank Dr. Pierre Garcia and Dr. Manuel Buttini for technical support.

REFERENCES

- [1] Liebow AA. The J. Burns Amberson lecture: pulmonary angitis and granulomatosis. *Am J Rev Respir Dis.* 1973; 108(108): 1-17.
- [2] Giraudo C, Nannini N, Balestro E, Meneghin A, Lunardi F, Polverosi R, et al. Necrotizing sarcoid granulomatosis with an uncommon manifestation: clinicopathological features and review of literature. *Respir Care.* 2013, Dec 10. Respcare 02842 (ahead of print)
- [3] Chowdhury FU, Sheerin F, Bradley KM, Gleeson FV. Sarcoid-like reaction to malignancy on whole-body integrated (18) F-FDG PET/CT. *Prevalance and disease pattern.* 2009;64(7):675-81.

PARTICULARS OF CONTRIBUTORS:

1. Faculty, Department of Geriatric Medicine, University of Regensburg, Regensburg, Germany.
2. Faculty, Department of Geriatric Medicine, University of Regensburg, Regensburg, Germany.
3. Faculty, Department of Internal Medicine II, Saarland University Medical Center, Homburg, Saar, Germany & Luxembourg Centre for Systems Biomedicine (LCSB), University of Luxembourg, Luxembourg.

NAME, ADDRESS, E-MAIL ID OF THE CORRESPONDING AUTHOR:

Dr (Prof). Jochen G. Schneider,
Luxembourg Centre for Systems Biomedicine (LCSB), Campus Belval,
7 Ave. des Hauts Fourneaux, L-4362 Esch, Luxembourg.
Email: jg.schneider@outlook.com

FINANCIAL OR OTHER COMPETING INTERESTS: None.

Date of Submission: **Feb 04, 2015**

Date of Peer Review: **May 22, 2015**

Date of Acceptance: **May 28, 2015**

Date of Publishing: **Jul 01, 2015**