

# Unicystic Ameloblastoma of Mandible Treated with an Innovative Approach: A Clinical Case Report

NARENDRA BABU<sup>1</sup>, NSC CHARLES<sup>2</sup>, RAJ RAI<sup>3</sup>, SMITA MATHUR<sup>4</sup>, SAMEER HEMANT RUNWAL<sup>5</sup>

## ABSTRACT

Ameloblastoma is a true benign neoplasm with its origin from remnants of odontogenic epithelium. Unicystic ameloblastoma presents as a cystic lesion which clinically, radiographically, and macroscopically mimics a mandibular cyst, but microscopically exhibits ameloblastic epithelium lining part of the cyst cavity, with or without intraluminal growth and tumour infiltration into the fibrous connective tissue wall. An important and perplexing aspect associated with ameloblastoma is its management. We hereby present a case of unicystic ameloblastoma in a 63-year-old female and report an innovative technique of treating the case with split iliac crest graft.

**Keywords:** Iliac crest graft, Neoplasm, Odontogenic, Resection

## CASE REPORT

A 63-year-old female reported to the Outpatient Department of CMDC, Jaipur, Rajasthan, India, with the chief complaint of an asymptomatic swelling in respect to the left posterior mandibular region. The swelling gradually increased in size in the past 6 months to attain the present size of concern. Patient was diabetic, hypertensive and severely anaemic. Extra-oral examination revealed a solitary oval shaped swelling with indistinct margins on the left side of the mandible, measuring approximately 3 × 5 cm [Table/Fig-1].

On palpation, the swelling was non-tender, non-compressible and bony hard. There were no neurosensory deficit. Intraorally, the swelling was bony hard and extended from the alveolar process to gingivo-buccal fold and antero-posteriorly from premolar area to retromolar area with an intact overlying mucosa. The teeth of the affected area tested vital. Orthopantomogram revealed a well-defined unilocular radiolucent lesion involving the body of left side of mandible [Table/Fig-2].

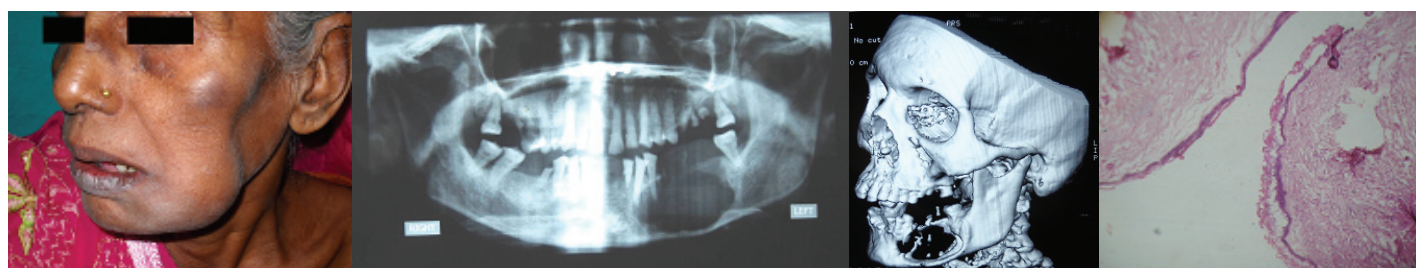Computed tomography revealed the bucco-lingual expansion of the tumour [Table/Fig-3].

Based on the clinical and radiographic features, a provisional diagnosis was given as benign odontogenic tumour probably

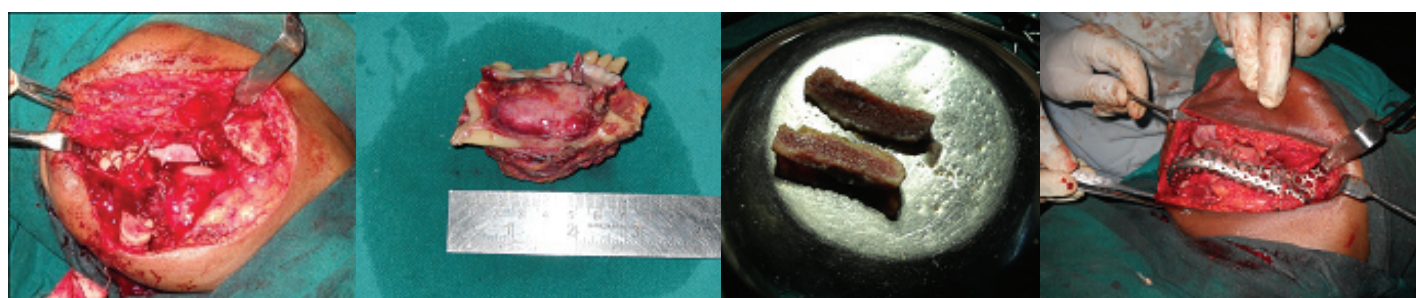
ameloblastoma. Keratocystic odontogenic tumour was included as the differential diagnosis for the lesion. An incisional biopsy was performed; the histopathological examination of the specimen revealed unicystic ameloblastoma [Table/Fig-4].

After obtaining informed consent from the patient, the case was planned for surgical resection of tumour followed by immediate reconstruction. A thorough pre-surgical work-up was planned. Reconstruction of the mandibular defect was planned with an iliac crest autograft followed by further reinforcement and stabilization using Dumbach mand segmental implant. As the patient was medically compromised, her general systemic condition was stabilized before surgery, her blood sugar levels and blood pressure were brought within normal range using appropriate measures, and her hemoglobin level was raised to 11.2 gm/dl preoperatively. Under general anaesthesia, mandibular resection was done [Table/Fig-5] with a safe margin of 1 cm (the actual tumour size was 9 cms) on either side [Table/Fig-6].

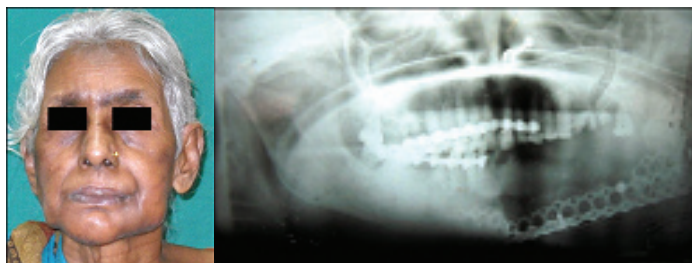Along with the resected mandible, teeth numbered 32, 33, 34 and 38 were also removed during the surgery [Table/Fig-6]. Following resection, there was a defect measuring approximately 11 cm considering the age of the patient age, the size of the defect and



[Table/Fig-1]: Preoperative extra-oral photograph showing the extent of the tumour [Table/Fig-2]: Orthopantomogram revealing a well-defined unilocular radiolucency [Table/Fig-3]: 3D Computed tomography reconstruction showing the defect created by the lesion [Table/Fig-4]: Photomicrograph revealing characteristic features of unicystic ameloblastoma



[Table/Fig-5]: Intraoperative picture showing the defect [Table/Fig-6]: Gross photograph of the resected specimen [Table/Fig-7]: Photograph showing sagittally split iliac crest graft [Table/Fig-8]: Intraoperative picture showing Dumbach mandibular segmental implant to support iliac crest graft



**[Table/Fig-9]:** Follow-up photograph of the patient showing restored functional and aesthetic form **[Table/Fig-10]:** Postoperative orthopantomograph

other co-morbidities, a novel and innovative modification was done on the surgical table. Approximately 5.5 cm iliac crest was harvested and was split sagittally to attain 11 cm of graft to restore the defective site [Table/Fig-7].

The graft was reinforced and stabilized using Dumbach mand segmental implant [Table/Fig-8].

The use of this technique resulted in gross restoration of the form and function of the patient. Acrylic plate prosthesis was fabricated and placed in situ to maintain the compromised occlusion. Patient was administered following medications for duration of 1 week: injection augmentin 1.2 g, 12 hourly; injection metronidazole 500 mg, 8 hourly; injection gentamicin 80 mg, 8 hourly; and injection dexamethasone 4 mg, 12 hourly. Presently, the patient is under follow-up since one year without any signs of relapse in the affected area [Table/Fig-9,10].

## DISCUSSION

Unicystic ameloblastoma is characterized by the proliferation of an ameloblastomatous epithelium which may be confined to the lining of the cystic cavity, or may exhibit an intraluminal growth or mural proliferation. It has also been described as an invasive ameloblastoma which presents as a single cystic cavity rather than multiple cystic spaces [1]. Robinson and Martinez were the first to describe this lesion as a distinct entity [2]. According to Robert and Diane, unicystic ameloblastoma may originate from reduced enamel epithelium; or as a result of transformation of dentigerous cyst into unicystic ameloblastoma; or as a result of cystic degeneration of solid/multicystic ameloblastoma [3,4]. The majority of cases (around 50%) occur in the second decade of life [5]. However, the patient in our case was 63-year-old. In majority of the cases, it presents as an asymptomatic lesion in the posterior mandible ramus region [6]. The tumour location and clinical presentation in our case was in general agreement with the existing literature. Generally, the unicystic ameloblastoma presents as unilocular image associated to a third molar severely displaced and occasionally presents a multilocular image in the premolar area [7]. The present case also presented as a unilocular radiolucency, however, there was no association with third molar, but roots of the involved teeth were displaced.

The management of ameloblastoma is still a mystery because of the fact that it is arduous to ascertain the incidence, management or recurrence rate of ameloblastoma. Moreover, each and every case of ameloblastoma exhibits a different and unique biological behaviour [7]. The present scientific literature suggests that unicystic ameloblastoma should be treated in a conservative manner as compared to solid or multicystic ameloblastomas since they exhibit a less aggressive biological behaviour. However, contrary to this belief, Gardner suggested that the three variants of unicystic ameloblastoma exhibit a different biological behaviour, with mural type behaving in a more aggressive fashion as compared to the luminal and intraluminal variants [6]. Thus, the possibility of predicting recurrence of an ameloblastoma prior to surgery would permit adjustment of the treatment plan for each case [7].

The unicystic ameloblastoma deserves special consideration on the basis of its clinical and radiologic appearance, its histopathology, and its response to treatment [8]. Numerous treatment modalities have

been employed for unicystic ameloblastoma, such as segmental or marginal resection [2]. However, conservative treatments (enucleation, curettage [9], marsupialization [10]) have also been reported in the literature. However, there is no adequate evidence to prove which treatment modality is the most effective.

In our case composite resection was done. This treatment modality was chosen considering the old age, medically compromised condition, and other co-morbidities associated with the patient. Further, segmental or composite resection produces good results, especially when carried out as a primary treatment because, once the tumour infiltrates the surrounding soft tissues, the rate of recurrence increases. This is mainly because of the difficulty in identifying the tumour boundary. Also, it has been reported that continued under-treatment of ameloblastomas can lead to unresectable recurrences [11]. Thus, sometimes a radical approach is necessary to prevent its recurrence.

However, a radical approach results in mandibular discontinuity affecting mastication, deglutition and articulation of speech. Thus, it becomes essential to restore the form and function. This can be restored with iliac bone graft which provides ample thickness of bone for very large defects for acceptance of dental implants. The iliac graft has a better uptake at the recipient site due to less dense cortical plates. Iliac graft is recommended for critical size defects not exceeding 5.5-6 cm [12]. However, in our case, critical size defect was 11 cm, but in consideration with the general health status of the patient, the vascularised graft was not a viable option. Consequently, nonvascularised iliac crest graft was harvested. Scientific literature shows that reconstruction method using only plate had a lower frequency of success than vascularized bone and non-vascularized bone transplants [13]. The use of iliac graft was made possible in our case by the use of an innovative approach, wherein, the harvested graft of 5.5 cm was split parallel with the help of osteotome to achieve graft size of approximately 11 cm. Titanium perforated reconstruction tray was used to support and stabilize the graft. The splitting of the graft not only aided in bridging the defect but also probably exposed the BMP factors, which are indirect regulators of angiogenesis and are osteoinductive in nature [14]. A study done by lino M et al., reports on 15 mandibular reconstructions using the Dumbach Titan Mesh-System and particulate cancellous bone and marrow harvested from bilateral posterior ilia, revealed an overall success rate of 87% [15]. The recipient site in our case has healed well without any postoperative complication.

## CONCLUSION

An innovative surgical reconstruction approach has been used in the present case for treatment of a relatively large mandibular defect created by unicystic ameloblastoma by using split iliac crest graft supported and reinforced by Dumbach mand segmental implant. We intend to use similar technique in our future cases also and thus, conduct a case study using this innovative approach.

## REFERENCES

- [1] Reichart PA, Phillipsen HP. Odontogenic tumours and allied lesions. Quintessence, Chicago, Ill, USA, 2004.
- [2] Robinson L, Martinez MG. Unicystic ameloblastoma: a prognostically distinct entity. *Cancer*. 1977;40:2278-85.
- [3] Marx RE, Stern D. Oral and maxillofacial pathology: a rationale for diagnosis and treatment. Chicago, Ill, USA: Quintessence Publishing Company; 2003.
- [4] Bajpai M, Agarwal D, Bhalla A, Kumar M, Garg R, Kumar M. Multilocular unicystic ameloblastoma of mandible. *Case Rep Dent*. 2013;2013:835892.
- [5] Ramesh RS, Manjunath S, Ustad TH, Pais S, Shivakumar K. Unicystic ameloblastoma of the mandible - an unusual case report and review of literature. *Head Neck Oncol*. 2010;2:1.
- [6] Gupta N, Saxena S, Rathod VC, Aggarwal P. Unicystic ameloblastoma of the mandible. *J Oral Maxillo Pathol*. 2011;15:228-31.
- [7] Bueno JM, Bueno SM, Romero JP, Atin MSB, Redecilla PH, Martin GR. Mandibular ameloblastoma. Reconstruction with iliac crest graft and implants. *Med Oral Patol Oral Cir Bucal*. 2007;12:e73-75.
- [8] Ackermann GL, Altini M, Shear M. The unicystic ameloblastoma: A clinicopathological study of 57 cases. *J Oral Pathol*. 1988;17:541-46.

- [9] Lee PK, Samman N, Ng IO. Unicystic ameloblastoma—Use of Carnoy's solution after enucleation. *Int J Oral Maxillofac Surg*. 2004;33:263-67.
- [10] Nakamura N, Higuchi Y, Tashiro H, Ohishi M. Marsupialization of cystic ameloblastoma: A clinical and histopathologic study of the growth characteristics before and after marsupialization. *J Oral Maxillofac Surg*. 1995;53:748-54.
- [11] Shatkin S, Hoffmeister FS. Ameloblastoma: A rational approach to therapy. *Oral Surg Oral Med Oral Pathol*. 1965;20:421-35.
- [12] Pogrel MA, Podlesh S, Anthony JP, Alexander J. A comparison of vascularized and non-vascularized bone grafts for reconstruction reconstruction of mandibular continuity defects. *J Oral Maxillofac Surg*. 1997;55:1200-06.
- [13] Emanuelsson J, Viblom J. Mandibular reconstruction after head and neck tumour treatment, a systematic review. Available from: <http://www.diva-portal.org/smash/get/diva2:776956/FULLTEXT01.pdf>.
- [14] Amini AR, Laurencin CT, Nukavarapu SP. Bone tissue engineering: recent advances and challenges. *Crit Rev Biomed Eng*. 2012;40:363-408.
- [15] Iino M, Fukuda M, Nagai H, Hamada Y, Yamada H, Nakaoka K, et al. Evaluation of 15 mandibular reconstructions with Dumbach Titan Mesh-System and particulate cancellous bone and marrow harvested from bilateral posterior ilia. *Oral Surg Oral Med Oral Pathol Oral Radiol*. 2009;107:e1-8.

#### PARTICULARS OF CONTRIBUTORS:

1. Specialist, Department of Oral and Maxillofacial Surgery, CMDC, Jaipur, Rajasthan, India.
2. Specialist, Department of Oral and Maxillofacial Pathology, CMDC, Jaipur, Rajasthan, India.
3. Professor and Head, Department of Oral and Maxillofacial Surgery, Dr. G.D. Pol Foundation's, Y.M.T. Dental College & Hospital, Kharghar, Navi Mumbai, Maharashtra, India.
4. Professor and Head, Department of Oral and Maxillofacial Pathology, Triveni Dental College, Bilaspur, Chhattisgarh, India.
5. Student, Bharti Vidyapeeth Deemed University Dental College and Hospital, Pune, Maharashtra, India.

#### NAME, ADDRESS, E-MAIL ID OF THE CORRESPONDING AUTHOR:

Dr. Narendra Babu,  
Specialist, Department of Oral and Maxillofacial Surgery, CMDC, Jaipur, Rajasthan, India.  
Email: babunarendra28@rediffmail.com

Date of Submission: **Mar 09, 2015**

Date of Peer Review: **Mar 29, 2015**

Date of Acceptance: **May 22, 2015**

Date of Publishing: **Jul 01, 2015**

FINANCIAL OR OTHER COMPETING INTERESTS: None.