

Complete Denture in a Microstomia Patient

ASHISH SATPATHY¹, ANIL K. GUJJARI²

ABSTRACT

Microstomia is the term used to describe a condition of reduction in the size of oral aperture which can be either acquired or congenital and affects the quality of life. Dentists occasionally come across patients with constricted oral openings. Limited oral opening makes access to the oral cavity for any dental procedure difficult. It's the duty of a dentist to provide every possible care to the patient with microstomia. This paper describes the treatment of a microstomia patient requiring complete dentures using sectional dentures. The cause of microstomia in the indexed patient was developmental in nature as all other causes of related conditions were ruled out. Finally upper and lower complete denture with sectional components were given to the patient after modification in conventional steps of its construction.

Keywords: Oral opening, Sectional dentures, Impression

CASE REPORT

A 58-year-old female edentulous patient having microstomia presented in the Department of Prosthodontics, JSS Dental College with the chief complaint of inability to chew food due to missing teeth in the month of November 2011 with the history of last extraction done six months back. The maximum mouth opening of the patient (distance between upper and lower edentulous ridge) [1] was measured to be 23mm [Table/Fig-1]. The various causes of microstomia can be Cleft lip and Palate, Scleroderma, Temporomandibular disorder, mumps, space infections, burns, postsurgical and radiation therapy [2]. The patient's medical and dental history was non-contributory. The cause of microstomia in this case seemed to be developmental in nature as all other causes were ruled out.

Sectional complete denture was planned for this patient as conventional complete denture is difficult if not impossible for the patient to wear and for the prosthodontist to fabricate. The consent for above treatment was taken from the patient before hand.

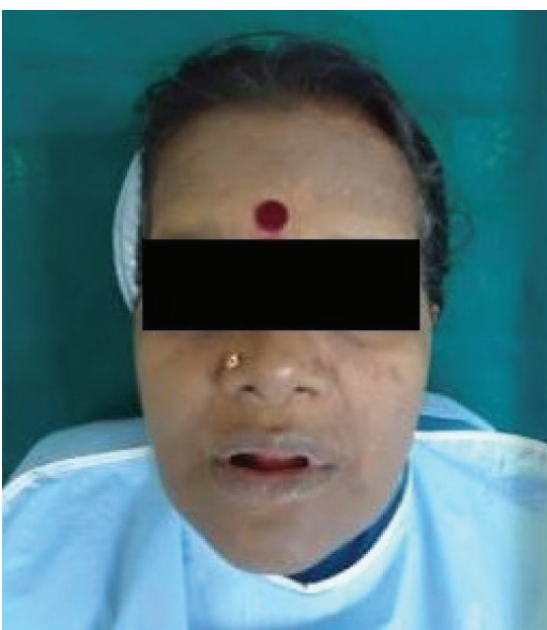Many techniques are used like hinged mandibular complete denture and sectional denture with hinge and stud attachments [3,4]. The technique described in this case report is a cheaper option as compared to other costly attachments since we used acrylic denture base to fabricate the sectional denture. The patient agreed to this treatment plan because it is a very cost effective technique.

Little modification in all phases of complete denture construction was done.

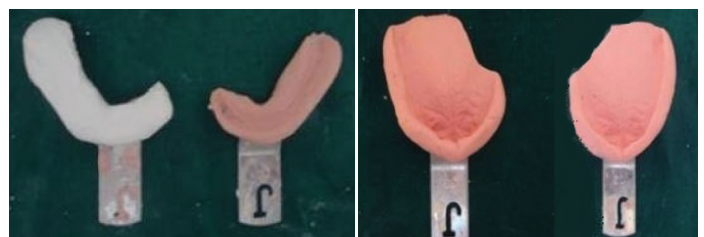
STEP- WISE PROCEDURE

Phase 1: Primary Impression [Table/Fig-2-4]

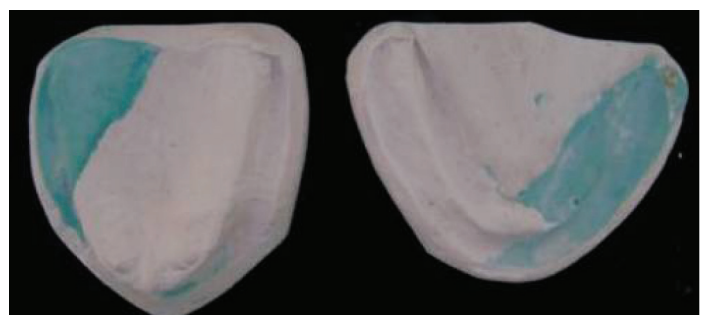
Two stock trays of similar size were cut more than half in opposite regions as shown in the [Table/Fig-2]. The first tray was used to make preliminary impression of one part of the ridge. It was then poured using dental plaster. Using the other tray, the impression of the remaining part of the ridge was made. The first retrieved cast was placed over the second impression and was secured with a rubber band.



[Table/Fig-1]: Microstomia patient with reduced mouth opening



[Table/Fig-2]: Sectional mandibular primary impression
[Table/Fig-3]: Sectional maxillary primary impression



[Table/Fig-4]: Preparation of diagnostic cast

The overlapping area of the cast and second impression works as a guide in the placement of the cast. Then the second sectional impression was also poured.

Finally a single diagnostic cast from two different sectional impressions was obtained.

Phase 2: Border Tracing and Secondary Impression

Before border moulding, a sectional custom tray was fabricated using die pins. Border tracing was done and a wash impression was made using a secondary impression paste of each half of the ridge separately.

After the wash impressions were made, the trays were assembled extra-orally using die pins and a master cast was prepared in a usual manner.

Phase 3: Fabrication of Permanent Denture Base and Preparation of the Denture Base

A usual procedure was carried out to fabricate heat cure acrylic permanent denture base. It was decided to fabricate buttoned sectional maxillary denture and cross pin, key-key way mechanism mandibular sectional denture.

The dentures bases were then modified as shown in the [Table/Fig-5,6].

Firstly, both record bases were sectioned into two halves.

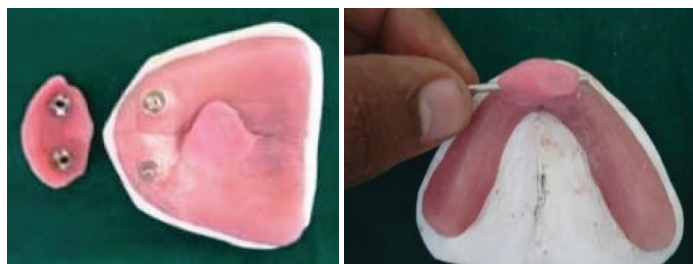
- Modification of maxillary record base:

Maxillary record base push buttons were attached to both halves and the anterior telescopic section was fabricated using auto-polymerising resin to hold the two halves together by using buttons as shown in [Table/Fig-5].

- Modification of mandibular record base:

To one half of the mandibular denture base, a denture key was attached as shown in the figure and to the other half a key way was attached which was covered with a housing. All these modification were made using autopolymerising resin as shown in the figure. Next, a hole was drilled through the key and the housing.

This assembly was reinforced by using a corresponding cross pin that conformed to the size of hole [Table/Fig-6].



[Table/Fig-5]: Fabrication of permanent denture base and preparation of the denture base (maxillary) [Table/Fig-6]: Fabrication of permanent denture base and preparation of the denture base (mandibular)

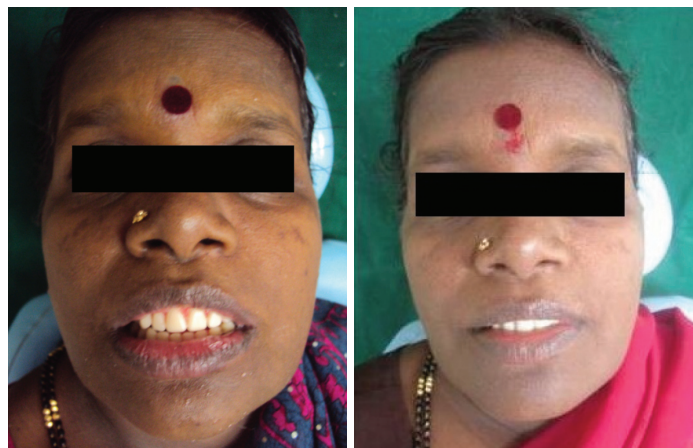Phase 4: Record Block Fabrication and Jaw Relation Recording

Record blocks were fabricated over modified record base and jaw relation record was carried out.

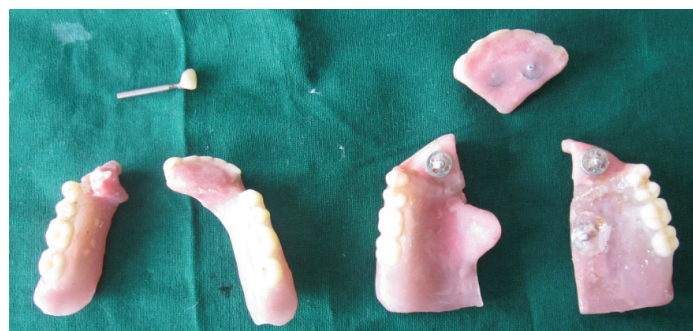The record blocks were sectional in nature. They can be inserted in parts into the patient mouth and assembled to form one complete unit.

Phase 5: Teeth Arrangement and Try in [Table/Fig-7]

Teeth arrangement was done. A canine was attached to the cross pin present at one side of the mandibular denture base. The removal of this canine and thereby the cross pin helps in disassembling the parts of the lower sectional denture.



[Table/Fig-7]:Teeth arrangement and try in
[Table/Fig-8]: Extra oral view after insertion



[Table/Fig-9]: Section wise denture ready for delivery

Phase 6: Denture Insertion and Follow Up [Table/Fig-8,9]

Finally the denture was inserted section wise, and post insertion follow up was done after one month. Section wise denture insertion is a comfortable way for such patients.

DISCUSSION

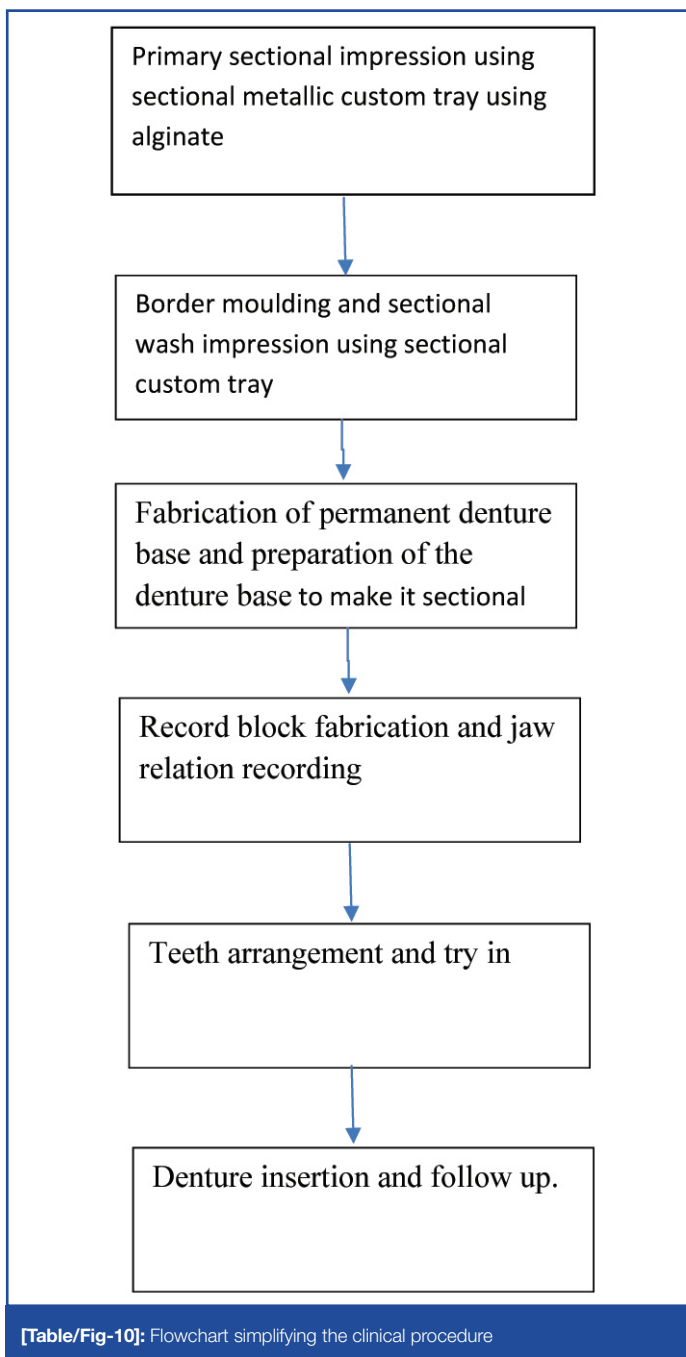
Normal mouth opening is essential for the function of speech, nutritional needs, dental hygiene, facial expression and social interaction [5]. Limited mouth opening manifests as a consequence of certain medical conditions [3]. A maximal oral opening that is smaller than the size of final prosthesis can make prosthetic treatment challenging. We need to differ prosthetic treatment procedures accordingly in these patients [6].

Ansgar Cheng et al., fabricated collapsible complete denture in a case of limited mouth opening patients. As per Ansgar Cheng et al., collapsible hinged mandibular complete denture is kept stable by tongue pressure in lateral direction and resistance provided by ridge slopes. According to authors though the procedure was found to be time consuming, the result was outstanding. So, the goal of prosthodontic treatment include: providing lip support, improving articulation, reducing drooling and regaining favourable aesthetics [3].

In a similar case a sectional denture with Hinge and stud attachments were used for working of this denture design. The advantages of the design are ease of insertion and removal, Structural durability and maximum coverage for retention, stability, and support [4].

The disadvantages of this treatment plan are restricted tongue space, increased laboratory time and requirement of patient's compliance.

Another group of authors fabricated sectional denture using Hinge and stud attachments for working of this denture design. Its advantages are custom made hinge is used which is more durable and less expensive, studs used in this method provide more rigid attachment than magnets and there is no fear of loss of magnetic effects when using studs [7].



[Table/Fig-10]: Flowchart simplifying the clinical procedure

In burns patients in particular various reconstructive and surgical techniques have been used to increase mouth opening [8,9].

This technique provides cheaper alternative to costly attachments, metal denture bases and other expensive equipments [Table/Fig-10]. The disadvantages of this type of technique are that the buttons should be regularly replaced when they lose their retention. The buttons resistance to corrosion in the patient mouth is questionable. Moreover, the autopolymerising resin used in this technique is not a long term solution due to its less strength and high monomer content.

CONCLUSION

Even though it is difficult to achieve all the aspects of prosthodontic treatment in a patient with microstomia, with improved working skills and technique we can still accomplish our goal. Other prosthodontic treatment like implants, obturators, and cast partial dentures can be done for this type of patients with slight modifications in all the procedures.

REFERENCES

- [1] Wittenaar JH, Dijkstrea PU, Vissink A, Van Oort RP, Roodenburg JLN. Variation in repeated mouth opening measurements in head and neck cancer patients with or without trismus. *Int J Oral Maxillofacial Surg.* 2009;38(1):26-30.
- [2] Prasad R, Bhide SV, Gandhi PV, Divekar NS, Madhav VNV. Prosthodontic management of a patient with limited mouth opening: a practical approach. *JIPS.* 2008;8:83-86.
- [3] Cheng AC, Wee AG, Morrison D, Maxymiw WG. Hinged mandibular removable complete denture for post-mandibulectomy patients. *J Prosthet Dent.* 1999;82(1):103-06.
- [4] Dikbas I, Koksal T, Kazazoglu E. Fabricating sectional-collapsible complete dentures for an edentulous patient with microstomia induced by scleroderma. *Quintessence Int.* 2007;38(1):15-22.
- [5] Koymen R, Gulses A, Karacayli U, Aydintug YS. Treatment of microstomia with commissuroplasties and semidynamic acrylic splints. *Oral Surg Oral Med Oral Pathol Oral Radiol Endod.* 2009;107(4):503-07.
- [6] Baker PS, Brandt RL, Boyajian G. Impression procedure for patients with severely limited mouth opening. *J Prosthet Dent.* 2000;84(2):241-44.
- [7] Cheng AC, Kwok-Seng L, Wee AG, Tee-Khin N. Prosthodontic management of edentulous patient with limited oral access using implant-supported prostheses: a clinical report. *J Prosthet Dent.* 2006;96(1):1-6.
- [8] Zweifel CJ, Guggenheim M, Jandali AR, Altintas MA, Kunzi W, Giovanoli P. Management of microstomia in adult burn patients. *Journal of Plastic, Reconstructive & Aesthetic Surgery.* 2010;63:e351-57.
- [9] Grishkevich VM. Post-burn microstomia: Anatomy and elimination with trapeze-flap plasty. *Burns.* 2011;37:484-89.

PARTICULARS OF CONTRIBUTORS:

1. Senior Lecturer, Department of Prosthodontics, Narsinhbhai Patel Dental College and Hospital, Visnagar, Gujarat, India.
2. Professor and Head, Department of Prosthodontics, JSS Dental college and hospital, Mysore, Karnataka, India.

NAME, ADDRESS, E-MAIL ID OF THE CORRESPONDING AUTHOR:

Dr. Ashish Satpathy,
Senior Lecturer, Department of Prosthodontics, Narsinhbhai Patel Dental College and Hospital,
Visnagar, Gujarat-384315, India.
E-mail: simund2@gmail.com

FINANCIAL OR OTHER COMPETING INTERESTS: None.

Date of Submission: Dec 25, 2014
Date of Peer Review: Mar 19, 2015
Date of Acceptance: Apr 01, 2015
Date of Publishing: May 01, 2015