

Neurofibroma at Unusual Locations: Report of Two Cases in Teenage Girls

CHEENA GARG¹, ARJUN AGARWAL², RANJAN AGRAWAL³, PARBODH KUMAR⁴

ABSTRACT

Solitary neurofibromas are rare occurrence in salivary gland region as well as mons pubis of females. We present two cases of teenage girls with swelling in parotid region and mons pubis. Fine needle aspiration cytology was inconclusive in both cases. They were both managed surgically and a diagnosis of neurofibroma was ascertained histopathologically and also confirmed with S-100 immunohistochemistry. The patients were followed up for a period of six months, however, no recurrence was noted. Though, one patient had a previous history of recurrence. We report these cases in view of their rarity of site and age as well as no correlation with neurofibromatosis and clitoromegaly.

Keywords: Mons pubis, Parotid gland, Solitary neurofibroma

CASE REPORT 1

A 15-year-old teenager girl presented to the surgery outpatient department with complaint of swelling over the left parotid region for 1.5 years, which was slowly progressive in nature. Further she gave a history of previous such swelling which was of four months duration and excised two years back (diagnosed as a benign nerve tumour). On examination, the current swelling was 3×2 cm in size, present below the ear lobule in the left parotid region. It was ill defined, non-tender and freely mobile with normal looking overlying skin. There was no intraoral swelling or defect in salivary secretions. There was no family history or other swellings over the body or associated signs and symptoms suggestive of neurofibromatosis or facial nerve compromise.

Fine Needle Aspiration cytology was inconclusive. The lesion was suspected clinically to be pleomorphic adenoma and superficial parotidectomy was carried out sparing the facial nerve. No radiological investigations were done.

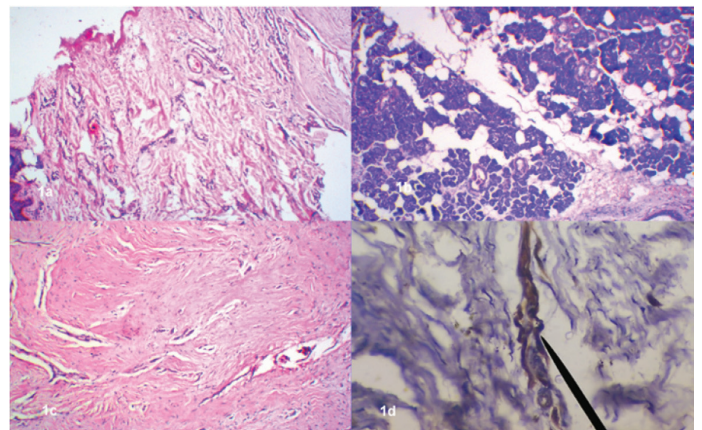
The specimen received for histopathology was irregular, greyish brown in colour and measured 5 × 4 × 2 cms. On microscopic examination, the sections showed normal serous parotid glands and acini arranged in lobules, part of skin and underlying subepithelial tissue with a subcutaneous circumscribed growth, comprising of abundant fibrous tissue and scattered nerve bundles. Immunohistochemistry for S-100 showed positivity for the nerve bundles admixed with the fibrous tissue of the tumour mass [Table/Fig-1].

Hence, a final diagnosis of neurofibroma (NF) of the parotid region was rendered.

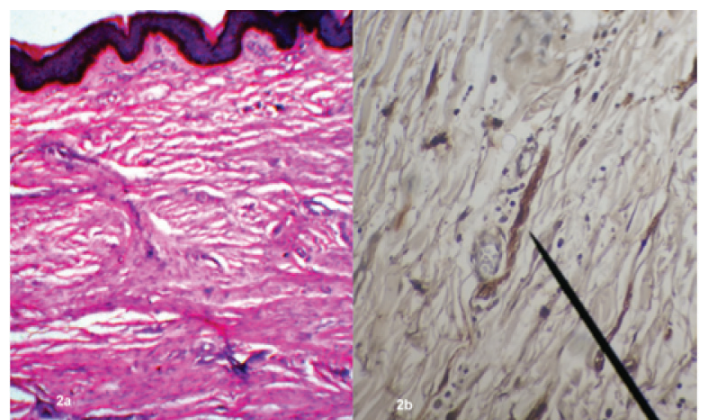
CASE REPORT 2

A 15-year-old female patient presented with a swelling over the external genitalia since one year, which was gradually progressive. On examination, the swelling was 1x1 cm in size, well defined, firm, immobile, non-tender and located over the mons pubis. The lesion was clinically suspected to be a benign cyst, in view of its location. No associated skin pigmentation, clitoromegaly, any other swellings or family history for neurofibromatosis was elicited.

FNAC was inconclusive, while radiological examination was not carried out. The lesion was excised and sent for histopathological examination. The specimen received was skin covered and greyish white in colour, measuring 1.5×1cm with a solid grey-white cut surface. Microscopic examination revealed a circumscribed un-



[Table/Fig-1]: a) Shows skin with underlying area of neurofibroma (H&E x 40), b) Shows part of normal attached parotid gland (H&E x 40), c) Shows fibrous tissue with interspersed nerve bundles (H&E x 40), d) Shows S-100 positive nerve bundle (arrow) within the neurofibroma (S-100 immunostain x 400)



[Table/Fig-2]: a) Shows skin with underlying proliferating fibrous as well as neural tissue (H&E x 40), b) Shows S-100 positive nerve bundle (arrow) running within the tumour (S-100 immunostain x 400)

encapsulated lesion beneath the epidermis, composed of randomly distributed population of spindle shaped Schwann cells and fibroblasts in the loosely textured connective tissue. The lesion entrapped few hair follicles at places.

Immunohistochemistry was positive for S-100 in the scattered Schwann cells. Thus, a final diagnosis of NF was made [Table/Fig-2].

OUTCOME AND FOLLOWUP

The postoperative recovery of both the patients was satisfactory and follow up has been uneventful since last six months.

DISCUSSION

Neurofibroma (NF) is a benign well-differentiated nerve sheath tumour. They may be solitary or multiple, sporadic or associated with neurofibromatosis I or II syndromes [1,2]. It is a slow growing tumour which is usually asymptomatic and unlike schwannoma, NF is intimately attached to the nerve of origin. NFs show autosomal dominant pattern. The systemic and hereditary factors are absent in the solitary type and the malignant transformation is extremely low [3]. The diagnostic criteria for Neurofibromatosis 1 (NF1) include family history, six or more café-au-lait macules, multiple NFs, Lisch nodules, tumour on the optic nerve and skeletal abnormalities, of which two must be present in a patient to be diagnosed as NF1. All of these features were absent in both our cases.

Radiological investigations and FNAC may not be very helpful for diagnosis. The rarity of positive cytology may be secondary to the adhesive nature of cells in such tumours [4]. Definitive diagnosis requires histopathological confirmation, which shows an unencapsulated tumour invading surrounding soft tissue structures including the nerve of origin. Microscopy reveals proliferation of all elements of nerve including axons, Schwann cells and fibroblasts. Immuno-reactivity for S-100 protein, neuron specific enolase, and vimentin is characteristic [5]. Treatment is surgical removal of the tumour.

Solitary NFs are uncommonly seen in the head and neck region [6]. Moreover, NFs arising in the salivary glands are very rare and constitute only 0.4% of all salivary neoplasms [7]. Even rarer is to find a NF arising within the parotid gland [1], where pleomorphic adenoma is considered to be the most common benign tumour with a high clinical suspicion, as was the case with our patient. Extratemporal facial nerve origin of NF is commonly expected in patients with intraparotid NF [8].

The lesion in our case was intraparotid and recurrent. It was clinically suspected to be a pleomorphic adenoma. However, the patient was confirmed to have intraparotid NF and thus a suspicion of origin from extratemporal facial nerve was high.

NFs of the vulvar and genital region of females constitute around 5% of all benign vulvar lesions [9]. Amongst the vulvar NFs majority are associated with Von Recklinghausen's disease (unlike our case) [10]. The common sites are vulva, clitoris (with clitoromegaly) and labia [11].

Neurofibromatosis as well as solitary NFs within the female genital tract is uncommon and only few reports are available in literature [12]. Detailed examination of genitourinary tract should ideally be carried out, but was not done in our case due to lack of clinical

suspicion. Solitary Vulvar NFs involving labia, clitoris and vestibule have been reported in literature, but none of them has been reported over the area of mons pubis especially, in a teenage girl [12-14].

Benign vulval tumours are less common than malignant ones, moreover, NF, lymphatic tumours, vascular aneurysm are even rarer. There was no association with neurofibromatosis or urinary tract involvement in our case and no evidence of precocious puberty or clitoral enlargement unlike, those reported in literature [10,11,15]. Fortunately, there were no areas of malignant change and the excisional biopsy was considered to be therapeutic in our case, as usually is the case. However, the patient has been kept on follow up to look for recurrence.

CONCLUSION

Solitary NFs are rare in teenager girls, especially in the parotid gland and the mons pubis. They may mimic other benign tumours or cysts and it is not always possible to suspect these cases during preoperative evaluation. Histopathology alone provides a definite diagnosis. Ruling out a possibility of neurofibromatosis in these cases is essential for patient management. More important is to follow up the patients for recurrence.

REFERENCES

- [1] Kavanaugh KT, Panje WR. Neurogenic neoplasms of the seventh clinical nerve presenting as a parotid mass. *Am J Otolaryngol*. 1982;3(1):53-56.
- [2] Sullivan MJ, Babyak JW, Kartush JM. Intraparotid facial neurofibroma. *Laryngoscope*. 1987;97: 219-23.
- [3] Boedeker CC, Ridder GJ, Kayser G, Schipper J, Maier W. Solitary neurofibroma of the maxillary sinus and pterygopalatine fossa. *Otolaryngol Head Neck Surg*. 2005;133:458-59.
- [4] Brettau P, Melchioris H, Krogdahl A. Intraparotid neurilemmoma. *Acta Otolaryngol*. 1983;95(3-4):382-84.
- [5] Moreno PM, Meseguer DH. Solitary neurofibroma of the inferior nasal turbinate. *Auris Nasus Larynx*. 1998;25:329-31.
- [6] Marocchio LS, Oliveira DT, Pereira MC, Soares CT, Fleury RN. Sporadic and multiple neurofibromas in the head and neck region: a retrospective study of 33 years. *Clin Oral Investig*. 2007;11:165-69.
- [7] Seifert G, Miehke A, Haubrich J, Chilla R. Diseases of the Salivary Glands: Pathology, Diagnosis, Treatment, Facial Nerve Surgery, Stuttgart, New York: Georg Thieme Verlag; 1986.p.171-79.
- [8] Conley J, Janecka I. Neurilemmoma of the facial nerve. *Plast Reconstr Surg*. 1973;52(1):55-60.
- [9] Gersell DJ, Fulling KH. Localized neurofibromatosis of the female genitourinary tract. *Am J Surg Pathol*. 1989;13:873-78.
- [10] Yüksel H, Odabai AR, Kafkas S, E Onur, M Turgut. Clitoromegaly in type 2 neurofibromatosis: a case report and review of the literature. *European Journal of Gynaecological Oncology*. 2003;24:447-51.
- [11] Nicholas GC, Fabian S, Arthur GW, Korgun K, Linda AB. Neurofibromatosis presenting as painless clitoromegaly. *Journal of Urology*. 2009;6:220.
- [12] Sa'adatu TS, Shehu SM, Umar HS. Neurofibroma of the labium majus: A case report, *NigJ Sur Res*. 2006;8:99-100.
- [13] Haley JC, Mirowski GW, Hood AF. Benign vulvar tumours. *Semin Cutan Med Surg*. 1998;17:196-204.
- [14] Amita M, Darshit D, Rekha W, Hemant T. Giant neurofibroma of the vulva. *Aust N Z J Obstet Gynaecol*. 2005;45:84-85.
- [15] Kidanto H, Garrison J, Wangwe P. Large neurofibroma of the labia majora: A case report. *Tanzania Journal of Health Research*. 2013;15(1):1-3.

PARTICULARS OF CONTRIBUTORS:

1. Assistant Professor, Department of Pathology, Rohilkhand Medical College and Hospital (RMCH), Bareilly, Uttar Pradesh, India.
2. Senior Resident, Department of Surgery, Rohilkhand Medical College and Hospital (RMCH), Bareilly, Uttar Pradesh, India.
3. Professor, Department of Pathology, Rohilkhand Medical College and Hospital (RMCH), Bareilly, Uttar Pradesh, India.
4. Professor, Department of Pathology, Rohilkhand Medical College and Hospital (RMCH), Bareilly, Uttar Pradesh, India.

NAME, ADDRESS, E-MAIL ID OF THE CORRESPONDING AUTHOR:

Dr. Cheena Garg,
35/C8, Rampur Garden, Bareilly, Uttar Pradesh-243001, India.
E-mail: cheena.garg@gmail.com

FINANCIAL OR OTHER COMPETING INTERESTS: None.

Date of Submission: **Nov 12, 2014**
Date of Peer Review: **Feb 03, 2015**
Date of Acceptance: **Feb 20, 2015**
Date of Publishing: **Apr 01, 2015**