

Desmoid Tumours: Our Experience of Six Cases and Review of Literature

ANJI REDDY KALLAM¹, B.V.RAMAKRISHNA², G.KISHORE ROY³, K.R.V.KARTHIK⁴

ABSTRACT

Desmoid tumours represent aggressive fibroblastic proliferation of the musculoaponeurotic structures commonly from the anterior abdominal wall. These tumours infiltrate locally, recur frequently but do not metastasize. Antecedent trauma, pregnancy and estrogens play a role in the etiopathogenesis of these tumours. In familial adenomatous polyposis (FAP) genetic history associated with chromosomal abnormality and familial incidence as in Gardner's syndrome is reported and most of these tumours are intraperitoneal either in the mesentery or pelvis and may be multiple and they carry poor prognosis. Surgery is the most preferred treatment and requires wide excision with 1 cm margin followed by reconstruction of the defect in the anterior abdominal wall either with local musculoaponeurotic layers or with synthetic mesh. In intra-abdominal cases associated with FAP in addition to surgery, hormonal treatment, chemotherapy and Radiotherapy are also advised depending upon the particular condition but usually prognosis is not encouraging.

In this article we present our personal experience in the successful treatment of six cases of sporadic desmoids, five in females of child bearing age, and all in the anterior abdominal wall and one extra abdominal in a child aged 13 y in the gluteal region (Case 6). It is very interesting and unique to see two desmoid tumours developing in the same patient (Case2)one in each of the Rectus abdominal muscles (Right & Left).

Keywords: Abdominal fibromatosis, Desmoids, Surgery

INTRODUCTION

Desmoid tumours are a rare group of locally aggressive, nonmalignant tumours of fibroblastic origin that can lead to significant morbidity due to local invasion and may even result in a fatal outcome when located around vital organs. The first description of the tumour was done by McFarlane who reported the disease occurring in the anterior abdominal wall of a young woman after delivery in 1832 [1]. However, Muller in 1838 coined the term Desmoid tumour (derived from the Greek word 'desmos' meaning tendon like [2]).

These tumours may occur at the site of any fascia particularly musculoaponeurotic junction and commonly seen in the anterior abdominal musculature. Depending on the site of occurrence they are classified as 1. Abdominal – in the anterior abdominal wall. 2. Intra-abdominal in the mesentery or pelvis, intraperitoneal or retroperitoneal, and 3. Extra- abdominal in the chest, extremities and head & neck region. While the anterior abdominal sporadic desmoids are more common in females of child bearing age, the intraabdominal tumours are frequently associated with Familial adenomatous polyposis (FAP) associated with Gardner's syndrome and extra abdominal tumours can occur in any sex and any age and are more commonly seen near the shoulder and pelvic girdle (Case 6). Many studies have shown that 37% to 50% desmoids occur in the abdominal region [3-5].

Peripheral desmoid tumours are firm, smooth, and mobile. They are often adherent to surrounding structures. The overlying skin is usually unaffected. The presence of such a soft tissue growth

should alert the clinician to look more deeply into the family history for evidence of familial polyposis coli and Gardner syndrome. Deep fibromatoses are aggressive tumours (hence, the term aggressive fibromatosis) and may cause serious clinical problems [6,7]. Intra-abdominal desmoid tumours remain asymptomatic until their growth and infiltration causes visceral compression. Symptoms of intestinal, vascular, ureteric, or neural involvement may be the initial manifestations. In this article, we present our personal experience in the successful treatment of six cases of sporadic desmoids.

MATERIALS AND METHODS

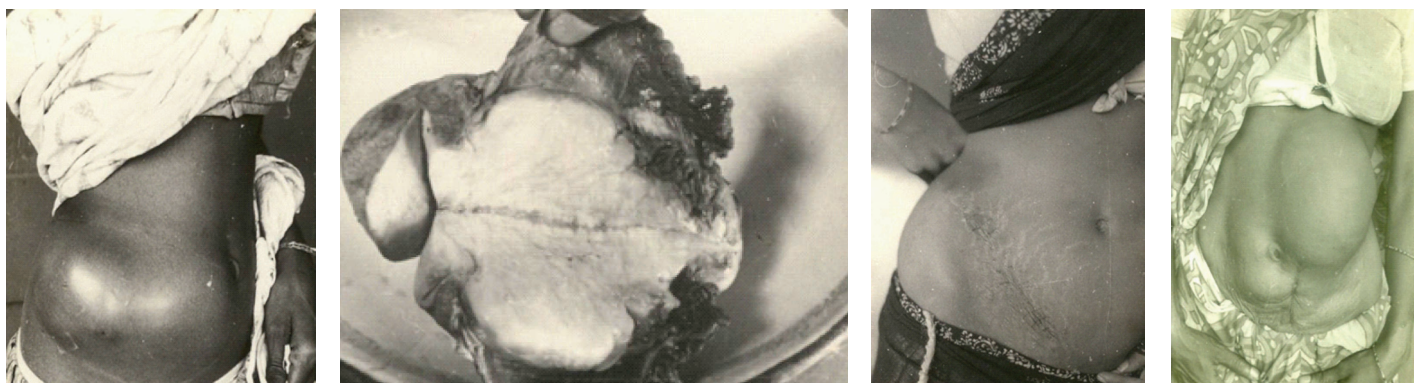
We have compiled the cases operated by us depicted in [Table/Fig -1] considering the clinical, operative and histopathological findings from 1971 to 2014 while working at Guntur medical college, Guntur (case 1 and 2) [Table/Fig 2-7], NRI Medical College, Chinakakani (cases 3, 4 and 5) [Table/Fig 8-17] and at Alluri Sita Ramaraju Academy of medical sciences, Eluru (case 6) [Table/Fig 18-20].

DISCUSSION

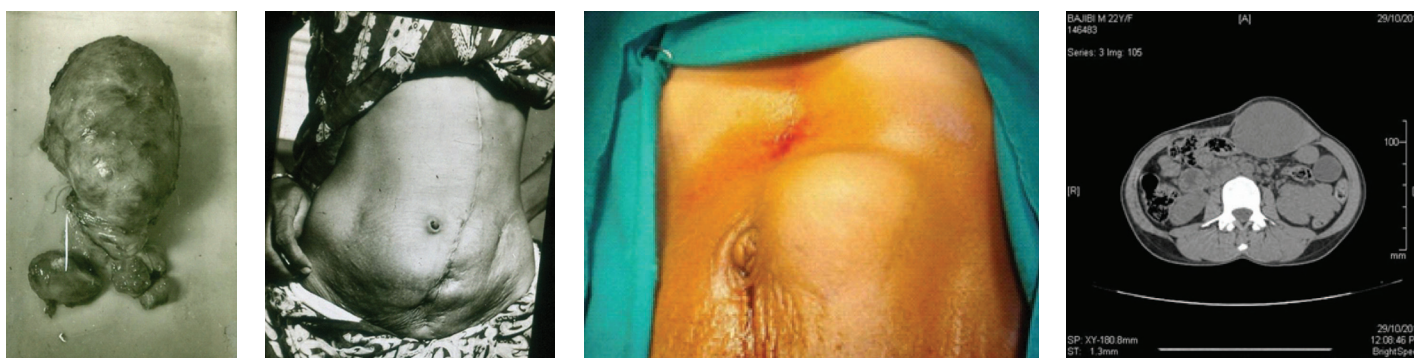Desmoid tumours account for 3% of all soft tissue neoplasms. In general population the incidence is 2.4 to 4.3 cases per million [8], but the risk increases 1000 folds in individuals with familial adenomatous polyposis (FAP) occurring as part of an inherited syndrome (Gardner's syndrome) [9]. They can occur anywhere in the body in any skeletal muscle particularly musculoaponeurotic junctions but most commonly seen in rectus abdominis muscles in women of childbearing age associated with pregnancy.

Cases	Age(yrs.)	Gender	Location	Duration	Size(cm)	Pregnancy related	Type of surgery	Recurrence
1	23	Female	Right lower abdomen	3 years	8x6	Yes	Wide excision ,mesh repair	-
2	35	Female	Anterior abdominal wall-two swellings (Right& Left)	11/2yrs & 3 months	10x7 & 3x2	Yes	Wide excision, mesh repair	-
3	22	Female	Left upper abdomen	1 year	8x5	Yes	Wide excision & repair	-
4	25	Female	Left lower abdomen	1 year	7x4	Yes	Wide excision & repair	-
5	25	Female	Left iliac fossa	6 months	10x5	Yes	-	-
6	13	Male	Right gluteal region	1 month	6x6	-	Wide excision	Yes

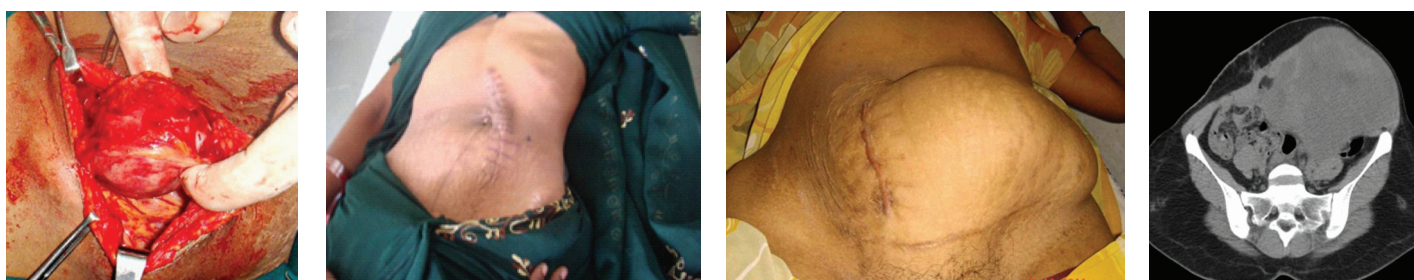[Table/Fig-1]: Summarizes our patient population



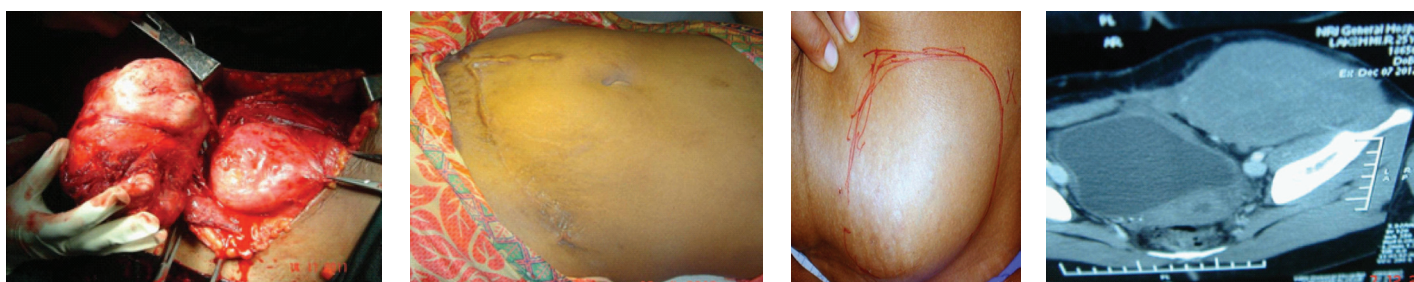[Table/Fig-2]: Case 1-Preoperative photograph **[Table/Fig-3]:** Case 1- Excised tumour and cut section **[Table/Fig-4]:** Case 1 -Postoperative photograph
[Table/Fig-5]: Case 2 -Preoperative photograph



[Table/Fig-6]: Case 2 -Excised two tumours-Gross appearances **[Table/Fig-7]:** Case 2 -Postoperative photograph **[Table/Fig-8]:** Case 3 -Preoperative photograph **[Table/Fig-9]:** Case 3 -CECT image of the tumour



[Table/Fig-10]: Case 3 -Perioperative picture showing the tumour in the rectus **[Table/Fig-11]:** Case 3 -Postoperative photograph., **[Table/Fig-12]:** Case 4- Preoperative photograph **[Table/Fig-13]:** Case 4- CECT image of the tumour

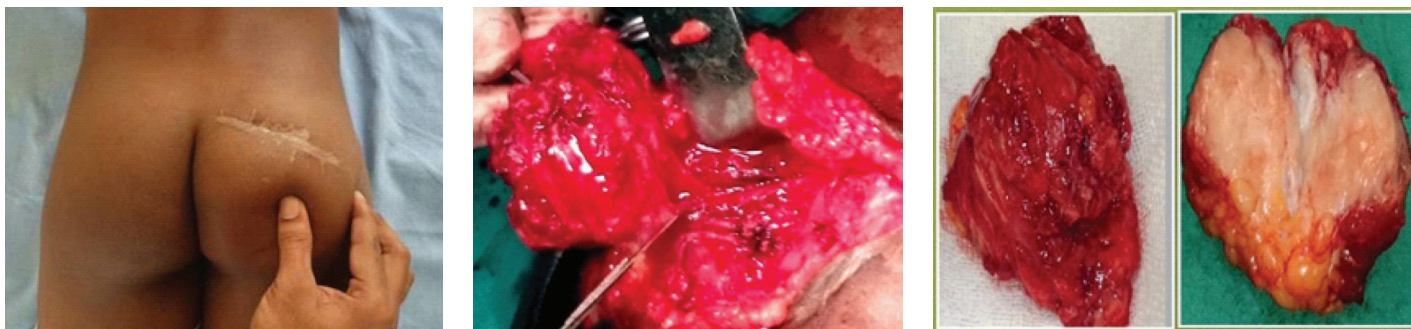

[Table/Fig-14]: Case 4 -Perioperative photograph showing the tumour and defect **[Table/Fig-15]:** Case 4-Postoperative photograph **[Table/Fig-16]:** Case 5- Preoperative photograph **[Table/Fig-17]:** Case 5- CECT image of the tumour

Desmoids arise from myofibroblasts, lacks a true capsule and usually infiltrate into the surrounding muscle [Table/Fig-3]. The telomerase length and activity is normal [10], nuclei are small and regular, and mitoses are infrequent - all of which support its histologically benign nature. Grossly, the desmoid tumours are morselized because of the incomplete excision and cutting through it had a firm gritty cut with vaguely fascicular white tan surface [Table/Fig-3]. Despite the benign histologic character, their biological behavior is more 'malignant', since the infiltrative pattern of growth can ultimately lead to life-threatening visceral involvement and even cause death [11].

Surgical trauma has been intimated in 68-86% of abdominal and intra-abdominal desmoids [5,8]. In our series, surgical intervention has been found in five patients. It has been suggested that trauma might have caused some precursor lesions that have progressed to true lesions, but results are still to be proven [5].

Role of an endocrine aetiology in the occurrence of desmoid tumour has also been suggested. These tumours occur twice as commonly among women. The commonest groups associated are young women during or after pregnancy. In our cases, among five abdominal desmoids, all are women of child bearing age group. The fibroblast has been shown to exhibit a proliferative response to



[Table/Fig-18]: Case 6- Preoperative photograph right gluteal region **[Table/Fig-19]:** Case 6-Perioperative photograph **[Table/Fig-20]:** Case 6 – Excised specimen- gross and cut section of the tumour

estrogen [12]. Additionally, desmoids regress on tamoxifen and oral estrogen therapy. Women with desmoid tumour have regression of their lesions after attaining menopause.

The prevalence of desmoid tumour in FAP is 10-25% [13-15]. Bertario et al., [8] and a recent study at Sturt et al., [16] indicated that family history is a risk factor independent of germ line APC mutation and that families do exist with 5' germ line mutations and a high proportion of members affected with desmoids.

Desmoids which are monoclonal proliferation of cells progress through well-defined precursor lesions before becoming mature tumours [5]. Desmoid precursor lesion and mesenteric fibrosis has been identified as the intermediate stage lesion before the development of the tumour. The role of beta catenin has also been implicated; the loss of APC gene allows this cytosolic protein to travel to the nuclei and increases the cellular component of cell cycle. Many authors have examined the role of beta catenin and assigned it as a marker to distinguish desmoid from other histologically similar tumour [17-19]. It has been proven that genetic deletion of receptor for hyaluronan-mediated motility (Rhamm) attenuates the formation of desmoids. Rhamm, a protein with an important role in wound healing and neoplastic progression, is also expressed at high levels in aggressive fibromatosis [20]. Genetic testing for APC gene mutation is advocated for patients with desmoid tumours and with positive family history [21]. This may help in screening of individuals who should undergo continuous surveillance of their colorectal and upper GI tract lesions.

The clinical features of desmoid tumours in our patients were consistent with those generally reported. This disease is more common among women than men, it can occur at any age, and it can arise in a variety of sites, but it most frequently occurs in the limb girdles, in contrast to our cases which are mostly abdominal. The lesion tends to be bulky at presentation. It is necessary to follow these patients for a prolonged time because occasional relapses will first become evident after five years. Desmoids can be divided into four groups, as reported in a study by Church [22]. He has described in his series that 10% of tumours resolve spontaneously, 30% undergo cycles of progression and resolution, 50% remain stable after diagnosis, and 10% progress rapidly. This natural history should be borne in mind while assessing the efficacy of therapy.

The diagnosis of desmoid tumour is based on clinical findings and suspicion. The role of imaging like ultrasound, CT or MRI is to define the degree of extension to surrounding structures.

Surgery is the mainstay of treatment for desmoid tumours of abdominal wall. Wide local resection, advocated nearly 100 y ago, and remains the treatment of choice for most patients with desmoid tumours. The excision should be completed with 1 cm margin and the resultant defect is to be repaired with local muscle flaps, distant muscle flaps or by synthetic mesh if necessary. Recurrence rates are lower if adequately excised and the morbidity rates associated with the procedure is negligible. Spear et al., [23] found a 22% recurrence rate after margin-negative resection. The major

prognostic factors were tumour location and size (>5cm), gender, and resection margins. Some studies have found a preponderance of recurrences among extremity lesions, which is seen in our case 6 [24]. The time from surgery to first recurrence has been reported to vary from 4-10. Six months with a median of 15 months. The disease-free survival at five years has been reported to be 73% and at 10 y 70%. Metastatic disease has not been reported with desmoid tumour.

Radiation therapy is effective in controlling gross desmoid tumour. Radiation may be indicated after margin positive resection or if unresectable with impending functional problems. The long-term control rate, in one series, of (76%) [25] is consistent with that in other reports [23,26].

A variety of systemic agents like tamoxifen, nonsteroidal and steroidal anti-inflammatory agents, interferon, testalactone and cytotoxic chemotherapeutic agents like doxorubicin, dacarbazine and carboplatin have been reported to produce partial or complete tumour responses when surgery is contraindicated or not feasible [9,10].

In our experience of five cases of abdominal wall desmoid tumours, all occurred in females and in childbearing age. This reflects that the role of trauma either by previous operations or physiological injury due to pregnancy along with estrogen is highly probable in the aetiology. Similar type of cases were also reported by Economou et al., [27] and Marcus et al., [28]. In all our cases surgical excision and reconstruction of the defect in the anterior abdominal wall either by local muscle flaps in two cases or synthetic mesh in two cases gave highly gratifying results, inspite of the large size of the tumours.

On gross examination, the tumours appear firm and the tumour usually extends beyond the pseudo-capsule. Microscopically, spindle-shaped cells are seen, separated by thick collagen fibers. Immunohistochemistry is positive for vimentin, smooth muscle actin and beta-catenin but negative for desmin, cytokeratin, and S-100. Molecular studies of X-chromosome inactivation have demonstrated that these tumours are a monoclonal proliferation of cells and not a reactive process as thought in the past [29].

Somatic mutations in the beta-catenin (CTNNB1) gene have been shown to occur with high frequency (98%) in sporadic desmoid tumours and it has been shown that certain CTNNB1 (45-F) mutations are at particular risk for recurrence [30]. Desmoid tumours associated with familial adenomatous polyposis (FAP) have been shown to be associated with mutations in the adenomatous polyposis coli (APC) gene [16]. Both CTNNB1 and APC are part of the Wnt signaling pathway and mutations in either gene result in stabilization of the beta-catenin protein leading to activation of the T-cell factor/lymphoid enhancer factor (TCF/Lef) family of transcription factors. This molecular biological trait may be targeted for therapies in the future [31].

CONCLUSION

Our experience in the successful management of all the five cases established that the abdominal wall desmoid tumours occur predominantly in females and in childbearing age and the role of

trauma either previous operations or physiological trauma due to pregnancy, in addition to the role of estrogen is highly probable in the aetiology. Diagnosis is easily made clinically, but the contrast enhanced CT will give the exact extent of the lesion which will help during surgery. Surgical excision if carefully done gives very good results and repair of the defect in the anterior abdominal wall can be performed either by local musculoaponeurotic tissues or by a synthetic mesh without difficulty. Since the tumour has no capsule and closely embedded in the musculoaponeurotic tissue care has to be taken for adequate excision with at least 1 cm margin to avoid local recurrence. Our case2 has established that these tumours can occur at multiple sites.

REFERENCES

- [1] MacFarlane J. Clinical reports on the surgical practice of Glasgow Royal Infirmary. *Glasgow: D. Robertson.* 1832. pp. 63-66.
- [2] Muller J. Ueber den feinem Bau und die Formen der krankhaften Geschwulste. *Berlin: G. Reimer,* 1838. p. 60.
- [3] Lewis JJ, Boland PJ, Leung DH, Woodruff JM, Brennan MF. The enigma of desmoid tumours. *Ann Surg.* 1999;229:866-72.
- [4] Bruce JM, Bradley EL 3rd, Satchidanand SK. A desmoid tumour of the pancreas. Sporadic intra-abdominal desmoids revisited. *Int J Pancreatol.* 1996;19:197-203.
- [5] Clark SK, Phillips RK. Desmoids in familial adenomatous polyposis. *Br J Surg.* 1996; 83:1494-504.
- [6] Mendez-Fernandez MA, Gard DA. The desmoid tumour: Benign neoplasm, not a benign disease. *Plast Reconstr Surg.* 1991;87:956-60.
- [7] Raynham WH, Louw JH. Desmoid tumours in familial polyposis of the colon. *S Afr J Surg.* 1971;9:133-40.
- [8] Bertario L, Russo A, Sala P, Eboli M, Giarola M, D'amico F, et al. Genotype and phenotype factors as determinants of desmoid tumours in patients with familial adenomatous polyposis. *Int J Cancer.* 2001;95:102-07.
- [9] Lopez R, Kemalyan N, Moseley HS, et al. Problems in diagnosis and management of desmoid tumours. *Am J Surg.* 1990;159:450-53.
- [10] Middleton SB, Pack K, Phillips RK. Telomere length in familial adenomatous polyposis-associated desmoids. *Dis Colon Rectum.* 2000;43:1535-39.
- [11] Lefevre JH, Parc Y, Kernis S, Goasguen N, Benis M, Parc R, et al. Risk factors for development of desmoid tumours in familial adenomatous polyposis. *Br J Surg.* 2008; 95:1136-39.
- [12] Dhingra K. Antiestrogens--tamoxifen, SERMs and beyond. *Invest New Drugs.* 1999;17:285-311.
- [13] Lofti AM, Dozois RR, Gordon H, Hruska LS, Weiland LH, Carryer PW, et al. Mesenteric fibromatosis complicating familial adenomatous polyposis: Predisposing factors and results of treatment. *Int J Colorectal Dis.* 1989;4:30-6.
- [14] Heinimann K, Mullhaupt B, Weber W, Attenhofer M, Scott RJ, Fried M, et al. Phenotypic differences in familial adenomatous polyposis based on APC germline mutation status. *Gut.* 1998;43:675-79.
- [15] Friedl W, Caspari R, Sengteller M, Uhlhaas S, Lamberti C, Jungck M, et al. Can APC mutation analysis contribute to therapeutic decisions in familial adenomatous polyposis? Experience from 680 FAP families. *Gut.* 2001;48:515-21.
- [16] Sturt NJH, Gallagher MC, Bassett P, Philp CR, Neale KF, Tomlinson IP, et al. Evidence for genetic predisposition to desmoid tumours in familial adenomatous polyposis (FAP) independent of the APC germline mutation. *Gut.* 2004;53:1832-36.
- [17] Miyoshi Y, Iwao K, Nawa G, Yoshikawa H, Ochi T, Nakamura Y. Frequent mutations in the beta-catenin gene in desmoid tumours from patients without familial adenomatous polyposis. *Oncol Res.* 1998;10:591-94.
- [18] Tejpar S, Nolle F, Li C, Wunder JS, Michils G, dal Cin P, et al. Predominance of beta-catenin mutations and beta-catenin dysregulation in sporadic aggressive fibromatosis. *Oncogene.* 1999;18:6615-20.
- [19] Montgomery E, Torbenson MS, Kaushal M, Fisher C, Abraham SC. Beta-catenin immunohistochemistry separates mesenteric fibromatosis from gastrointestinal stromal tumour and sclerosing mesenteritis. *Am J Surg Pathol.* 2002;26:1296-301.
- [20] Tolg C, Poon R, Fodde R, Turley EA, Alman BA. Genetic deletion of receptor for hyaluronan-mediated motility (Rhamm) attenuates the formation of aggressive fibromatosis (desmoid tumour). *Oncogene.* 2003;22:6873-82.
- [21] Brueckl WM, Ballhausen WG, Fortsch T, Günther K, Fiedler W, Gentner B, et al. Genetic testing for germline mutations of the APC gene in patients with apparently sporadic desmoid tumours but a family history of colorectal carcinoma. *Dis Colon Rectum.* 2005;48:1275-81.
- [22] Church JM. Desmoid tumours in patients with familial adenomatous polyposis. *Semin Colon Rectal Surg.* 1995;6:29-32.
- [23] Spear MA, Jennings LC, Mankin HJ, Spiro IJ, Springfield DS, Gebhardt MC, et al. Individualizing management of aggressive fibromatosis. *Int J Radiat Oncol Biol Phys.* 1998; 40:637-45.
- [24] Kamath SS, Parsons JT, Marcus RB, Zlotnicki RA, Scarborough MT. Radiotherapy for local control of aggressive fibromatosis. *Int J Radiat Oncol Biol Phys.* 1996;36:325-28.
- [25] Ballo MT, Zagars GK, Pollack A, Pisters PW, Pollack RA. Desmoid tumour: Prognostic factors and outcome after surgery, radiation therapy or combined surgery and radiation therapy. *J Clin Oncol.* 1999;17:158-67.
- [26] Karakousis CP, Mayordomo J, Zografos GC, Deborah L Driscoll. Desmoid tumours of the trunk and extremity. *Cancer.* 1993;72:1637-41.
- [27] Economou, et al. Desmoid tumour of the abdominal wall: a case report. *Journal of Medical Case Reports.* 2011;5:326.
- [28] Marcus Overhaus, Pan Decker, Hans Peter Fischer, Hans Jochen Textor, and Andreas Hirner. Desmoid tumours of the abdominal wall: A case report. *World J Surg Oncol.* 2003;1:11.
- [29] Li M, Cordon-Cardo C, Gerald WL, Rosai J. Desmoid fibromatosis is a clonal process. *Hum Pathol.* 1996;27:939-43.
- [30] Lazar AJ, Tuvin D, Hajibashi S, Habeeb S, Bolshakov S, Mayordomo-Aranda E, et al. Specific mutations in the beta-catenin gene (CTNNB1) correlate with local recurrence in sporadic desmoid tumours. *Am J Pathol.* 2008;173:1518-27.
- [31] Kotilgim D, Lazar AJ, Pollock RE, Lev D. Desmoid tumour: A disease opportune for molecular insights. *Histol Histopathol.* 2008;23:117-126.

PARTICULARS OF CONTRIBUTORS:

1. Director & Plastic Surgeon, Alluri Sitarama Raju Institute of Medical Sciences, Eluru, AP, India.
2. HOD, Department of Pathology, Alluri Sitarama Raju Institute of Medical Sciences, Eluru, AP, India.
3. HOD, Department of Orthopedics, Alluri Sitarama Raju Institute of Medical Sciences, Eluru, AP, India.
4. Resident, Department of Orthopedics, Alluri Sitarama Raju Institute of Medical Sciences, Eluru, AP, India.

NAME, ADDRESS, E-MAIL ID OF THE CORRESPONDING AUTHOR:

Dr. Anji Reddy kallam,
 Director & Plastic Surgeon, Alluri Sita Rama Raju academy of Medical Sciences,
 Malkapuram, Eluru, Wt. Godavari Dt, Andhra Pradesh-534005, India.
 Phone : 9652570679, E-mail : reddykanji@gmail.com

FINANCIAL OR OTHER COMPETING INTERESTS: None.

Date of Submission: **Apr 11, 2014**

Date of Peer Review: **Aug 07, 2014**

Date of Acceptance: **Sep 11, 2014**

Date of Publishing: **Oct 20, 2014**