

# Intraosseous Epidermoid Cyst Associated with Impacted Mandibular Wisdom Teeth: An Uncommon Entity

ORCUN TOPTAS<sup>1</sup>, ISMAIL AKKAS<sup>2</sup>, MUSTAFA TEK<sup>3</sup>, FATİH OZAN<sup>4</sup>, CETIN BORAN<sup>5</sup>

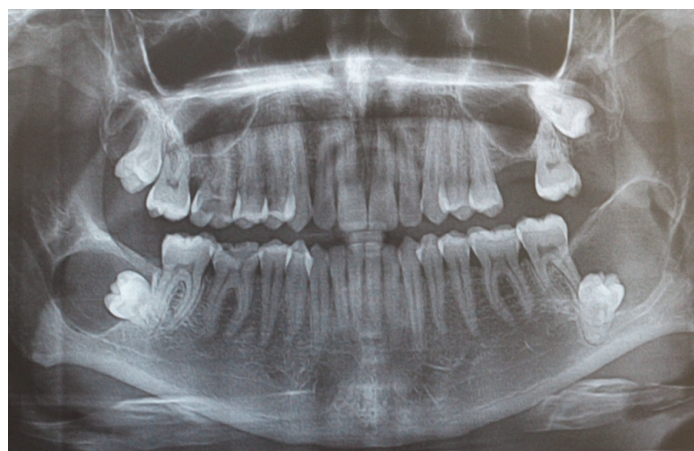## ABSTRACT

Epidermoid and dermoid cysts of the jaws are seen rarely. The formation theories of the intraosseous epidermoid cyst (IEC) are not clear. The radiographic appearance is similar with unilocular cysts. Surgical enucleation is the suggested treatment method for epidermoid cysts. This case report presents bilateral mandibular intraosseous epidermoid cysts with impacted wisdom teeth which is the first documented case in the literature.

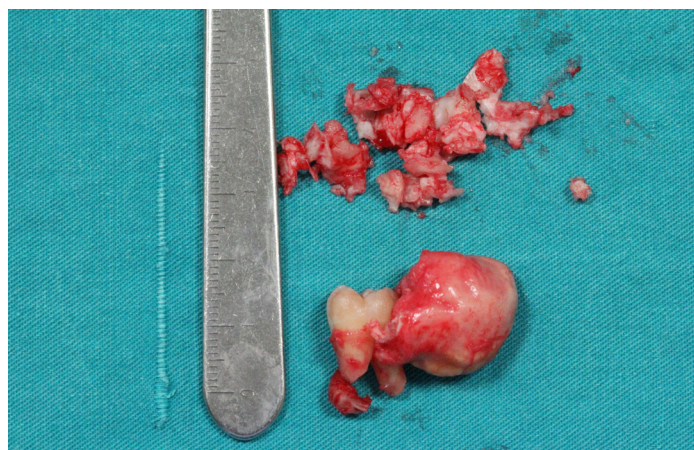
**Keywords:** Enucleation, Epidermoid cyst, Impacted wisdom teeth, Mandible

## CASE REPORT

A 24-year-old patient was referred to our clinic for treatment of impacted wisdom teeth. The patient had odontogenic pain on upper and lower right jaw. Clinical examination showed that upper and lower right first molars have deep caries and pulpitis pain. The wisdom teeth were not seen in mouth clinically. The patient anamnesis gives no wisdom teeth extraction story in past. The orthopantomograph was taken to see the positions and situations of all wisdom teeth. Bilaterally impacted teeth surrounded by large radiolucency were detected by orthopantomograph [Table/Fig-1].



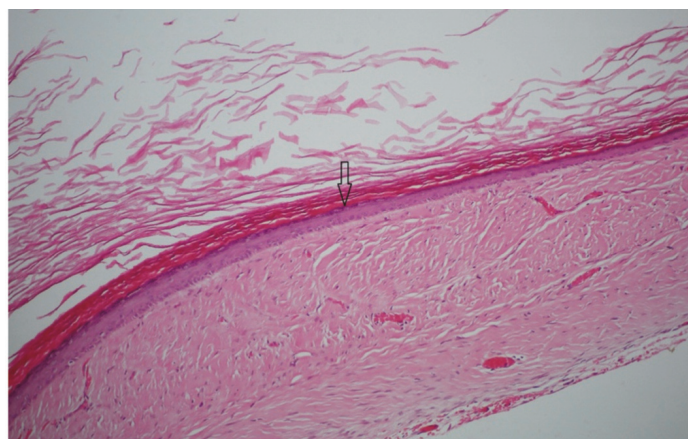
[Table/Fig-1]: Radiological view of the bilateral intraosseous epidermoid cysts



[Table/Fig-2]: Macroscopic appearance is smooth-surfaced, elastic mass associated with impacted tooth

The patient had no complaints like swelling, pain, paresthesia etc. related to the cystic lesions. The results of clinical and radiological examination was considered the odontogenic cyst especially dentigerous cyst, ameloblastoma, and keratocystic odontogenic tumour. Because of surgical accessibility of lesion and typical odontogenic cyst appearance on radiograph, the aspiration biopsy was not performed. Instead, it was decided the enucleation of the lesion directly. Surgical procedure was performed under local anesthesia. Lesions were elastic, and consisted of cheese-like masses and enucleated with associated impacted third molars. Macroscopically, the specimens were cysts with smooth surfaces [Table/Fig-2].

Histopathologically, cyst wall was showing stratified squamous epithelial lining with orthokeratotic production which is similar to epidermis. But, the lesion wall had no skin appendage that confirms the diagnosis of the lesion as IEC instead of dermoid cyst [Table/Fig-3].



[Table/Fig-3]: Histological view of epidermal cyst showing stratified squamous epithelial lining (arrow) with orthokeratotic production (H&E, X100)

## DISCUSSION

The causes of both epidermoids and dermoids include failure of surface ectoderm to separate from underlying structures, sequestration and implantation of surface ectoderm. Most congenital dermoid and epidermoid cysts probably arise due to an embryologic accident during the early stages of development, between 3 and 5 weeks of gestation. Enclosed ectodermal cysts can occur when the surface ectoderm fails to separate completely from the underlying neural tube. Alternately, they may result from abnormal sequestration or invagination of surface ectoderm along the embryologic sites of dermal fusion that form the eyes, ears, and face [1,2]. In literature

search, we couldn't find any intraosseous epidermoid cyst (IEC) located in the mandibula bilaterally and associated with impacted mandibular third molars.

Up to now numerous intraosseous epidermoid lesions were reported by many authors. Shear defined a primary intraalveolar epidermoid carcinoma [3]. In World Health Organization (WHO) classification system, primary intraosseous carcinoma term recommended in lieu primary intraalveolar carcinoma [4]. It has been considered that the malignant alterations of the odontogenic cyst epithelia is the major cause of the primary intraalveolar epidermoid carcinomas [3]. Ishida et al., showed multiple intraosseous epidermoid and trichilemmal characterised lesions in tibia as a rare manifestation of Gardner syndrome [5]. Arora et al., described a subungual IEC by sonographie [6].

The epidermal lesions especially IEC can occur anywhere at the body. The pathogenesis of IEC is not clear. Generally it has been thought that the entrapped epidermal tissues in other tissues by trauma or iatrogenic causes differentiates the IEC [6]. IEC is named as "epidermoid inclusion cyst" and located commonly in subungual region [7]. In our case IECs were placed bilaterally and both of them were associated with impacted third molars. A case that implantation type epidermoid cyst injury in the mandible due the gun shot presented in the literature [8]. In our case, the patient was a temporary military private but has no trauma or gunshot injury story.

Dermoid, epidermoid and teratoid cysts can develop in midline or sublingual region in oral cavity [9,10]. Congenital epidermoid cysts are usually originated from fuse site of embryogenic parts especially 1<sup>st</sup> and 2<sup>nd</sup> branchial archs [10]. The acquired type of the cyst generally originates from trauma, inflammation, surgery or iatrogenic causes [10,11]. The reports defines the dermoid or epidermoid cysts in the midline of the body and most frequently in the periorbital region in head and neck [12]. The production theories of IEC of the mandible are various. Embryonic ectoderm entrapment theory seems invalid for our case. Although the cysts were bilateral, there is no embryonic cleft in angulus mandible region and also the IECs had no skin appendages like hair follicles and sweat glands. The second theory suggests the Fordyce's granules which migrates from oral mucosa into bone through fistula or due the surgical operations as the origin of IECs [13]. Because of detecting no fistulas or no surgical history from patient, this theory seems also invalid for our case. Final theory explains the reason of IECs by metaplasia of the epithelium of dentigerous cysts. Sebaceous differentiation of cyst wall by induction of mesodermal organizer causes the epidermoid cysts [14]. This theory also supports the absence of skin appendages in our case. The attached impacted teeth also preoccupies that the last theory is suitable for mandibular IECs.

The researchers suggests the diagnostic work up for IEC including ultrasonography, computed tomography or magnetic resonance imaging to evaluate the adjacent anatomical structures, determine the exact location of lesion and decide the appropriate surgical approach [14]. In our case, we used only orthopantomographs and did not consider the IEC in differential diagnosis. The aspiration biopsy was not performed, either, because IEC is very rare condition and the lesions were bilaterally placed with impacted third molar teeth.

Histopathologically, cyst wall was showing stratified squamous epithelial lining with orthokeratotic production which is similar to epidermis. Histologic appearance of epidermoid cyst is similar to keratocystic odontogenic tumour. However, keratocystic odontogenic tumours have high level keratinising epithelial layer which is separated from basal cell layer, epidermoid cysts have mild keratinising epidermis. The absence of skin appendages eliminated the dermoid cyst in diagnosis.

## CONCLUSION

The lesion enucleated by intraoral approach which is suitable and suggested technique for IECs. It is important that IEC should be placed in differential diagnosis of mandibular cystic lesions in dental practice. The aspiration biopsy and further radiological investigations like ultrasonography, computed tomography or magnetic resonance imaging should be considered for cystic lesions of the jaws. Although, we have a large literature of jaw pathologies, we may still come across unique and unclear cases. Clinical examination, conventional radiographs and surgical experience is not enough for diagnosis of all pathologies. Our case is very rare and first case in the literature because of bilateral placement and being relationship with impacted third molars.

## REFERENCES

- [1] Brownstein MH, Helwig EB. Subcutaneous dermoid cysts. *Archives of Dermatology*. 1973;107(2):237-39. Epub 1973/02/01.
- [2] Pear BL. Epidermoid and dermoid sequestration cysts. *The American journal of roentgenology, radium therapy, and nuclear medicine*. 1970;110(1):148-55. Epub 1970/09/01.
- [3] Shear M. Primary intra-alveolar epidermoid carcinoma of the jaw. *The Journal of pathology*. 1969;97(4):645-51. Epub 1969/04/01.
- [4] Elzay RP. Primary intraosseous carcinoma of the jaws. Review and update of odontogenic carcinomas. *Oral surgery, Oral Medicine, and Oral Pathology*. 1982;54(3):299-303. Epub 1982/09/01.
- [5] Ishida T, Abe S, Miki Y, Imamura T. Intraosseous pilomatricoma: a possible rare skeletal manifestation of Gardner syndrome. *Skeletal Radiology*. 2007;36(7):693-98. Epub 2007/01/20.
- [6] Arora A, Srivastava D, Gupta H, Kumar V, Kotwal PP. Sonographic diagnosis of subungual intraosseous epidermoid cyst. *Journal of Clinical Ultrasound : JCU*. 2013;41 Suppl 1:35-7. Epub 2013/07/24.
- [7] Baek HJ, Lee SJ, Cho KH, Choo HJ, Lee SM, Lee YH, et al. Subungual tumours: clinicopathologic correlation with US and MR imaging findings. *Radiographics: a review publication of the Radiological Society of North America, Inc*. 2010;30(6):1621-36. Epub 2010/11/13.
- [8] Noffke CE. Implantation-type epidermoid cyst of the mandible. *Dento Maxillo Facial Radiology*. 1999;28(6):383-85. Epub. 1999/12/01.
- [9] Leveque H, Saraceno CA, Tang CK, Blanchard CL. Dermoid cysts of the floor of the mouth and lateral neck. *The Laryngoscope*. 1979;89(2 Pt 1):296-305. Epub 1979/02/01.
- [10] Makos C, Noussios G, Peios M, Gougousis S, Chouridis P. Dermoid cysts of the floor of the mouth: two case reports. *Case Reports in Medicine*. 2011;2011:362170. Epub 2011/09/17.
- [11] Kudoh M, Harada H, Omura K, Ishii Y. Epidermoid cyst arising in the submandibular region. *Case reports in medicine*. 2013;2013:419289. Epub 2013/11/06.
- [12] Bonet-Coloma C, Minguez-Martinez I, Palma-Carrio C, Ortega-Sanchez B, Penarrocha-Diago M, Minguez-Sanz JM. Orofacial dermoid cysts in pediatric patients: a review of 8 cases. *Medicina Oral, Patologia Oral Y Cirugia Bucal*. 2011;16(2):e200-3. Epub 2010/08/17.
- [13] Dror M, Allon SC, Ilana Kaplan. Intraosseous compound-type dermoid cyst of the jaw. *International Journal of Head and Neck Surgery*. 2010;1(2):103-06.
- [14] Bodner L, Woldenberg Y, Sion-Vardy N. Dermoid cyst of the maxilla. *International Journal of Oral and Maxillofacial Surgery*. 2005;34(4):453-55. Epub 2005/08/02.

### PARTICULARS OF CONTRIBUTORS:

1. Assistant Professor, Department of Oral and Maxillofacial Surgery, Abant Izzet Baysal University Bolu, Turkey.
2. Faculty, Department of Oral and Maxillofacial Surgery, Abant Izzet Baysal University Bolu, Turkey.
3. Faculty, Department of Oral and Maxillofacial Surgery, Abant Izzet Baysal University Bolu, Turkey.
4. Faculty, Department of Oral and Maxillofacial Surgery, Abant Izzet Baysal University Bolu, Turkey.
5. Faculty, Department of Pathology and Medicine, Abant Izzet Baysal University Bolu, Turkey.

### NAME, ADDRESS, E-MAIL ID OF THE CORRESPONDING AUTHOR:

Dr. Orçun Toptas,  
Assistant Professor, Department of Oral and Maxillofacial Surgery, Abant Izzet Baysal University Bolu, Turkey.  
E-mail: otopas@ibu.edu.tr

FINANCIAL OR OTHER COMPETING INTERESTS: None.

Date of Submission: Mar 26, 2014

Date of Peer Review: May 24, 2014

Date of Acceptance: Jun 16, 2014

Date of Publishing: Jul 20, 2014