

Ameloblastic Fibro-odontome (AFO) of the Mandible: A Case Report

SREENATH G.¹, INDIRA REDDY Y.², SREENIVASREDDY P.³, RAVI PRAKASH A.⁴

ABSTRACT

Odontoameloblastoma are tumours which represent a histological combination of ameloblastoma and complex odontoma. It behaves in an invasive manner like ameloblastoma and is more aggressive in nature. We report a new case of Ameloblastic Fibro-Odontoma (AFO). Clinical, radiographic and histopathological features are discussed.

Keywords: Ameloblastic fibro-odontoma, Ameloblastic fibroma, Neoplasm

CASE REPORT

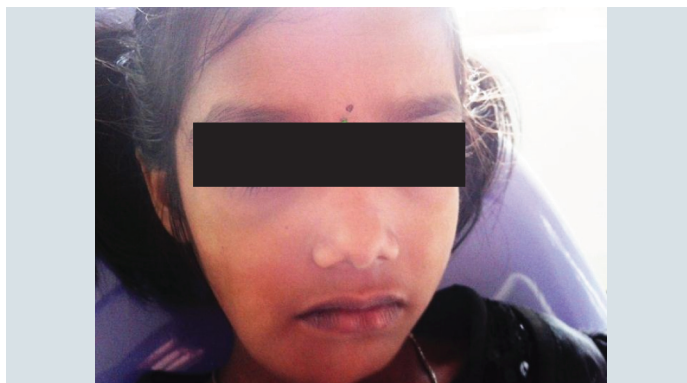A 5-year-old girl presented to our department with a chief complaint of swelling in the right mandibular region. Extraoral examination revealed facial asymmetry, with swelling present on the right side of the mandible measuring 3 × 4 cm [Table/Fig-1]. The swelling was asymptomatic and covered with healthy skin with normal colour. Intraoral examination revealed a swelling of the vestibule of mouth, extending from the deciduous canine to the deciduous second molar region, covered with normal mucosa and was hard to palpation [Table/Fig-2]. Oral inspection also revealed a full complement of deciduous teeth present along with good oral hygiene. There was no history of local trauma or infection. The OPG revealed a well-defined radiolucent lesion extending from the lower left canine to the right deciduous second molar region [Table/Fig-3]. The border of the lesion was well-circumscribed.

As the clinical features alone could not show a definitive diagnosis, incisional biopsy was performed. The histopathology revealed cellular, dental papilla-like mesenchymal tissues admixed with irregularly shaped nests of odontogenic epithelium and areas of dentin and enamel matrix. The picture was suggestive of an AFO. The lesion was surgically excised and AFO was confirmed after excision.

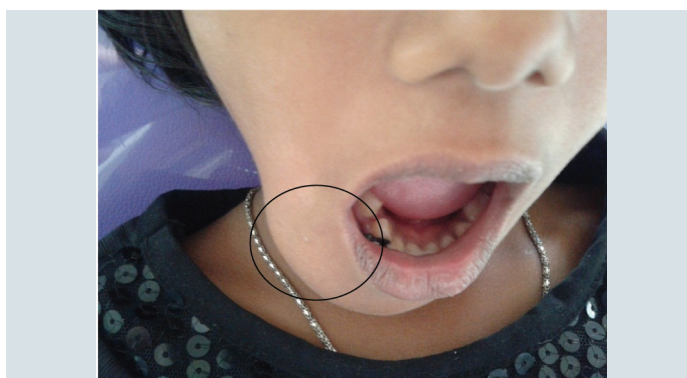DISCUSSION

AFO is defined as “a neoplasm composed of proliferating odontogenic epithelium in a cellular ectomesenchymal tissue with varying degrees of inductive changes and dental hard tissue formation” [1]. According to the World Health Organization, AFO is a tumour with histological features similar to those of ameloblastic fibroma (AF), but with inductive changes that lead to the formation of enamel or dentin [2]. Among the odontogenic tumours, the incidence of AFO varies from 0.3% to 1.7%, reaching 4.6% when only the cases in children are considered [3]. The lesions are usually diagnosed during the first and second decade of life. It occurs with equal frequency in the maxilla and the mandible, with no significant gender predilection. Radiographically it shows a well-defined, radiolucent area containing various amounts of radiopaque material of irregular size. Conservative surgical excision is the treatment of choice and the lesions do not tend to recur [4].

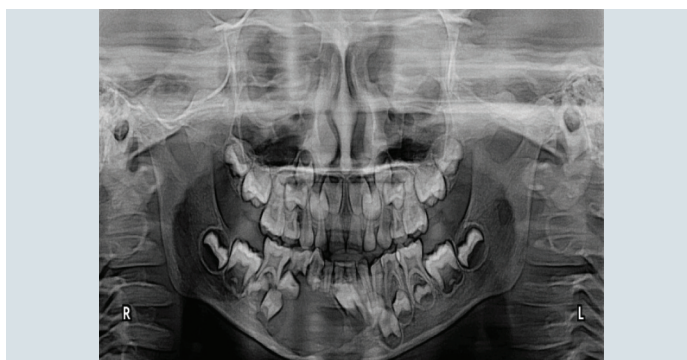The AFO is a rare, slow growing odontogenic tumour. AFO is relatively rare, with the prevalence among oral biopsies being about 1% and its frequency among odontogenic tumours being reported at 1% to 3% [5]. AFO exhibits the same benign biologic behaviour



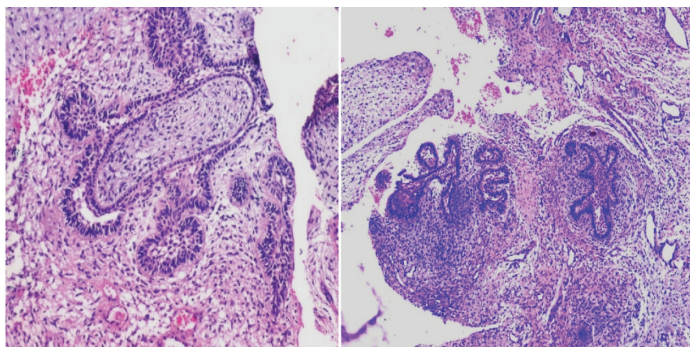
[Table/Fig-1]: Facial asymmetry is seen on the right side of the mandible



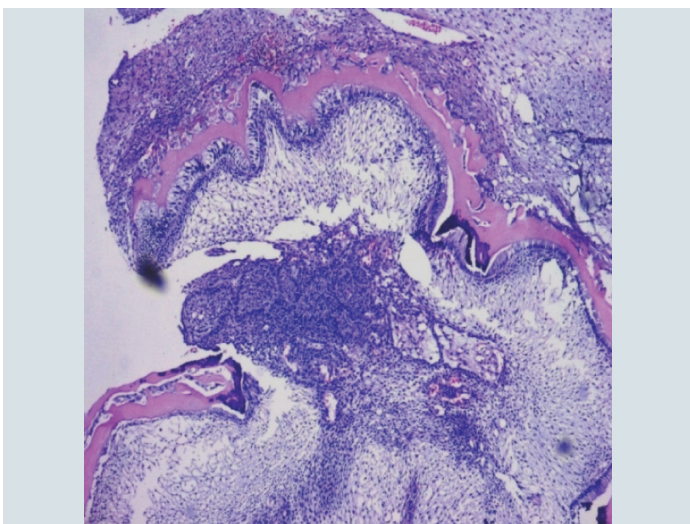
[Table/Fig-2]: Intraoral examination revealed a swelling of the vestibule of mouth, extending from the deciduous canine to the deciduous second molar region



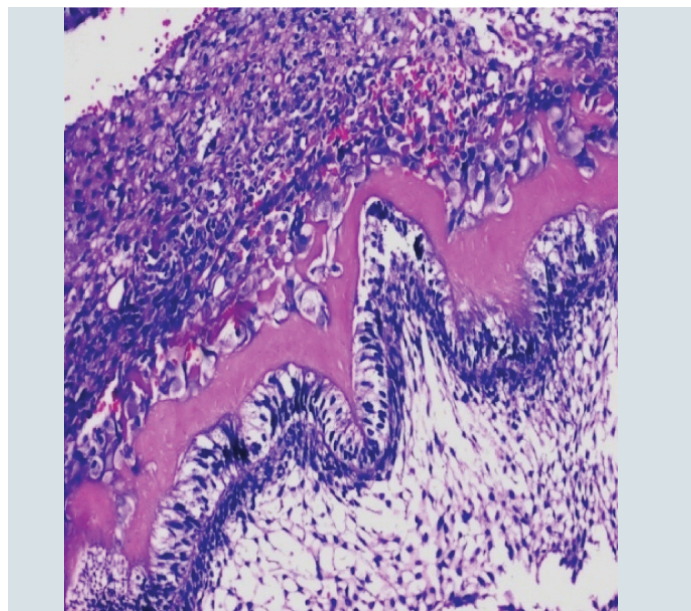
[Table/Fig-3]: OPG revealed a well-defined radiolucent lesion extending from the lower left canine to the right deciduous second molar region



[Table/Fig-4&5]: Under scanner view (4X) the H&E section shows odontogenic islands with in the ectomesenchymal tissue



[Table/Fig-6]: Under low power magnification (10X) shows induction effect of odontogenic epithelium and the formation of dental hard tissue



[Table/Fig-7]: Under high power magnification (40X) shows ameloblast like cells with dental hard tissueformation

as that of odontoameloblastoma, showing inductive changes that lead to the formation of both dentin and enamel but that is less aggressive compared to the odontoameloblastoma.

According to the revised World Health Organization (WHO) classification, AF and AFO are believed to be a stage of complex odontoma formation. However, the concept that these lesions represent a continuum of differentiation is not widely accepted, with other researchers suggesting that they are separate pathologic entities [6,7]. In some studies, the term AFO represents a histological combination of AF and complex odontoma [8].

Philpsen HP et al., raised the hypothesis that AF, Ameloblastic Fibrodentinoma (AFD) and AFO develop in two different ways. The neoplastic lineage would comprise AF and AFD, whereas AFO would be a hamartoma. But not all lesions of AFO behave as a hamartoma, some lesions show neoplastic behaviour or malignant features [9].

It is not possible to distinguish hamartoma from neoplasm based on histological features alone. A small lesion on the occlusal surface of an unerupted molar may be an immature stage of odontome, whereas, the lesion that causes swelling and cortical expansion is likely to be a true AFO [10].

Chen, et al., analysed seven cases of AFO and reported two recurrent lesions that behaved like odontomas, which were subsequently diagnosed as complex odontomas. This finding also supports the concept that AFO is an immature stage of complex odontoma in a hamartomatous structure, as previously discussed. In the same study, the possible cause of recurrence was related to lesions with tooth germs, a relatively large tumour and insufficient enucleation [11]. The recommended treatment of AFO is conservative enucleation with curettage. It has been suggested that unerupted teeth related to the lesion should be removed in order to avoid possible recurrence.

Our case presented clinical and radiographic patterns in accordance to the literature, since a radiographic examination could confirm the slow-growing character of the disease, as well as, the progressive production of calcifying material by the tumour. Histologically, AFO is composed of strands, cords and islands of odontogenic epithelium embedded in a cell-rich, primitive ectomesenchyme that resembles the dental papilla [Table/Fig-4 & 5]. Dentin and enamel matrix are also seen [Table/Fig-6]. Recently, it was determined that amelogenins participate in multi-faceted aspects of dental hard tissue formation that takes place in AFO [Table/Fig-7] [12].

Since AFO is a well-encapsulated lesion, usually not locally invasive, the recommended treatment is conservative surgical excision. Some authors have suggested that the impacted tooth associated with the lesion be preserved [13], while others have reported recurrence after preservation of impacted or retained teeth associated with the lesion [14]. In the present case, no recurrence was observed after surgical excision of the lesion that was followed up for 18 months.

CONCLUSION

AFO is a benign, rare and non recurrent tumour in a paediatric patient, which emphasizes the importance of radiographic examination of these conditions for early detection. The differential diagnosis with Odonto Ameloblastoma and AFO is essential for correct treatment and follow-up, as well as, to reduce patient morbidity.

REFERENCES

- [1] Ayham Arab Oghli, Ignazio Scuto, Christoph Ziegler, Christa Flechtenmacher, Christof Hafele. A large ameloblastic fibro-odontoma of the right mandible. *Med Oral Patol Oral Cir Bucal*. 2007; 12: E34-7.
- [2] Elen de Souza Tolentino, Bruna Stuchi Centurion, Marta Cunha Lima, Patricia Freitas-Faria, Alberto Consolaro, Eduardo Santana. Ameloblastic fibro-odontoma: A diagnostic challenge. *International Journal of Dentistry*. 2010. (Article ID104630, 4 pages.<http://dx.doi.org/10.1155/20110/104630>)
- [3] Ana-Sueli-Rodrigues Cavalcante, Ana-Lia Anbinder, Nívea-Cristina-Sena Costa, José-Roberto Sá Lima and Yasmin-Rodarte Carvalho. Ameloblastic fibro-odontoma: A case report. *Med Oral Patol Oral Cir Bucal*; 2009; 1:14 (12).
- [4] Randa Al-Fotawei, BDS, FDS RCS. Multilocular ameloblastic fibro-odontoma: A case report in the anterior maxilla. *Saudi Dental Journal*. 2009; 21(1): 51-6.
- [5] Hyunho Chang, DDS, MSD, PhD, Michael S. Shimizu, BSc, DMD, MD, MSc and David S. Precious, DDS, MSc, FRCD. Ameloblastic fibro-odontoma: A case report. *J Can Dent Assoc*. 2002; 68(4): 243-6.
- [6] PJ Slootweg. An analysis of the interrelationship of the mixed odontogenic tumours-ameloblastic fibroma, ameloblastic fibro-odontoma, and the odontomas. *Oral Surgery Oral Medicine and Oral Pathology*. 1981; 51: 266-76.
- [7] Gardner DG. The mixed odontogenic tumours. *Oral Surgery Oral Medicine and Oral Pathology*; 1984; 58: 166-68.

- [8] Chang H, Precious DS, Shimizu MS. Ameloblastic fibro-odontoma: A case report." *Journal of the Canadian Dental Association*. 2002; 68: 243-46.
- [9] Philipsen HP, Reichart PA, KH Zhang. Adenomatoid odontogenic tumour: Biologic profile based on 499 cases. *J Oral Pathol Med*. 1991; 20: 149-58.
- [10] Dolanmaz D, Pampu AA, Kalayc A, Etoz OA, Atic S. An unusual size of ameloblastic fibro-odontoma. *Dentomaxillofacial Radiology*. 2008; 37: 179-82.
- [11] Chen YK, Hwang IY, Chen JY, Wang WC, Lin LM. Adenomatoid odontogenic tumor arising from a dentigerous cyst- A case report. *Int J Pediatr Otorhinolaryngol*. 2007;2:257-63
- [12] Yagishita H, Taya Y, Kanri Y, Matsuo A, Nonaka H and Fujita H. The secretion of amelogenins is associated with the induction of enamel and dentinoid in an ameloblastic fibroodontoma. *J Oral Pathol Med*. 2001; 30: 499-503.
- [13] Reis SR, De Freitas CE and Do Espirito Santo AR. Management of ameloblastic fibro-odontoma in a 6-year-old girl preserving the associated impacted permanent tooth. *J Oral Sci*. 2007; 49:331-5.
- [14] Furst I, Pharoah M, Phillips J. Recurrence of an ameloblastic Fibro-odontoma in a 9-year-old boy. *J Oral Maxillofac Surg*. 1999; 57:620-3.

PARTICULARS OF CONTRIBUTORS:

1. Senior Lecturer, Department of Oral Pathology, G. Pullareddy Dental College, Kurnool, Andhra Pradesh, India.
2. Senior Lecturer, Department of Oral Pathology, G. Pullareddy Dental College, Kurnool, Andhra Pradesh, India.
3. Reader, Department of Oral Surgery, G. Pullareddy Dental College, Kurnool, Andhra Pradesh, India.
4. Head of the Department, Department of Oral Pathology, G. Pullareddy Dental College, Kurnool, Andhra Pradesh, India.

NAME, ADDRESS, E-MAIL ID OF THE CORRESPONDING AUTHOR:

Dr. Sreenath G.,
G. Pulla Reddy Dental College, Kurnool, Andhra Pradesh, India.
Phone: 09000476899, E-mail: dr.srinathg@yahoo.com

FINANCIAL OR OTHER COMPETING INTERESTS: None.

Date of Submission: **Dec 04, 2013**

Date of Peer Review: **May 16, 2013**

Date of Acceptance: **Nov 22, 2013**

Date of Publishing: **Jan 12, 2014**