

# An Interesting Case of Dysphagia in a HIV Patient

DEEPAK MADI, BASAVAPRABHU ACHAPPA, JOHN T. RAMAPURAM, NITHYANANDA CHOWTA, SOUNDARYA MAHALINGAM

## ABSTRACT

Oesophageal tuberculosis is a rare disease. Tuberculosis (TB) can cause dysphagia due to oesophageal ulcers, Tracheo-Oesophageal Fistulas (TOFs) and an extrinsic compression which is caused by the mediastinal lymph nodes. A 33-year-old gentleman was admitted to our hospital for the evaluation of fever, dysphagia and cough. His chest X-ray was suggestive of miliary tuberculosis. A CT scan of his chest revealed miliary tuberculosis, mediastinal lymphadenopathy and pneumomediastinum. His sputum AFB (acid-fast bacilli)

test was positive. An upper gastrointestinal endoscopy revealed a large ulcer in the oesophagus with a fistulous opening which was suggestive of a tracheo-oesophageal fistula. A biopsy from the ulcer was positive for AFB. The test for HIV-1 was positive. A nasogastric feeding tube was placed and the Anti Tubercular Therapy (ATT) was started. The main aim of this case report is to sensitize the clinicians about the fact that Tuberculosis can present with dysphagia, especially in HIV patients.

**Key Words:** HIV, Dysphagia, Tuberculosis, Oesophageal ulcer, Tracheo-oesophageal fistula

## INTRODUCTION

Oesophageal disease occurs in as many as 30% of the HIV patients at some point during the course of the infection [1]. Candida, cytomegalovirus, Herpes simplex virus and non-specific ulceration of the oesophagus can cause dysphagia in HIV patients. The ulcers which are caused by cytomegalovirus and idiopathic ulcers are the most common causes of the oesophageal ulceration in HIV patients [2]. Tuberculous involvement of the oesophagus is rare [3]. Studies have estimated that oesophageal tuberculosis constitutes about 0.3% of the gastrointestinal TB cases [4]. We are presenting an interesting case of oesophageal tuberculosis in an immunocompromised patient.

## CASE REPORT

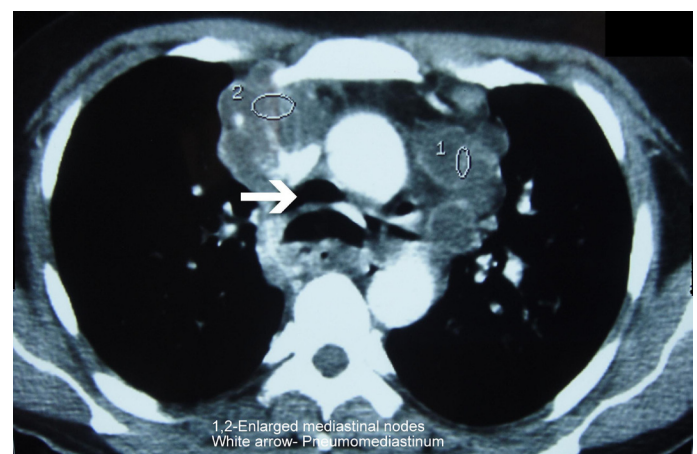
A 33-year-old male was admitted to our hospital for the evaluation of fever, dysphagia and cough. He gave a history of low grade fever of 1 month's duration. He complained of dysphagia for past 10 days. He also gave a history of cough for past 5 days. The cough was associated with a choking sensation. Choking and cough began immediately, following the ingestion of liquid or solid food. He also gave a history of breathlessness and anorexia. A history of alcohol consumption was present.

On examination, he was found to have cervical lymphadenopathy. His respiratory system examination revealed bilateral crepitations.

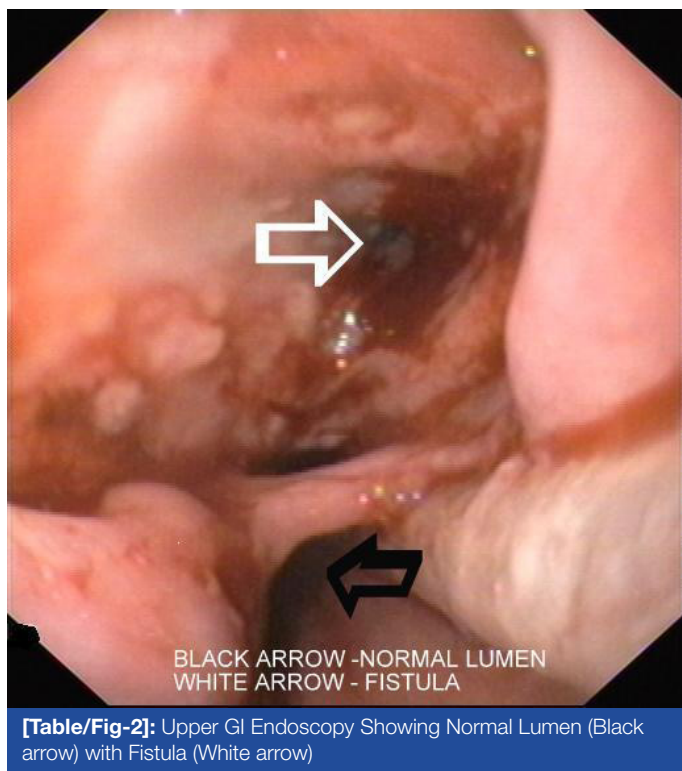
His lab investigations showed Hb -9.9 g/dl, Total White Blood Cell count -8700 cells/cu.mm, DC- N77 L-11, E-3 and M-9, platelet count-2,33,000 cells/cu.mm. ESR- 104mm/1<sup>st</sup> hour, Total.Bilirubin-1mg/dl, SGPT/SGOT(U/L)-172/83, ALP-157 U/L, total protein-7.5g/ dl, Serum Albumin-2.2g/dl and Serum Globulin-5.3g/ dl. His serum electrolytes, blood sugar and renal function were normal. The tests for HIV-1 and the Hepatitis B surface antigen were positive. His CD4+ count was 75cells/ $\mu$ l. His chest X-ray was suggestive of miliary tuberculosis. His chest X-ray also showed

an evidence of a mediastinal lymphadenopathy. Ultrasound of his abdomen showed cirrhosis of his liver. CT scan of his chest revealed miliary tuberculosis, mediastinal lymphadenopathy [Table/Fig-1] and pneumomediastinum. His sputum AFB (Acid fast bacilli) test was positive. FNAC of his cervical lymph nodes also showed AFB. An upper gastrointestinal endoscopy revealed a large ulcer in his oesophagus with a fistulous opening, which was suggestive of a Tracheo-Oesophageal Fistula (TOF) [Table/Fig-2]. Histology revealed an oesophageal mucosa with extensive ulceration and acute and chronic inflammatory cells. The staining for acid-fast bacilli was positive. A nasogastric feeding tube was placed and anti tubercular drugs were given.

ART (Zidovudine, Lamivudine and Efaviranz) was started. Trimethoprim/sulfamethoxazole prophylaxis was started. Our patient did not want a percutaneous gastrostomy. He took treatment for the first 2 months and did not come for follow up.



**[Table/Fig-1]:** CTScan of Chest showing Enlarged Mediastinal Nodes (1,2) and Pneumomediastinum(white arrow)



**[Table/Fig-2]:** Upper GI Endoscopy Showing Normal Lumen (Black arrow) with Fistula (White arrow)

## DISCUSSION

Primary involvement of the oesophagus by tuberculosis is extremely rare, and an oesophageal involvement usually results from the extension of the tuberculosis from the adjacent structures such as the mediastinal lymph nodes or the lungs or by a haematogenous spread from a distant site [5]. Our patient had secondary oesophageal tuberculosis. An oesophageal involvement by tuberculosis usually affects the middle third of the oesophagus, at the level of the carina [6]. Even our patient had an ulcer in the middle third of the oesophagus.

Oesophageal tuberculosis is almost always associated with mediastinal lymphadenopathy, with or without a tracheo-oesophageal fistula [7]. Our patient had mediastinal lymphadenopathy and a tracheo-oesophageal fistula.

The most common symptom of oesophageal tuberculosis is dysphagia [8]. Patients with an oesophago-bronchial fistula present with cough after the ingestion of food [7,9]. A tuberculous dysphagia can be due to intrinsic oesophageal ulcers, tracheo-oesophageal fistulae and the extrinsic compression which is caused by the mediastinal lymph nodes. In 14 patients with dysphagia which was caused by TB, the aetiology was mediastinal and subcarinal lymphadenopathy in seven, it was tracheo-oesophageal fistulas in four, it was oesophageal ulcers in two, and it was cervical node suppuration in one [10]. The dysphagia in our patient was mainly due to the large oesophageal ulcer and the tracheo-oesophageal fistula.

'Ono's sign' (uncontrolled coughing after swallowing) suggests the possibility of a tracheo-oesophageal fistula. Our patient had choking and cough after the consumption of food. Iatrogenic, malignant and traumatic causes have now superseded infection, which was formerly the predominant aetiology of acquired TOF [11,12]. Mediastinal tuberculous lymphadenitis can also cause dysphagia [13]. Tuberculous mediastinal lymphadenitis can also cause oesophageal ulceration and fistula.

An oesophageal endoscopy is the most important investigation in the evaluation of dysphagia. The endoscopic features of oesophageal tuberculosis are large oesophageal ulcers, tracheo-oesophageal fistulas, and chronic nonhealing ulcers [14]. Biopsies from the ulcer may show the classic granuloma in approximately 50% of the cases, whereas AFB are demonstrated in less than 25% of the patients [15]. A biopsy from the ulcer was positive for AFB in our patient. Bronchoscopy, with the application of methylene blue into the oesophagus, will show even a small fistula. Bronchoscopy and barium studies were not done in our patient. CT scan of the chest must be done to assess mediastinal adenopathy, an oesophageal rupture and pneumomediastinum. A spontaneous pneumomediastinum in tuberculosis has been reported in miliary as well as non-miliary tuberculosis [16].

Tuberculous tracheo-oesophageal fistulae usually require a combination of both surgical and medical treatments. Surgery consists of a simple division and closure or tracheal resection and reconstruction [10, 17]. However, there are case reports where the fistula had healed completely with medical therapy alone [7,18]. Our patient did not want surgery. He was treated with Isoniazid, Rifampicin, Pyrazinamide and Ethambutol. He completed 2 months of ATT and then did not come for follow up.

## CONCLUSION

Candida, cytomegalovirus, Herpes simplex virus and non-specific ulceration of the oesophagus commonly cause dysphagia in an HIV patient. Although it is rare, oesophageal tuberculosis must be kept in mind in the patients who present with dysphagia, especially in the countries with a high prevalence of tuberculosis and HIV.

## REFERENCES

- [1] Connolly GM, Hawkins D, Harcourt-Webster JN, Parsons PA, Husain OA, Gazzard BG. Oesophageal symptoms, their causes, treatment, and prognosis in patients with the acquired immunodeficiency syndrome. *Gut*. 1989;30:1033-39.
- [2] Wilcox CM, Schwartz DA, Clark WS. Esophageal ulceration in human immunodeficiency virus infection: Causes, response to therapy, and long-term outcome. *Ann Intern Med*. 1995;123:143-49.
- [3] Jain SK, Jain S, Jain M, Yaduvanshi A. Oesophageal tuberculosis: is it so rare? Report of 12 cases and review of the literature. *Am J Gastroenterol*. 2002;97:287-91.
- [4] Marshall JB. Tuberculosis of the gastrointestinal tract and peritoneum. *Am J Gastroenterol*. 1993;88:989-99.
- [5] Fahrny AR, Guirdi R, Farid A. Tuberculosis of the oesophagus. *Thorax*. 1969;24:254-56.
- [6] Eng J, Sabanathan S. Tuberculosis of the esophagus. *Dig Dis Sci*. 1991;36:536-40.
- [7] Devarbhavi HC, Alvares JF, Radhikadevi M. Esophageal tuberculosis associated with esophagotracheal or esophagomediastinal fistula: report of 10 cases. *Gastrointest Endosc*. 2003;57:588-92.
- [8] Mokoena T, Shama DM, Ngakane H, Bryer JV. Oesophageal tuberculosis: a review of eleven cases. *Postgrad Med J*. 1992;68: 110-15.
- [9] Dow C.J. Oesophageal tuberculosis: Four cases. *Gut*. 1981;22: 234-36.
- [10] Rathinam S, Kanagavel M, Tiruvadanan BS, Santhosam R, Chandramohan SM. Dysphagia due to tuberculosis. *Eur J Cardiothorac Surg*. 2006 ; 30 : 833 - 36 .
- [11] Reed MF, Mathisen DJ. Tracheoesophageal fistula. *Chest Surg Clin N Am*. 2003; 13: 271-89.
- [12] Couraud L, Ballester ML, Delaisement C. Acquired tracheoesophageal fistula and its management. *Semin Thorac Cardiovasc Surg*. 1998; 8: 392-99.
- [13] Ghimire MP, Walker RJ. Painful dysphagia in a case of mediastinal tuberculous lymphadenopathy. *Postgrad Med J*. 1985;61:427-28.
- [14] Abid S, Jafri W, Hamid S, Khan H, Hussaini A. Endoscopic features of esophageal tuberculosis. *Gastrointest Endosc*. 2003;57:759-62.

- [15] Seivewright N, Fechally J, Wiks ACB. Primary tuberculosis of the esophagus. *Am J Gastroenterol*. 1984;79:842-43.
- [16] Dixit R, George J. Subcutaneous emphysema in cavitary pulmonary tuberculosis without pneumothorax or pneumomediastinum. *Lung India*. 2012 ;29:70-72.
- [17] Mathisen DJ, Grillo HC, Wain JC, Hilgenberg AD. Management of acquired nonmalignant tracheoesophageal fistula. *Ann Thorac Surg*. 1991;52:759-65.
- [18] Lee JH, Shin DH, Kang KW, Park SS, Lee DH. The medical treatment of a tuberculous tracheo-esophageal fistula. *Tuber Lung Dis*. 1992;73:177-79.

**AUTHOR(S):**

1. Deepak Madi
2. Basavaprabhu Achappa
3. John T Ramapuram
4. Nithyananda Chowta
5. Soundarya Mahalingam

**PARTICULARS OF CONTRIBUTORS:**

1. Assistant Professor, Department of General Medicine, Kasturba Medical College, Mangalore (affiliated to Manipal University), India.
2. Associate Professor, Department of General Medicine, Kasturba Medical College, Mangalore (affiliated to Manipal University), India.
3. Professor and Unit Chief Department of General Medicine, Kasturba Medical College, Mangalore (affiliated to Manipal University), India.
4. Additional Professor, Department of General Medicine, Kasturba Medical College, Mangalore (affiliated to Manipal University), India.

5. Associate Professor, Department of Paediatrics, Kasturba Medical College, Mangalore (affiliated to Manipal University), India.

**NAME, ADDRESS, E-MAIL ID OF THE CORRESPONDING AUTHOR:**

Dr. Basavaprabhu Achappa,  
Associate Professor,  
Department of General Medicine,  
Kasturba Medical College,(affiliated to Manipal University)  
Attavar, Mangalore, 575001,India.  
Phone: 9980170480  
E-mail: bachu1504@gmail.com

**FINANCIAL OR OTHER COMPETING INTERESTS:**

None.

Date of Submission: **Jun 22, 2012**  
Date of Peer Review: **Aug 13, 2012**  
Date of Acceptance: **Dec 04, 2012**  
Date of Publishing: **Mar 01, 2013**