

# A Study on the Mast Cells in Appendicitis

SULOCHANA SONTI

## ABSTRACT

**Aim and objective:** To study the number and distribution of mast cells in surgically resected appendices of normal and inflamed, age and sex wise.

**Introduction:** Mast cells play an important role in various inflammatory and immune reactions. The association of changes in the number of mast cells in appendicitis is unclear. Mast cells could be one of the important cell populations responsible for nerve proliferation and hypertrophy in cases with clinically and histopathologically diagnosed appendicitis.

**Materials and Methods:** Two ninety appendicitis cases were analyzed with routine hematoxyline and eosine staining and also other special stains like toluidine blue, giemsa and leishmans stain were used. The number of mast cells present in ten

consecutive high power field was counted by randomly in all the sections with one percent toluidine blue and graded the mast cells

**Results:** Among two ninety cases, the acute appendicitis were one fifty eight cases (158), with higher mast cell count and chronic appendicitis were one hundred four cases (104), with highest mast cell count and normal appendices were twenty eight cases, did not show any significant variation in mast cell count.

**Conclusion:** We concluded that mast cell count was higher in acute appendicitis indicating immunological and non immunological injury causing acute appendicitis. The mast cell count was highest in chronic appendicitis, indicating growth interaction between mast cells, nerves and fibrosis.

**Key Words:** Appendix, Appendicitis, Mast cells, Mast cell degranulation

## INTRODUCTION

Appendicitis is the most common indication for an emergency laparotomy. The appendix was first described by the physician, anatomist, Erenario Da Capri in 1521. In 1710, Verneys coined the name "Vermiform Appendix". In 1886, Reginald Fitz coined the term 'appendicitis'. The mast cell was first described in the unstained frog's mesentery by VonRecklinghausen et al., (1863). Paul Ehrlich, in 1877, discovered the cells with basophilic granules, which when stained, appeared red or violet with the blue basic aniline dyes [1]. These cells were found to originate in the bone marrow [2]. Great numbers of mast cells were found to be present in the connective tissues of all the vertebrates, around the blood vessels, in the skin, respiratory tract, liver, spleen, bone marrow and the thymus and to some extent, in the lymphatics. The mast cells play an important role in various inflammatory and immune reactions, often linking the humoral and the cell mediated phases of the immune responses. The mast cells are the sources of heparin. The granules also contain tryptase, arylsulfatase, beta glucuronidase, the eosinophilic chemotactic factor, the neutrophilic chemotactic factor, prostaglandin -D<sub>2</sub>, the platelet activating factor and the leukotrienes, LTC and LT B<sub>4</sub>. Therefore, the mast cells are regarded as "Disseminated unicellular endocrine glands".

The association of the changes in the number of mast cells in appendicitis is unclear. The mast cells could be one of the important cell populations which are responsible for the nerve proliferation and the hypertrophy in the cases with clinically and histopathologically diagnosed appendicitis. The change in the number of mast cells in the appendix might be associated with fibrosis and

it may reflect a physiologic ageing phenomenon. The mast cell counts were found to be the lowest in normal appendices, significantly higher in acute appendicitis and the highest in chronic appendicitis. The type-1 hypersensitive reaction with a release of the mediators by the mast cells might be a triggering factor for the sequence of events which lead to appendicitis. The present study was undertaken to investigate the extent of mast cell involvement in appendicitis and to evaluate the possible role of the mast cells in appendicitis.

## MATERIALS AND METHODS

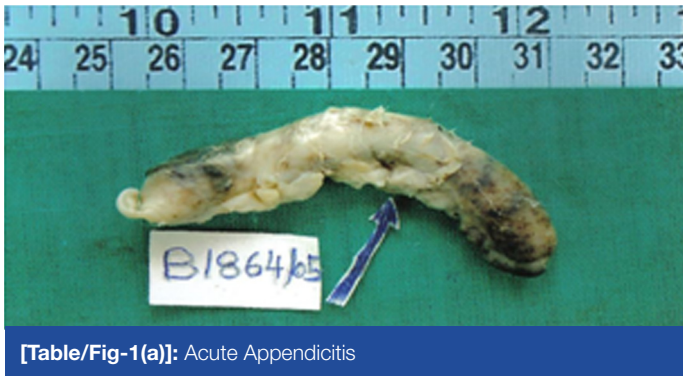The present study was done in the Department of Pathology, Kurnool Medical College, Kurnool.

Two hundred and ninety appendicitis cases were analyzed by doing the routine hematoxylin and eosin staining. The other special stains like Toluidine blue and Giemsa's and Leishman's stains were also used.

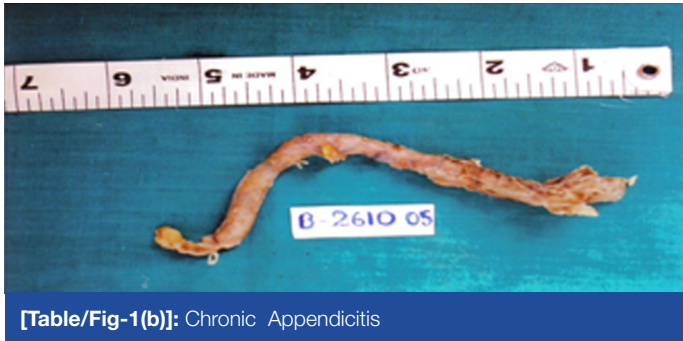## MAST CELL COUNTING

**John D Bancroft, Marilyn Gamble (2008):** 1% Toluidine blue stained sections were examined under the high power magnification [3]. The number of mast cells which were present in 10 consecutive high power fields was counted in all the sections. The total 290 cases were divided into four groups, based on the histopathological criteria.

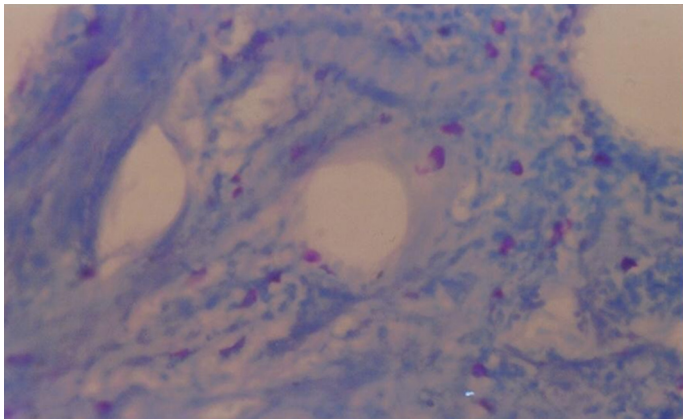
Group – A : Acute appendicitis presenting with a neutrophilic infiltration.



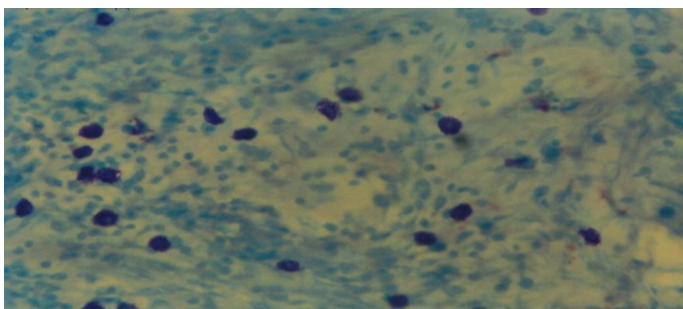
[Table/Fig-1(a)]: Acute Appendicitis



[Table/Fig-1(b)]: Chronic Appendicitis



[Table/Fig-2]: Acute Appendicitis Grade-II Mast Cells In Submucosa And Muscularis Propria – 1% Toluidine Blue –40x (18)

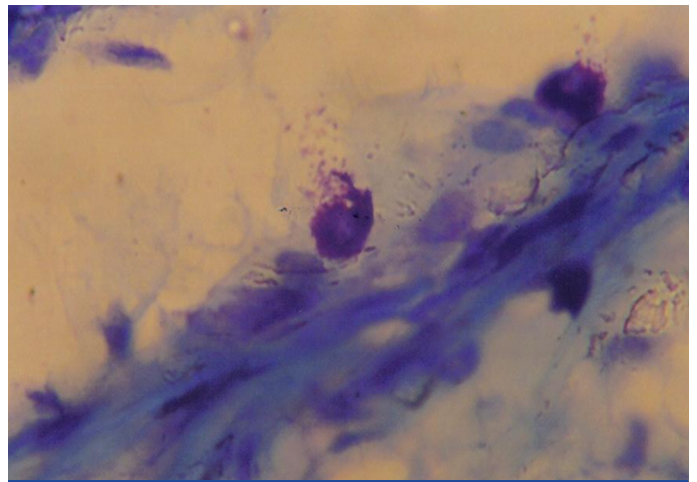


[Table/Fig-3]: Chronic Appendicitis Grade-III Mast Cells In Mucosa, Submucosa And Muscularis Propria - Giemsa Stain –40x (28)

- Group – B : Appendicitis with an eosinophilic infiltration.
- Group – C : The appendix removed incidentally during other abdominal surgeries and showing a normal picture.
- Group – D : Chronic appendicitis presenting with a lympho mono nuclear infiltrate and fibrosis.

**Grading:**

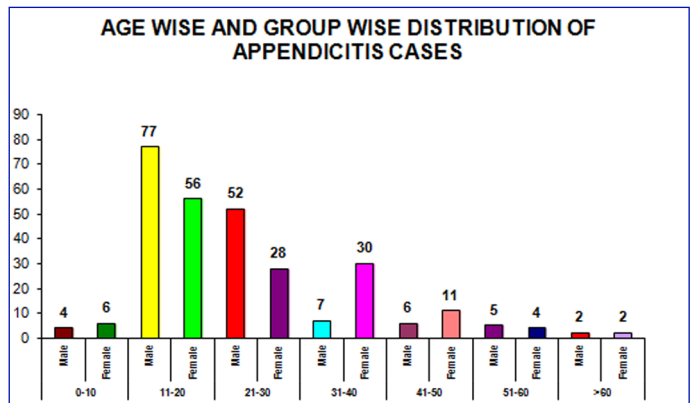
- Grade – 0 :No cells
- Grade – 1 + :Few cells seen in few high power fields.



[Table/Fig-4]: Grade- I Mast Cell Degranulation–1%Toluidine Blue-40x (18)

Diagnosis	No. of cases	Mast cell count in mucosa		Mast cell count in Sub mucosa	
		Range	Mean	Range	Mean
A. Acute appendicitis	105	5-60	30	7-40	36
B. Acute appendicitis	53	3-84	44	6-80	38
C. Normal	28	2-86	47	3-84	40
D. Chronic appendicitis	104	12-115	49	8-100	46

[Table/Fig-5]: Mast Cells / 10hpf In The Mucosal Layer And Mast Cells In Submucosa / 10hpf In The Group-A To D



[Table/Fig-6]: Age Wise And Group Wise Distribution Of Appendicitis Cases

	Group - A	Group - B	Group - C	Group -D
Dr. Nayak	29	43.14	45.4	-
Present study	30	44	47	49

[Table/Fig-7]: Mast cell count in mucosal layer

	Group - A	Group - B	Group - C	Group -D
Dr. Nayak	34.48	41.76	38.30	-
Present study	36	38	40	46

[Table/Fig-8]: Mast cell count in sub mucosa

- Grade – 2 + :Clusters of more than 10 cells seen in some fields.
- Grade – 3 + :Such clusters seen in most fields.

## RESULTS

The total number of appendices which were examined in the present study was 290 [Table/Fig-5 & 6]. The commonest lesion which was noticed was acute appendicitis in 158 cases (54.13%). The next common lesion which was noticed was chronic appendicitis in 104 cases (35.8%) and normal appendices were noticed in 28 cases (9.65%).

The mast cell count did not show a significant variation in the non inflamed appendices. Acute appendicitis was noticed in 158 cases (54.13%). In these cases, the mucosal and the sub mucosal mast cell counts were decreased. The variation of the mast cell count was proportional to the severity and the extent of the inflammation.

48 cases showed the grade- I count 20 cases showed the grade-II count There was a marked decrease in the mast cell count in the group-A lesions due to a progressive degranulation, thus making it difficult to detect the mast cells. In the group-B lesions, the mast cell count was of grades II and III. In the group-C lesions (28 cases), the mast cell count was between grades I and II.

In the group-D lesions, the maximum number of mast cells were observed to be in grade III. The mucosal mast cell count was marginally more than that which was found in the sub mucosa. [Table/Fig-7& 8]. In the present study, a variation in the grading of the mast cells was noted in acute appendicitis, thus indicating the immunological or the non-immunological injury which caused the acute appendicitis [Table/Fig-1(a) & 2].

An increased mast cell count (grade-III) in chronic sclerosing appendicitis indicated the growth interaction between the mast cells, nerves and the fibrosis [Table/Fig 1(b) & 3].

## DISCUSSION

The present study showed a significant mast cell variation in the normal and inflamed appendices. There was little variation in the average mucosal and the sub mucosal mast cells along the length of the appendix. There were not much variations in the mast cells with respect to the age and sex of the patients.

### Acute appendicitis: Groups-A and B:

In this present study, out of the 158 cases, 80 cases (20.7%) showed luminal obstruction with a faecolith. An obstruction and an infection are the important causes of acute appendicitis [4]. The obstruction which is caused by faecoliths (20.1%) causes acute appendicitis [5]. The inflammation precedes the infection in the pathogenesis of acute appendicitis [6]. In our study, mucosal ulceration was noted in 68 cases (23%). The mast cell counts were found to be reduced in the mucosal ulceration and in areas of eosinophilic infiltration [7].

Acute appendicitis is common in the age group of 10-30 years and it is average in the age around 20 years, when the lymphoid tissue is the most prominent. It has also been also noted that an immune complex injury evokes an inflammation [8,9].

### Group C

In this group, in 28 cases, the appendices were removed during other abdominal surgeries. Out of these 28 cases, in 14 cases, they were removed during hysterectomy and in 4 cases, they were removed during cholecystectomy. These cases were histologically normal and they did not show variations in the mast cell

count. There was a variation in the mast cell counts in the surgically resected appendices which were studied and reported by Naik R in 1997 [10].

### Chronic Appendicitis: Group D:

Of a total of 104 cases, 72(69%) cases showed sub mucosal fibrosis, often focal and also extending to the lamina propria, thus suggesting that the release of the growth factors led to a fibroblastic proliferation.

An increase in the mast cell clustering was seen in the vicinity of the blood vessels and also in the region of the fibrosis. In the lamina propria, approximately a threefold increase was seen. The increase in the density declines until the mucosa is obliterated by fibrous tissue and the foci of sub mucosal fibrosis did not show any significant increase in the mast cell density [11]. The initiating stimulus for fibrosis is a luminal obstruction and the mast cells are therefore activated [12].

The type -I hypersensitivity which involves mast cell degranulation and eosinophil chemotaxis, is the trigger for acute appendicitis. This very same mechanism may be repeated each time with recurrent bouts of appendicitis. The mast cells have been associated with fibrosis in various diseases and every bout of the mast cell activity may lead to a subsequent fibrosis during its resolution [9].

Butch, in 1973, stated that a resolved inflammation caused fibrosis and that it was observed in young patients who were less than 20 years of age. Partial fibrous obliteration of the lumen causes a progressive infrequency of acute appendicitis, with the age being beyond young adult hood [13]. Rajendra Bhatnagar et al., in 1979, stated about the communication between the nerves and the mast cells, that they may interact as a part of the normal homeostasis and the repair process. He also stated that the mast cell degranulation which occurred in response to a luminal antigenic stimulus was reflected as an appendicular colic. Group-D showed an evidence of mast cell degranulation [Table/Fig-4].

A variation in the mast cell distribution was noted in the normal appendix in the mucosa and the sub mucosa, but there was not much variation in the mast cells with the sex and age of the patient. Immunologic and non immunologic stimuli cause degranulation of the mast cells. There is a highest frequency of the mast cell and the nerve apposition in the appendix. The nerve growth factor causes hyperplasia of both the mucosal and the sub mucosal mast cells. Even the fibroblasts have an ability to make the nerve growth factor; hence, there is an abundant potential for growth interactions between the mast cells, nerves and the fibroblasts [12]. In the present study, a number of mast cells were noted in both chronic appendicitis and in a few normal appendices.

We concluded that the mast cell count was higher in acute appendicitis, thus indicating that an immunological or a non immunological injury caused appendicitis. The mast cell count was the highest in chronic appendicitis, thus indicating the growth interaction between the mast cells, nerves and the fibrosis.

## REFERENCES

- [1] Wikipedia -Mast cell, the free encyclopedia. 2009 Dec; 18:04.
- [2] Metcalfe DD, Baram D, Mekori YA: Mast cells. *Physiol Rev*.1997 Oct;77(4) : 1033-79.
- [3] Bancroft JD, Gamble M. Theory and Practice of the Histological techniques.6th edition. *Elsevier Limited*. 2008; 105-17.

- [4] Bowers WF. Appendicitis, with a special reference to the pathogenesis, bacteriology and the healing . *Arch. Surg.* 1939 ;9:362-70.
- [5] Myoserkar W.et al. The mast cells in surgically resected appendices. *Indian J Pathol Microbiol.* 2006 Apr;49(2):229-33.
- [6] Doraiswamy NV . The progress of acute appendicitis - A study in children. *Br J Surg.* 1978 ;65, 877-79.
- [7] Ruchard SG, Robest AC. Superficial mucosal ulceration and the pathogenesis of acute appendicitis .*Am J Surg.* 1971; 122: 378-80.
- [8] Bohrad MG. The pathogenesis of acute appendicitis. *Am J Pathol.* 1946; 16:752-60.
- [9] Aravindan KP. Eosinophils in acute appendicitis: a possible significance. *Indian J Pathol Microbiol.* 1997 Oct ;40(4) 491-98.
- [10] Naik R. Gowda RJ, Pai MR. The mast cell counts in surgically resected appendices. *J Indian Med. Assoc.* 1997 ;95(11) 571-72.
- [11] Stead, Franks. The mast cells, nerves and fibrosis in the appendix. A morphologic assessment . *J Pathol.* 1992; 161:209-19.
- [12] Naik R, Pai MR, Bansal R. The relationship between the mast cell, the nerve and the fibrosis in the appendix. *Indian J. of Pathol and Microbiol.* 1998 ;41(1): 27-30.
- [13] Cooly B. The surgical pathology of acute appendicitis. *Hum. Pathol.* 1981; 12(10) 870-78.

**AUTHOR(S):**

1. Dr. Sulochana Sonti

**PARTICULARS OF CONTRIBUTORS:**

1. Assistant Professor, Department of Pathology, Saveetha Medical College, Thandalam, Chennai, Tamilnadu, India.

**NAME, ADDRESS, E-MAIL ID OF THE CORRESPONDING AUTHOR:**

Dr. Sulochana Sonti,  
Assistant Professor, Department of Pathology,  
Saveetha medical college, thandalam, Chennai,  
Tamilnadu, India.  
Phone: 9600110836  
E-mail: sulochanamaster@gmail.com

**FINANCIAL OR OTHER COMPETING INTERESTS:**

None.

Date of Submission: **Jun 16, 2012**

Date of Peer Review: **Jul 10, 2012**

Date of Acceptance: **Aug 20, 2012**

Date of Publishing: **Sep 30, 2012**