

Delayed Presentation of a Chronic Abscess Which was Caused by a Retained Fecolith Following Appendicectomy: An Interesting Case Report and Review of the Literature

PRAVEEN KUMAR K., EREL A.I. DIAZ, RUPA M. MASCARENHAS

ABSTRACT

A chronic abscess which is caused by a retained fecolith (appendicolith) is an uncommon complication following appendicectomy. It is more common after laparoscopic appendicectomy than open appendicectomy. It's incidence has increased due

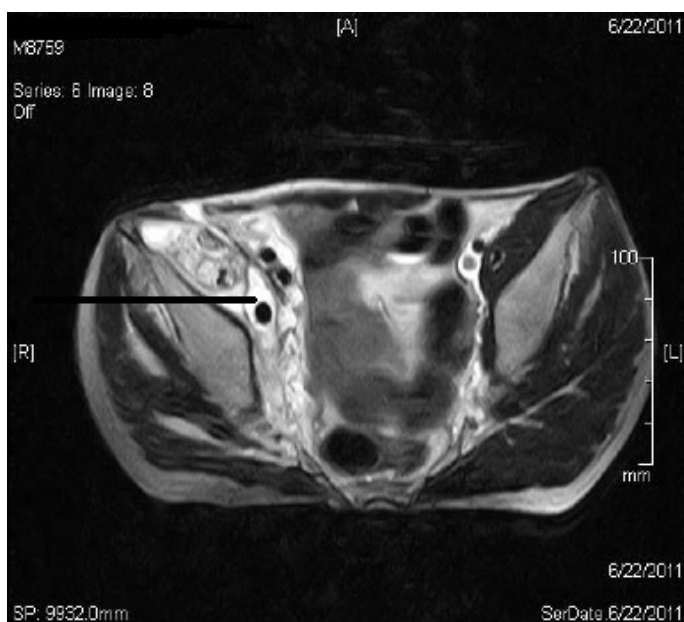
to the increased use of laparoscopic appendicectomy. We are reporting an interesting case report of a delayed presentation of a chronic abscess after 4 years following open appendicectomy, which was caused by a retained fecolith.

Key Words: Chronic abscess. Fecolith. Appendicectomy

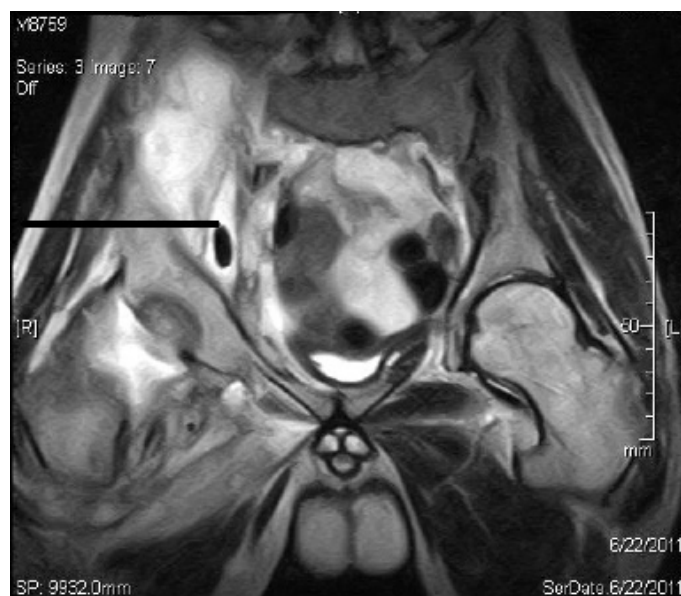
CASE SUMMARY

A 24-years old male presented with a discharging sinus in the right iliac fossa, of 8 months duration. He gave a past history of an open appendicectomy which was done 4 years back. The patient was haemodynamically stable. On examination, his abdomen was found to be soft and there was a sinus in the right iliac fossa, just below the appendicectomy scar, with a purulent discharge. There was a flexion deformity of the right hip joint and on palpation, the right iliac fossa was found to be tender. His routine blood investigations were normal, except for a raised ESR (80mm/hr). His chest X-ray and X-ray of the abdomen were normal.

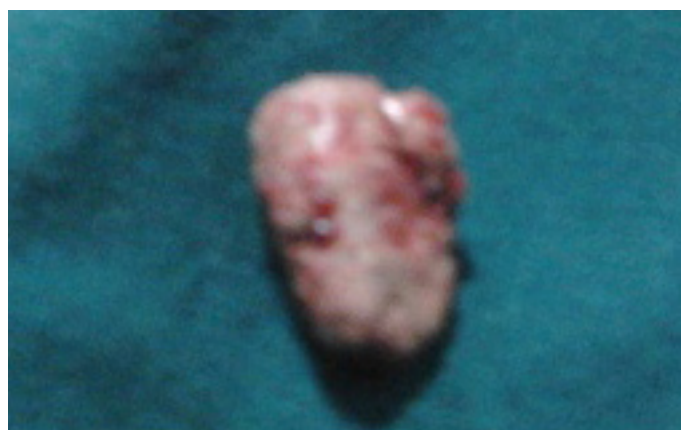MRI of the lower abdomen and hip showed a chronic abscess over the right iliacus muscle with a fecolith. The patient underwent



[Table/Fig-1]: MRI-axial film, arrow showing fecolith



[Table/Fig-2]: MRI-coronal film arrow showing fecolith



[Table/Fig-3]: Operative film showing fecolith

exploration and drainage of the abscess and removal of the fecolith. He recovered well, his wound healed well and he was discharged to go home after 3 weeks.

DISCUSSION

A chronic abscess which is caused by a retained fecolith (appendicolith) at open (i.e., conventional) appendectomy [1] or at laparoscopic appendectomy [2, 3] has rarely been reported in the surgical literature. Fecoliths are composed of inspissated faecal material, mucus with trapped calcium phosphate and inorganic salts. Fecoliths can be detected in a plain abdominal radiograph in 10 to 15% of the patients with acute appendicitis. With the recent popularity of ultrasound and CT-scan, the rate of their detection has increased [2].

A laparoscopic approach has become increasingly common in recent years, because it offers several potential advantages over the traditional open approach. Prospective studies have shown that the laparoscopic appendectomy patients have less pain, a faster recovery time after the surgery, better cosmetic results, and a somewhat lower rate of wound infection. The adoption of laparoscopic appendectomy is not yet universal [1, 4]. Some controversy continues about the appropriateness of laparoscopic appendectomy in certain situations, especially in perforated appendicitis [4].

A dropped fecolith which is associated with an abscess formation can be compared with a similar complication which is associated with gallstones which are dropped during a cholecystectomy for acute cholecystitis which is associated with an intraabdominal abscess. It is reasonable to assume that most, if not all, dropped fecoliths are also potentially infectious [2]. When laparoscopic appendectomy becomes a more common procedure; the

complications which are related to it will probably become more common also.

About 10 cases of dropped fecoliths have been reported, that caused an abscess after an open appendectomy [1, 2]. Only three cases involved laparoscopic appendectomy. Dropped fecoliths from laparoscopic appendectomies are rare, but they are potential sources of an intraabdominal abscess [3]. The time between the laparoscopic appendectomy and the presentation with the abscess ranged from 2 months to 4 years [5]. Hence, a retained fecolith should be suspected and investigated in any patient who presents with a discharging sinus in the right iliac fossa after appendectomy. The nidus of the infection – the fecolith must be removed as soon as it is identified, to prevent recurrence of the abscess [1-3, 6, 7]

REFERENCES

- [1] Mulder M. Retained fecolith as a late complication of an appendectomy. *JAMA* 1973;225:639.
- [2] Strathern DW, Jones BT. A retained fecolith after laparoscopic appendectomy. *Surg Endosc* 1999; 13:287-89.
- [3] Smith AG, Ripepi A, Stahlfeld KR. A retained fecolith: laparoscopic removal. *Surg Laparosc Endosc Percutan Tech* 2002; 12:441-42.
- [4] Hardin DM Jr. Acute appendicitis: review and update. *Am Fam Physician* 1999;60:2027-34.
- [5] Newrhee K, William PR, Maher A, Douglas SK. CT identification of the abscesses which follow dropped appendicoliths during laparoscopic appendectomy. *AJR* 2004; 182:1203-05.
- [6] Horton M, Florence MG. Unusual abscess patterns following dropped gallstones during laparoscopic cholecystectomy. *Am J Surg* 1998; 175: 375-79.
- [7] Morrin MM, Kruskal JB, Hochman MG, Saldinger PF, Kane RA. Radiologic features of the complications which arise from dropped gallstones in laparoscopic cholecystectomy patients. *AJR* 2000; 174:1441-45.

AUTHOR(S):

1. Dr. Praveen Kumar K.
2. Dr. Erel A.I. Diaz
3. Dr. Rupa M. Mascarenhas

PARTICULARS OF CONTRIBUTORS:

1. Dept of Surgery
2. Professor
3. Assistant professor

NAME OF DEPARTMENT(S)/INSTITUTION(S) TO WHICH THE WORK IS ATTRIBUTED:

Dept of Surgery,
Fr. Muller Medical College,
Kankanady, Mangalore, India - 575002

NAME, ADDRESS, E-MAIL ID OF THE CORRESPONDING AUTHOR:

Dr. Praveen Kumar K,
Dept of Surgery,
Fr. Muller Medical College,
Kankanady, Mangalore, India - 575002
Phone: 09480576235
E-mail: drpkumar@yahoo.com

FINANCIAL OR OTHER COMPETING INTERESTS:

None.

Date of Submission: **Jan 08, 2012**
Date of Peer review: **Mar 29, 2012**
Date of Acceptance: **Apr 09, 2012**
Date of Publishing: **May 31, 2012**