

JOURNAL OF CLINICAL AND DIAGNOSTIC RESEARCH

How to cite this article:

DAS PRAFULLA K, SAMANTARAY S, PATTANAYAK L, KAKKAR S. GASTRIC CARCINOID MIMICKING ADENOCARCINOMA. Journal of Clinical and Diagnostic Research [serial online] 2008 February [cited: 2008 February 4]; 2:5650658.

Available from

http://www.jcdr.net/back_issues.asp?issn=0973-709x&year=2008&month=February&volume=2&issue=2&page=656-658&id=146

CASE REPORT

Gastric Carcinoid mimicking Adenocarcinoma

DAS PRAFULLA K¹, SAMANTARAY S², PATTANAYAK L³, KAKKAR S⁴

ABSTRACT

Background - Carcinoids are rare neuro-endocrine tumors with gastric carcinoids comprising 2% of all gastro intestinal carcinoids.

Case - A 62 year old male presented with dyspepsia, loss of appetite and vomiting. On examination, a 4x3cm, irregular, slightly mobile epigastric mass was noted. Endoscopic biopsy confirmed it as Adenocarcinoma. Patient underwent subtotal radical gastrectomy. A brief review of literature was made as regards to its incidence and biological behaviour.

Conclusion - Gastric carcinoid incidence is low but not uncommon. Patients with gastric mass should be evaluated closely as the incidence of Carcinoid tumors seems to be on the rise.

Keywords - Neuro-endocrine tumors, Gastric carcinoids, Radical Gastrectomy.

Key Messages:

- Gastric carcinoids are of rare occurrence.
- High index of suspicion is paramount for the diagnosis.

1 Department of Surgical Oncology, A.H.Regional Cancer Centre, Cuttack

2 Department of Oncopathology, A.H.Regional Cancer Centre, Cuttack

3 Ex Resident, Department of Radiation Oncology, A.H.Regional Cancer Centre, Cuttack

4 Department of Radiation Oncology, Tata Memorial Hospital, Mumbai

Corresponding Author: Dr. P.K.Das, Asst. Professor, Surgical Oncology, A.H.Regional Cancer Centre, Manglabag, Cuttack - 753001, Orissa, India.
Email: das_ahrcc@rediffmail.com
Tel: 09437314901

Introduction

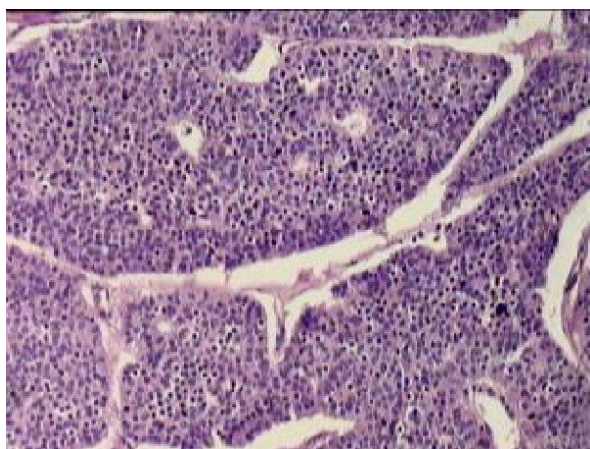
Carcinoid or Gastroenteropancreatic-Neuroectodermal tumor (GEP-NET) is a rare endocrine neoplasm derived from the diffuse neuroendocrine system. It arises from the enterochromaffin or enterochromaffin-like cells with characteristic clinical, histochemical features, dependent on their site of origin. Gastrointestinal tract, bronchus, lungs, biliary tract and ovary being the common sites of origin. Gastric carcinoids represent only 2% of the gastrointestinal carcinoids and 0.3% of the total number of gastric neoplasms[1]. Although their clinical, radiologic and pathologic features have been extensively analyzed[2], the preoperative diagnosis of gastrointestinal carcinoids remains

elusive. In gastric lesions, the rarity of occurrence, protean clinical manifestations, varied radiographic features make their recognition extremely difficult. Here we describe a case of carcinoid of the stomach in a 62 year old male in spite of its rarity.

Case Report:

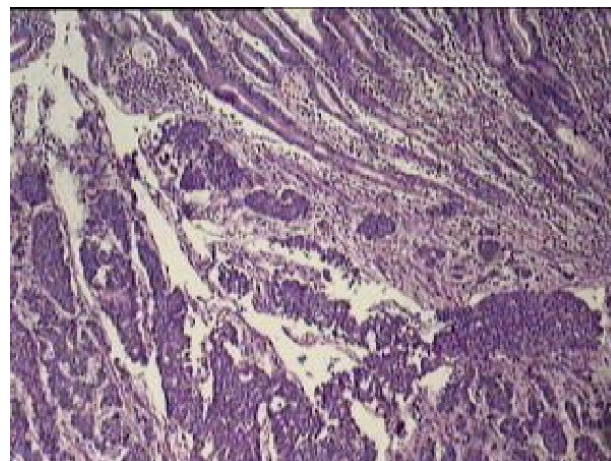
A 62 yr old gentleman presented in the Surgical Clinic with history dyspepsia, loss of appetite and occasional vomiting since 5 months. He was a habitual tobacco chewer and occasional alcoholic for the last 15 years with no significant medical history. General examination was essentially normal. On local examination, abdomen was scaphoid, umbilicus centrally located and inverted. An irregular, non-tender, 4 x 3 cm sized mass was palpable in the epigastrium, which was slightly mobile from side to side but not to the act of respiration. On knee-elbow position, the mass was confirmed to be intraperitoneal. Digital rectal examination did not reveal any palpable mass through the rectal wall in the pelvis. There was no visible peristalsis and overlying skin was healthy. Liver was palpable 2 cm below costal margin, non tender with smooth margin. There was no splenomegaly or ascites.

His routine investigations were normal. Transabdominal sonography showed a large, 4.3x3.4cm sized hypoechoic mass, arising from the stomach wall with prominent gastric folds and thickening of the wall of the body and pylorus. All the viscera were normal; no SOL was seen in the liver. On endoscopy, the esophagus and gastroesophageal junction were normal. An ulcero-proliferative mass was seen in the body of the stomach towards the lesser curvature, 7cm below the GE junction and was extending to the pylorus. The scope could be negotiated to the duodenum with difficulty. Biopsy was taken which revealed adenocarcinoma of the stomach in view of the microglandular pattern. No preoperative tumor marker study was performed as gastric adenocarcinoma was the working diagnosis. Patient underwent subtotal radical gastrectomy along with lymph node dissection over left gastric, hepatic and splenic arterial group. (D2 gastrectomy). Postoperative period was uneventful and the final histopathological diagnosis revealed tumor cells infiltrating the lamina propria. The cells appeared in monotonous sheets, arranged in clusters and nests with retraction artifacts, intense desmoplasia and thin delicate fibrovascular stroma (Table/Fig 1 and Table/Fig 2). The nuclei appeared round to oval with scanty cytoplasm and no mitotic activity suggestive of Gastric Carcinoid. 10 out of 23 lymph nodes were positive and suggested high grade tumor. Patient was discharged on 9th postoperative day. 5 months after treatment; he has no evidence of locoregional spread or distant metastases on imaging study. The patient is currently asymptomatic and stable.



Table/Fig 1

100 magnification view showing monotonous looking tumor cells present in solid sheets with surrounding retraction artifacts separated by thin delicate fibrovascular stroma.



Table/Fig 2

40 magnification view showing normal looking gastric pits and islands of tumor cells arranged in clusters and nests infiltrating the lamina propria of stomach.

Discussion:

Gastrointestinal carcinoids arise from the enterochromaffin cells of Kulchitsky situated at the base of the crypts of Lieberkuhn, from cardia to anal sphincter.[1] The enterochromaffin cells belongs to APUD System that shares the features of Amine content, Precursor uptake and Decarboxylation. Carcinoid tumors are a group of well-differentiated Gastroenteropancreatic Neuroendocrine tumor (GEP-NET). The revised WHO Classification published in 2000 divided the GEP-NET into three broad groups – Ia: well-differentiated Neuroendocrine tumor; Ib: well-differentiated Neuroendocrine carcinoma; II: poorly differentiated Neuroendocrine carcinoma. The age at presentation in the stomach ranges from 25 to 89 years, average being 56years[3]. They remain clinically silent in majority of cases or present with non specific features like dyspepsia, loss of appetite as seen in our patient. Carcinoid syndrome consists of flushing, diarrhea, bronchospasm, valvular heart disease and occurs due to release of neuropeptides and tryptophan. Gastric Carcinoid seldom present with the typical Carcinoid syndrome [4]. Based on histology and clinical features, gastric carcinoids are divided in three groups: a) associated with atrophic gastritis, pernicious anemia, chronic thyroiditis; b) sporadic cases; c) associated with MEN-1 and Zollinger-Ellison Syndrome. Histopathologically, they are composed of small, monomorphic cells, uniform in size, arranged in clusters or ribbons. Intense desmoplasia may cause vascular occlusion as seen

here. Mitotic activity is rare and stands against Carcinoid[5]. Various neuroendocrine markers aids in the diagnosis like urinary 5-HIAA level, chromogranin A, synaptophysin, Substance P, neurotensin, somatostatin. Gastric carcinoid being of foregut origin doesn't show high urinary 5-HIAA levels. The frequent use of endoscopy has led to an increase in the detection of gastric carcinoid. Carcinoids are slow growing with a well recognized malignant potential [1]. Prognosis of gastric carcinoid is guarded and in a patient without lymph node or liver metastases survival of 10-15 years is not unusual[1]. In our case of sporadic GEP-NET, in spite of the disease being more aggressive with serosal involvement and 10 out of 23 nodes positive, patient is currently stable and asymptomatic.

Conclusion:

Carcinoids are rare tumors and the diagnosis is often made after surgery. Complete resection of the tumor tissue is the treatment of choice and if detected early can result in complete and permanent cure. Due to small numbers reported, there is a need for larger number of similar cases and longer follow-up to determine their natural history and treatment outcome. As the incidence is on the rise clinicians should be careful while evaluating patients with gastric mass with high index of suspicion of carcinoid tumor, as the pathological profile, treatment options and prognosis are different for gastric adenocarcinoma and carcinoids.

References

- [1] Balthazar JE, Megibow A, Bryk D, Cohen T. Gastric Carcinoids: Radiographic features in 8 cases. *AJR* 1982;139,DEC1982
- [2] Godwin JD II. Carcinoid tumors: An analysis of 2837 cases. *Cancer* 1975; 36: 560-569.
- [3] Railford TS: Carcinoid of the Gastro-intestinal tract, *Am J Cancer* 1993; 18: 803.
- [4] Bhatnagar S, Borg Grech A: Gastric polyposis caused by multiple carcinoids. *J Clin Pathol* 1995; 48: 589-591.
- [5] Salman Guraya Y, Khairi GA: Carcinoid of the meckel's diverticulum: *Saudi J of GE* 2006; 12: 139-141.