

# Evaluation of Stability of Implants Placed Simultaneously with Lateral Window Sinus Augmentation using Putty Alloplastic Bone Substitute: A Prospective Interventional Study

CHANDER PRAKASH<sup>1</sup>, NISHI TANWAR<sup>2</sup>, SUBRAMONY BHAGAVATHEESWARAN<sup>3</sup>

## ABSTRACT

**Introduction:** Lateral window sinus augmentation is done to augment the vertical sinus height for implant placement. Putty alloplasts have been used due to their longer resorption time and provide resistance to implant insertion. Although, widely used, the stability and bone loss around implants placed simultaneously following sinus augmentation with putty bone graft has not been evaluated.

**Aim:** To evaluate the effect of putty alloplastic bone substitute on implant stability.

**Materials and Methods:** A prospective interventional study was conducted in the Outpatient Department (OPD) of Oral and Maxillofacial surgery at SGT Dental College and Research Institute, Gurugram, Haryana, India. The duration of the study was two years and 11 months, from December 2014–November 2016. A total of 15 implants were placed simultaneously after lateral window sinus augmentation. Primary implant stability measurements were done using Resonance Frequency

Analysis (RFA). Vertical Bone Height (VBH), Maximum Insertion Torque (MIT) and Crestal Bone Loss (CBL) were measured till six months of follow-up. The data was analysed using standard statistical analyses with Shapiro-Wilk-test, Wilcoxon signed-rank test and Spearman's correlation co-efficient.

**Results:** The mean age of the study participants was 58±3.04 years. A total of 15 implants were placed in 12 patients. Adequate primary stability was achieved with MIT >36 N/cm<sup>2</sup> in 9/15 patients whereas, in 6/15 patients the MIT was ≤36 N/cm<sup>2</sup>. The implants showed 100% survival rate. Postoperative bone gain obtained was in the range of 7.89 mm to 11.9 mm, with a mean of 9.92 mm. Acceptable levels of implant stability were obtained after six months.

**Conclusion:** Within the limitations of the study, it can be concluded that, putty bone alloplast can serve as an adequate bone substitute in simultaneous implant placement after lateral window sinus augmentation and help in achieving stability.

**Keywords:** Osseointegration, Sinus floor augmentation, Torque

## INTRODUCTION

Placement of dental implants in edentulous posterior maxilla can be challenging because of increased pneumatization by the maxillary sinus resulting in a deficient hard tissue bed [1]. Various surgical techniques like summer's osteotome technique, lateral window technique, piezosurgery for sinus floor augmentation can be used depending upon the residual bone height. Osteotome technique with simultaneous placement of implants is performed, where more than 6 mm of residual bone is present and augmentation of about 3 to 4 mm is required. In case of more extensive pneumatization, a bone window in the lateral wall is required to elevate the Schneiderian membrane and augment the sinus floor. This lateral window technique has been reported to deliver a significantly larger increase in bone height than the osteotome technique [2]. Previous studies have established that, simultaneous implant placement can be done with lateral window sinus augmentation if a minimum bone height of 4-5 mm is present pre-operatively [3,4].

Usually, the sinus cavity is augmented using autogenous bone grafts, biomaterials, or their combination. Intraoral autogenous bone grafts, though osteogenic, provide a significantly small volume of donor bone. In addition, they fail to yield predictable results owing to their faster resorption time. Hence, alternatives to autogenous bone grafts have been pursued. Alloplastic materials are synthetic biocompatible products developed to cover a broad range of indications. They come in a great variety of textures, particle size, shape and consistency. Bioactive synthetic bone graft putty is a commercially available product that is premixed and mouldable,

which can be shaped and placed easily into osseous defect. It has four components: regular calcium phosphosilicate particles, smaller sized calcium phosphosilicate particles, binder composed of Phosphoethylene Glycol (PEG) and glycerin. Within hours of placement, Ca<sup>2+</sup> and PO<sub>4</sub><sup>2-</sup> ions along with soluble silica are released, forming a silica gel and hydroxyl carbonate apatite layer which recruits osteoprogenitor cells [5].

Primary implant stability has been identified as a prerequisite to achieve osseointegration [6-8]. This primary stability is critical at the time of implant insertion on grafted site also. Recently, Resonance-frequency Analysis (RFA) has been introduced to provide an objective measurement of implant stability and to monitor implant stability [9-18]. RFA is an effective method to measure changes in implant stability which may not be otherwise apparent clinically [10,11,14]. It is postulated that, the putty material acts as a viscoelastic medium that transfers the resistance of cortical bony walls of the sinus to the inserted implant similarly, to the function of cancellous bone during implant placement in an intact ridge, thus, increasing its primary stability. Therefore, it is suggested that, the remaining available bone and putty both together constitute in obtaining the primary implant stability [19]. It is important to know the role offered by putty alloplastic bone substitute in offering stability to implants placed in compromised conditions as that following lateral window sinus elevation. There are very few studies, which have evaluated the immediate stability of implants placed similarly [20,21]. So, the aim of present study was to evaluate the effect of putty alloplastic bone substitute on implant stability.

## MATERIALS AND METHODS

The present prospective interventional study was conducted in the OPD of Oral and Maxillofacial Surgery at SGT Dental College and Research Institute, Gurugram, Haryana, India. The duration of the study was two years and 11 months, from December 2014–November 2016. The present study was approved by Institutional Ethics Committee (IEC) approval number SGT/IEC/2014/28 and ethical principles were followed in accordance with Helsinki declaration as modified in 2013 [22]. Written informed consent was also obtained from all the patients.

The non probability convenient sampling was opted for the current study. After stringent inclusion and exclusion criteria, a total of 12 patients were recruited and 15 implants were placed in conjugation with lateral approach sinus elevation.

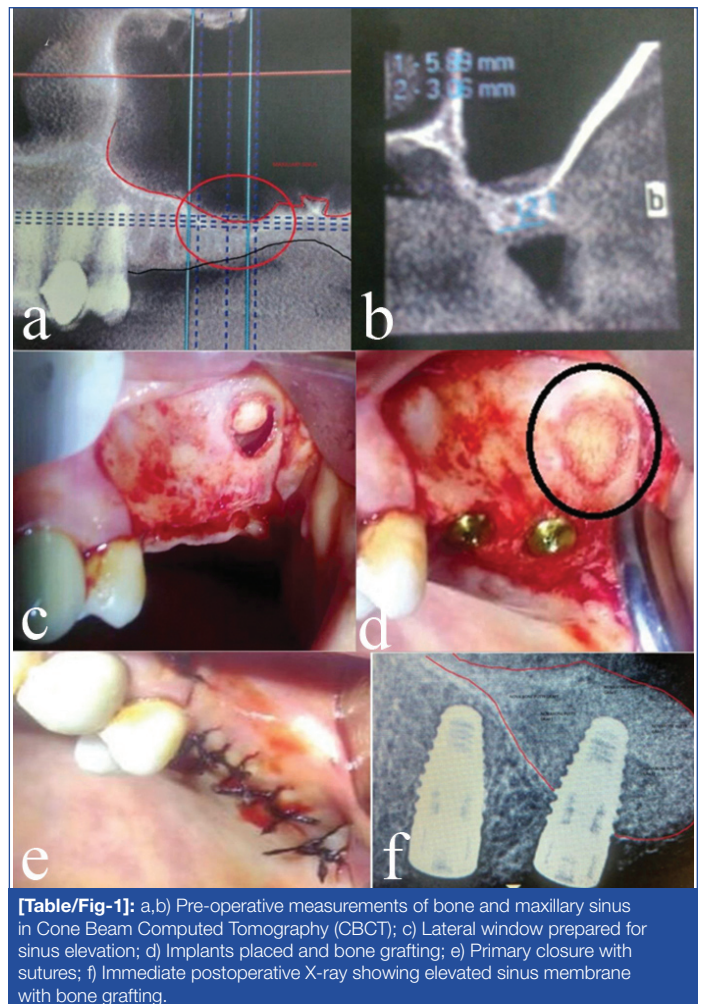
**Inclusion criteria:** Healthy male or female patients with inadequate bone height in the deficient posterior maxilla (presenting with edentulous, atrophic unilateral or bilateral maxillary arch with residual bone height less than 5 mm) who requires direct sinus lift with graft and implant placement.

**Exclusion criteria:** Patients with poor oral hygiene, chronic smoker, patient with systemic illness/systemic drugs that would affect postoperative healing, patient with acute and chronic sinus infections, patient unwilling for the follow-up, history of previous maxillary sinus surgery.

### Study Procedure

Oral prophylaxis was done two weeks before the scheduled implant placement. The edentulous site and maxillary sinus were evaluated using Cone Beam Computed Tomography (CBCT) [Table/Fig-1a,b] and implants of suitable length were planned. Direct sinus lift procedure was performed by preparing an osteotomy in the buccal wall to access the schneiderian membrane [Table/Fig-1c]. The boundaries of the osteotomy were determined by the dimension of the maxillary sinus and the amount of elevation as deemed necessary from the preoperative evaluation. The membrane was separated from bone and gently elevated with blunt instruments. The sinus cavity was then filled using alloplastic bone graft material, putty alloplastic bone substitute (NovaBone Dental Putty; NovaBone Products, Alachua, FL). The preoperative residual bone height was ranged from 2 mm to 4.2 mm. All the implants were placed simultaneously with the sinus lift surgeries [Table/Fig-1d]. The implants were slowly torqued into prepared osteotomy site. Primary stability was recorded as the MIT achieved using a torque wrench for the placement of the implant in its final position followed by RFA values, by means of a transducer attached to the implant via a screw and frequency response analyser (Osstell™ device, Integration Diagnostic AB, Sweden) [23].

Primary flap closure was achieved using a single interrupted suturing technique. Postoperative instructions such as, refraining from nose blowing and sucking with a straw were given. Patients were followed-up after one week for suture removal and to evaluate the soft tissue healing and then evaluated at three months and six months [Table/Fig-1e,f]. Standardised Intra Oral Periapical Radiography (IOPA) X-rays were taken to evaluate the amount of postoperative VBH (POSVBH) and to assess the radiographic signs of osseointegration. RFA values were recorded again with the same technique at the 6<sup>th</sup> month follow-up. During surgery for each implant, the implant diameter; implant length; and the insertion torque were recorded and the RFA value with the ISQ scale. In each patient, mesial and distal implant crestal bone levels were evaluated by calibrated examination of periapical X-rays. The periapical radiographs were taken by using long-cone paralleling technique, and the measurements were scaled using known markers (i.e., the length of the implant) to correct possible elongation or foreshortening of measurements.



**[Table/Fig-1]:** a,b) Pre-operative measurements of bone and maxillary sinus in Cone Beam Computed Tomography (CBCT); c) Lateral window prepared for sinus elevation; d) Implants placed and bone grafting; e) Primary closure with sutures; f) Immediate postoperative X-ray showing elevated sinus membrane with bone grafting.

Resonance Frequency Analysis Buccolingually (RFBL), Resonance Frequency Analysis Mesiodistally (RFMD) were measured at baseline (immediately after implant placement) and 6<sup>th</sup> month follow-up. CBL Mesial (CBLM), CBL Distal (CBLD), Pre VBH, POSVBH were measured at baseline, three months and six months after placement. MIT was noted at the time of implant insertion.

### STATISTICAL ANALYSIS

Data recorded was processed by standard statistical analysis in Statistical Package for Social Sciences (SPSS) software. The normality of distribution of data was examined by Shapiro-Wilk test. Data was found to be non normally distributed and hence, was subjected to non parametric test for statistical analysis. Intragroup comparison at two times interval was done using Wilcoxon signed-rank test and at three point intervals by Friedman analysis. Correlation between predictors and dependent variables was analysed by Spearman's correlation analysis. The level of statistical significance was  $p < 0.05$ .

### RESULTS

A total of 15 implants were placed in 12 patients (eight males and four females) with a mean age of  $58 \pm 3.04$  years [Table/Fig-2]. The preoperative residual bone height ranged from 2 to 4.2 mm (mean  $3.46 \pm 0.61$ ). Adequate primary stability was achieved with MIT  $> 36$  N/cm<sup>2</sup> in 9/15 patients (60%) whereas, the MIT was  $\leq 36$  N/cm<sup>2</sup> in 6/15 implants placed (40%). In all the cases (100%) atleast 25 N/cm<sup>2</sup> of MIT were achieved. Postoperative bone gain obtained was in the range of 7.89 mm to 11.9 mm, with a mean of 9.92 mm.

Gender	Number (n)	Percentage (%)
Male	08	66.7
Female	04	33.3

**[Table/Fig-2]:** Demographic details of patients.

[Table/Fig-3] represents intragroup comparison of parameters at baseline, three months and six months. On intragroup comparison mesiodistal and buccolingual RFA was highly statistically significant ( $p=0.001$ ). Mesial and distal crestal bone analysis was highly significant at baseline and six months follow-up ( $p=0.002$  and  $0.001$ , respectively). VBH gain was also statistically significant ( $p=0.001$ ) with mean postoperative bone height  $13.11\pm0.61$  mm at three month follow-up and  $12.67\pm0.67$  mm at six months.

Spearman's correlation in between various parameters [Table/Fig-4] revealed no significant correlation between RFA values and marginal bone loss.

Parameters	Baseline (Mean±SD) n=15	Three months (Mean±SD) n=15	Six months (Mean±SD) n=15	p-value
RFBL (ISQ value)	54.07±9.20	-	67.2±6.91	0.001
RFMD (ISQ value)	55.93±9.42	-	69.6±6.97	0.001
CBLM (mm)	-	0.17±0.21	0.51±0.30	0.002
CBLD (mm)	-	0.15±0.18	0.58±0.33	0.001
POSVBH (mm)	13.33±0.72	13.11±.61	12.67±0.67	0.001

**[Table/Fig-3]:** Comparison of parameters at baseline and six months.

Intragroup comparison at two times interval was done using Wilcoxon signed-rank test and at three point intervals by Friedman analysis

RFBL: Resonance frequency analysis buccolingually; RFMD: Resonance frequency analysis mesiodistally; CBLM: Crestal bone loss mesial; CBLD: Crestal bone loss distal; VBH: Pre vertical bone height; POSVBH: Postoperative vertical bone height; ISQ: Implant stability quotient

Parameters		RFMD6	CBM6	CBD6
CBLM6	Correlation coefficient	-	-	0.660*
	Significance (p-value)	-	-	0.007
RFBL6	Correlation coefficient	0.573*	0.015	0.378
	Significance (p-value)	0.026	0.956	0.164
RFMD6	Correlation coefficient	-	0.395	0.156
	Significance (p-value)	-	0.145	0.579

**[Table/Fig-4]:** Spearman's correlation in between various parameters.

CBLM6: Crestal bone loss mesial at six months; RFBL6: Resonance frequency analysis buccolingually at six months; RFMD6: Resonance frequency analysis mesiodistally at six months

## DISCUSSION

Several treatment options have been utilised in posterior maxillae to overcome the problem of inadequate bone quantity. The most conservative treatment is the insertion of short implants to avoid the need for entering the sinus cavity. However, the bone found in the posterior maxilla consists mostly of thin cortices and spongy cancellous compartments, hence, guarding the long-term success of short implants. The sinus lift procedure or sinus floor elevation, is an internal augmentation of the maxillary sinus, which is intended to increase the VBH in the lateral maxilla in order to facilitate the placement of implants [24]. Even though, sinus lift procedures are well documented, very few studies were carried out to understand if, the bone grafted during a sinus lift is able to assure a good primary stability during implant insertion and if it is able to maintain this stability even after six months. The augmentation of the maxillary sinus induces the bone formation by promoting osteoconduction from surrounding bone and is dependent on the rate of revascularisation and osteoblast recruitment [25,26]. During organisation of granulation tissue, inconspicuous perivascular cells are activated which, ultimately form bone [27].

The purpose of the present study, was to assess the stability of implants placed with the proposed sinus augmentation technique and to study the relationship of VBH, Insertion torque, and the RFA values at the time of implant placement and followed-up to six months. A statistically significant increase in RFA (ISQ value) was noted ( $p=0.001$ ) at six months follow-up. This finding is consistent with the finding of Sullivan D et al., [28]. Two implants had ISQ values less than 40 at the time of implant placement. This increased thereafter at the time of six month follow-up. In the present study,

statistically significant CBL was observed: mesially from  $0.17\pm0.21$  to  $0.51\pm0.30$  and distally from  $0.15\pm0.18$  to  $0.58\pm0.33$  at three months and six months, respectively. These findings fall well within the implant success criteria by Albrektsson T et al., [29]. Though, in the present study, the crestal bone resorption mesially and distally showed grafted sinus height loss for each implant between follow-up time intervals; however, apices of all implants were observed to be covered with grafted sinus floor and the reported loss in the VBH was due to CBL. The rapid initial bone loss in the present study might be the result of periosteal elevation, surgical trauma, and the osteotomy preparation of the recipient bed and stress concentration from tightening of the implant in less than 5 mm of remaining residual bone height. The average residual alveolar bone height was  $3.46\pm0.61$  mm preoperatively and after sinus floor augmentation, the increase in the residual bone height was in the range of 7.89 mm to 11.9 mm (mean 9.92 mm) with graft. The increase in post VBH was statistically very significant in the range of  $12.67\pm0.67$  mm after sinus floor augmentation over the period of six months following surgery. These findings were compatible with studies by Mazor Z et al., [30].

Despite CBL, the overall RFA values increased, which suggested that, the effect of bone loss was compensated by an increased interfacial stiffness resulting from bone formation and remodelling, due to the graft maturation and osseointegration [31]. No preoperative VBH was found to be the predictive value for implant stability. Even though, patients had very less residual bone height pre-operatively, good stability could be attained with marked increase in RFA values within six months. Implants in soft bone with low primary stability showed a marked increase in stability in the current study. The Calcium Phosphosilicate (CPS) putty acted as a viscoelastic medium, which transferred the resistance of cortical bony walls of the sinus during placement of implant similarly to the function of cancellous bone, thus, increasing its primary stability. It is assumed that, the primary stability of the implant was obtained from its anchorage in the remaining crestal bone and the putty present in the augmented sinus cavity. The viscoelastic characteristics of the putty bone substitutes and their enhanced graft particle containment allowed the surgeon to have a better tactile sensation during the implant surgical procedure. Therefore, if sufficient primary stability can be obtained, a single stage approach with simultaneous implant placement is preferred, even in minimal residual alveolar bone.

In the present study, all the implants achieved acceptable stability (ISQ >55) with sinus augmentation at the end of six months, which signifies a safe level of stability [32]. The bone height at baseline was not found to be the predictor of primary implant stability. The survival of implants placed was found to be 100% after six months of healing period. The simultaneous placement of implant in direct sinus lift thus, gives advantage of single stage surgery as being less invasive, more cost-effective, and saves time for the patients and a viable treatment option when primary stability can be assured.

### Limitation(s)

Limitations of the study include the small sample size and limited follow-up period. Long-term prospective studies are required to verify the findings of the present study and provide definitive guidelines for simultaneous implant placement, along with direct sinus lift procedures.

## CONCLUSION(S)

Simultaneous implant placement with sinus elevation and putty alloplastic bone grafting can be considered as a viable option for implant placement in case of atrophic maxillae. Within the limitations of the present study, it can be concluded that, implant placement with sinus elevation and putty alloplastic bone grafts yields a sufficient degree of osseointegration, even in bare minimum residual bone height of 2 mm. Initial primary stability seems to be a more pivotal factor for implant survival, rather than residual VBH in isolation.

## REFERENCES

- [1] Peleg M, Mazor Z. Augmentation grafting of the maxillary sinus and simultaneous implant placement in patients with 3-5 mm of residual bone height. *Int J Oral Maxillofac Surg.* 1999;14:549-56.
- [2] Watzek G, Weber R, Bernhart TH, Ulm CH, Haas HS. Treatment of patients with extreme maxillary atrophy using sinus floor augmentation and implants: Preliminary results. *Int J Oral Maxillofac Surg.* 1998;27:428-34.
- [3] Tatum OH Jr, Lebowitz MS, Tatum CA, Borgner RA. Sinus augmentation. Rationale, development, long-term results. *N Y State Dent J.* 1993;59(5):43-48.
- [4] Kent JN, Block MS. Simultaneous maxillary sinus floor bone grafting and placement of hydroxylapatite-coated implants. *J Oral Maxillofac Surg.* 1989;47(3):238-42. Doi: 10.1016/0278-2391(89)90225-5.
- [5] Eliaz N, Metoki N. Calcium phosphate bioceramics: A review of their history, structure, properties, coating technologies and biomedical applications. *Materials (Basel).* 2017;10(4):334.
- [6] Branemark PI, Hansson BO, Adell R, Breine U, Lindstrom J, Hallen O, et al. Osseointegrated implants in the treatment of the edentulous jaw. Experience from a 10-year period. *Scand J Plast Reconstr Surg.* 1977;16:01-132.
- [7] Adell R, Lekholm U, Rockler B, Branemark PI. A 15-year study of osseointegrated implants in the treatment of the edentulous jaw. *Int Journal of Oral Surgery.* 1981;10:387-416.
- [8] Albrektsson, T, Branemark PI, Hansson HA, Lindstro MJ. Osseointegrated titanium implants requirements for ensuring a long-lasting, direct bone to implant anchorage in man. *Acta Orthop. Scand.* 1981;52:155-70.
- [9] Meredith N, Book K, Friberg B, Jemt T, Sennerby L. Resonance frequency measurements of implant stability in vivo. A cross sectional and longitudinal study of resonance frequency measurements on implants in the edentulous and partially dentate maxilla. *Clin Oral Implants Res.* 1997a;8:226-333.
- [10] Meredith N, Shagaldi F, Alleyne D, Sennerby L, Cawley P. The application of resonance frequency measurements to study the stability of titanium implants during healing in the rabbit tibia. *Clin Oral Implants Res.* 1997b;8:234-43.
- [11] Friberg B, Sennerby L, Linden B, Grondahl K, Lekholm U. Stability measurements of one-stage Branemark implants during healing in mandibles. A clinical resonance frequency analysis study. *Int J Oral Maxillofac Surg.* 1999a;28:266-72.
- [12] Friberg B, Sennerby L, Meredith N, Lekholm U. A comparison between cutting torque and resonance frequency measurements of maxillary implants. A 20-month clinical study. *Int J Oral Maxillofac Surg.* 1999b;28:297-303.
- [13] Rasmusson L, Kahnberg KE, Tan A. Effects of implant design and surface on bone regeneration and implant stability: An experimental study in the dog mandible. *Clin Implant Dent Relat Res.* 2001;3:02-08.
- [14] Bischof M, Nedir R, Moncler S, Bernard JP, Samson J. Implant stability measurement of delayed and immediately loaded implants during healing. A clinical RFA study with SLA ITI implants. *Clin Oral Implants Res.* 2004;15:520-28.
- [15] Heo SJ, Sennerby L, Odersjö M, Granström G, Tjellström A, Meredith N. Stability measurements of craniofacial implants by the means of resonance frequency analysis. A clinical pilot study. *J Laryngol Otol.* 1998;112:537-42.
- [16] Balleri P, Cozzolino A, Ghelli L, Momicchioli G, Varriale A. Stability measurements of osseointegrated implants using Osstell in partially edentulous jaws after 1 year of loading: A pilot study. *Clin Implant Dent Relat Res.* 2002;4:128-32.
- [17] Thor A, Wannfors K, Sennerby L, Rasmusson L. Reconstruction of the severely resorbed maxilla with autogenous bone, platelet-rich plasma, and implants: 1-year results of a controlled prospective 5-year study. *Clin Implant Dent Relat Res.* 2005;7:209-20.
- [18] Degidi M, Daprile G, Piattelli A, Carinci F. Evaluation of factors influencing resonance frequency analysis values, at insertion surgery, of implants placed in sinus-augmented and non grafted sites. *Clin Implant Dent Relat Res.* 2007;9:144-49.
- [19] Knabe C, Adel-Khattab D, Kluk E, Struck R, Stiller M. Effect of a particulate and a putty-like Tricalcium Phosphate-based bone-grafting material on bone formation, volume stability and osteogenic marker expression after bilateral sinus floor augmentation in humans. *J Funct Biomater.* 2017;8(3):31.
- [20] Jodia K, Sadhwani BS, Parmar BS, Anchlia S, Sadhwani SB. Sinus elevation with an alloplastic material and simultaneous implant placement: A 1-stage procedure in severely atrophic maxillae. *J Maxillofac Oral Surg.* 2014;13(3):271-80.
- [21] Kher U, Mazor Z, Stanitsas P, Kotsakis GA. Implants placed simultaneously with lateral window sinus augmentation using a putty alloplastic bone substitute for increased primary implant stability: A retrospective study. *Implant Dent.* 2014;23(4):496-501.
- [22] General Assembly of the World Medical Association. World Medical Association Declaration of Helsinki: Ethical principles for medical research involving human subjects. *J Am Coll Dent.* 2014;81(3):14-18.
- [23] Meredith N. Assessment of implant stability as a prognostic determinant. *Int J Prosthodont.* 1998;11:491-501.
- [24] Smiler DG, Johnson PW, Lozada JL, Misch C, Rosenlicht JL, Tatum OH, et al. Sinus lift grafts and endosseous implants: Treatment of the atrophic posterior maxilla. *Dent Clin N Am.* 1992;36(1):151-86.
- [25] Avera, SP, Stampley WA, McAllister BS. Histologic and clinical observations of resorbable and non resorbable barrier membranes used in maxillary sinus graft containment. *Int J Oral Maxillofac Implants.* 1997;12:88-94.
- [26] Block MS, Kent JN. Sinus augmentation for dental implants: The use of autogenous bone. *J Maxillofac Surg.* 1997;55:1281-86.
- [27] Schenk RK, Buser D, Hardwick WR, Dahlin C. Healing pattern of bone regeneration in membrane-protected defects: A histologic study in the canine mandible. *Int J Oral Maxillofac Implants.* 1994;9:13-29.
- [28] Sullivan D, Sennerby L, Meredith N. Measurements comparing the initial stability of five designs of dental implants: A human cadaver study. *Clin Implant Dent Relat Res.* 2000;2:85-92.
- [29] Albrektsson T, Zarb G, Worthington P, Eriksson AR. The long-term efficacy of currently used dental implants: A review and proposed criteria of success. *Int J Oral Maxillofac Implants.* 1986;1(1):11-25.
- [30] Mazor Z, Peleg M, Garg AK, Chaushu G. The use of hydroxyapatite bone cement for sinus floor augmentation with simultaneous implant placement in the atrophic maxilla. A report of 10 cases. *J Periodontol.* 2000;71(7):1187-94.
- [31] Nakata H, Kuroda S, Tachikawa N, Okada E, Akatsuka M, Kasugai S, et al. Histological and micro-computed tomographic observations after maxillary sinus augmentation with porous hydroxyapatite alloplasts: A clinical case series. *Springer Plus.* 2016;5:260.
- [32] Sennerby L, Meredith N. Implant stability measurements using resonance frequency analysis: Biological and biomechanical aspects and clinical implications. *Periodontol 2000.* 2008;47:51-66.

## PARTICULARS OF CONTRIBUTORS:

1. Lecturer, Department of Oral Surgery, Theerthanker Mahaveer Dental College and Research Centre, Moradabad, Uttar Pradesh, India.
2. Professor, Department of Periodontics, Postgraduate Institute of Dental Sciences, Rohtak, Haryana, India.
3. Senior Resident, Department of Periodontics, Postgraduate Institute of Dental Sciences, Rohtak, Haryana, India.

## NAME, ADDRESS, E-MAIL ID OF THE CORRESPONDING AUTHOR:

Dr. Nishi Tanwar,  
Room No. 101, Professor, Department of Periodontics, Postgraduate Institute of  
Dental Sciences, Rohtak-124001, Haryana, India.  
E-mail: nsh\_tanwar@yahoo.co.in

## AUTHOR DECLARATION:

- Financial or Other Competing Interests: None
- Was Ethics Committee Approval obtained for this study? Yes
- Was informed consent obtained from the subjects involved in the study? Yes
- For any images presented appropriate consent has been obtained from the subjects. Yes

## PLAGIARISM CHECKING METHODS: [Jain H et al.]

- Plagiarism X-checker: Nov 05, 2022
- Manual Googling: Jan 12, 2023
- iThenticate Software: Feb 09, 2023 (8%)

ETYMOLOGY: Author Origin

EMENDATIONS: 7

Date of Submission: Nov 02, 2022

Date of Peer Review: Dec 07, 2022

Date of Acceptance: Mar 01, 2023

Date of Publishing: Jul 01, 2023