

Evaluation of Diagnostic Accuracy of Contrast-enhanced Computed Tomography in Acute Abdomen: A Cross-sectional Study

AJEET KUMAR MADHESIA¹, SANGRAM PANDA², SUDHANSU SEKHAR MOHANTY³, MATADHA KUMARASWAMY SUMA⁴, KAMAL KUMAR SEN⁵, RADHA KRISHNA KOLLURU⁶, SUNNY SWARAJ⁷, YALAMANCHI RAJESH⁸



ABSTRACT

Introduction: Acute abdomen is one of the most frequent causes of presentation to the Emergency Department (ED). The clinicians favour radiological examinations to reach the proper final diagnosis after thorough physical examinations, lab investigations, and clinical interpretation. Contrast-enhanced Computed Tomography (CECT) imaging aids in preventing delayed necessary treatment or unnecessary surgery.

Aim: To investigate the specificity and sensitivity of CECT in cases of the acute abdomen using histopathological, clinical, and intraoperative surgical findings as gold standards.

Materials and Methods: A cross-sectional study was conducted in the Department of Radiology, Kalinga Institute of Medical Sciences, Bhubaneswar, Odisha, India, from September 2020-2022. Evaluation of 115 patients was done based on inclusion (Patients presenting with clinical symptoms of acute abdomen and undergoing CECT Abdomen, followed by a clinical, biochemical,

surgical, or histopathological examination) and exclusion criteria. Sensitivity, specificity, Positive Predictive Value (PPV), Negative Predictive Value (NPV), and accuracy of CECT were calculated. The data were analysed using Statistical Package for Social Sciences (SPSS) version 22.

Results: The study included 115 patients with ages ranging from 9-88 years. An increased incidence in males was observed, M:F ratio of 1.4:1. The most common age group was 31-40 years (n-25; 21.7%), followed by 41-50 years (n-20; 17.4%). Cholecystitis was the most common cause of acute abdomen, accounting for 22.6% (n-26) of total cases followed by appendicitis. The overall accuracy rate of CECT was 93% with an accuracy of 98-99% in cases of cholecystitis appendicitis, pancreatitis, ovarian cyst, and bowel obstruction.

Conclusion: CECT shows higher sensitivity and specificity in identifying different aetiology of acute abdomen. It also helps in optimal decision-making for management and improved outcomes.

Keywords: Bowel obstruction, Ovarian cyst, Pancreatitis, Sensitivity

INTRODUCTION

An acute abdomen is defined as an entity with sudden onset of intense abdominal pain necessitating emergency medical/surgical management [1]. It is one of the most common complaints accounting for up to 7-10% of all ED visits [2,3]. Acute abdomen may result from a number of aetiologies, ranging from benign self-limiting conditions to life-threatening disorders. The clinicians favour radiological examinations to reach the proper final diagnosis after the patients had thorough physical examinations, lab investigations, clinical interpretation, and other testing procedures in the ED [4].

An accurate and efficient diagnosis should be provided for these individuals so as to lower the morbidity and mortality rates [5]. Sometimes, it could be difficult to diagnose because investigations like plain abdominal radiography and Ultrasonography (USG) are frequently inconclusive and clinical examination is difficult [6]. In such circumstances, CECT is commonly regarded as a primary investigation of choice [7-9]. CECT is preferred over non contrast CT because the use of contrast agents, either intravenous (i.v.) or orally, improves image quality by delineating anatomical structures more clearly. However, contrast enhancement is not always necessary and does come with some risks. The appropriateness of contrast enhancement usually depends on the suspected diagnosis [10].

Rapid and accurate diagnostic work-up is required to give appropriate triage and treatment. CECT is the fastest, very accurate, time-effective, objective, and most informative imaging technique. The solid organs, mesenteries, peritoneum, and retroperitoneal areas are all evaluated globally by CECT. The accuracy of diagnosis in acute abdomen cases has been improved as a result of the implementation of multi-planner reconstruction in the workstations through CECT [11]. The aim of this study was to investigate the

specificity and sensitivity of CECT in cases of different aetiologies of the acute abdomen using histopathological, clinical, and intraoperative surgical findings as reference standards.

MATERIALS AND METHODS

This cross-sectional study was conducted in the Department of Radiology, Kalinga Institute of Medical Sciences, Bhubaneswar, Odisha, India from September 2020-2022. Institutional Ethical Committee (IEC) approval was obtained (KIMS/R&D/PG/2020/03). Informed consent was obtained from all the subjects before the study. A total of 115 subjects were included and a consecutive sampling technique was followed.

Inclusion criteria: Patients presenting with clinical symptoms (such as abdomen pain, vomiting, abdominal distension, constipation, and fever) of acute abdomen and undergoing CECT abdomen, followed by a clinical, biochemical, surgical, or histopathological examination.

Exclusion criteria: Patients presenting with acute abdomen, but have not undergone CECT abdomen; patients for whom contrast media was contraindicated.

Study Procedure

The clinical history regarding the onset of symptoms, clinical progression of disease, and spectrum of findings were recorded. CECT was done using a 64-slice GE OPTIMA CT scanner. Non ionic contrast Iopromide (1.5 mL/kg body weight) i.v. contrast media with MEDRAD STELLANT double-barrel pressure injector at the rate of 4 cc/second using an 18 G i.v. cannula was administered. Non contrast images were acquired followed by the acquisition of arterial and venous phase images. Scan duration was 90 seconds

with a scanning delay time of 30 seconds for the arterial phase and 60 seconds for the venous phase. No oral or rectal contrast was given. The scan was rebuilt to create 5 mm axial sections from the lung bases to the pubic symphysis. Coronal and sagittal reconstructions were also made.

The radiological data of acute abdomen were collected systematically and were compared with medical, surgical and histopathological findings. Patients who are conservatively managed in non surgical instances were followed-up until clinical recovery and compared with CECT findings.

STATISTICAL ANALYSIS

Statistical analysis was done by using the computer-based SPSS-22.0 software program. Results were expressed in terms of frequency and percentages. Collected data were analysed by sensitivity, specificity, PPV, NPV and accuracy.

RESULTS

A total of 115 patients were included in this study with ages ranging from 9-88 years. An increased incidence in males was observed, M:F ratio of 1.4:1. The most common age group was 31-40 (21.7%; n=25) years, followed by 41-50 (17.4%; n=20) years [Table/Fig-1].

The most common clinical complaint of patients was abdominal pain (localised or diffuse) present in 100% of cases [Table/Fig-2].

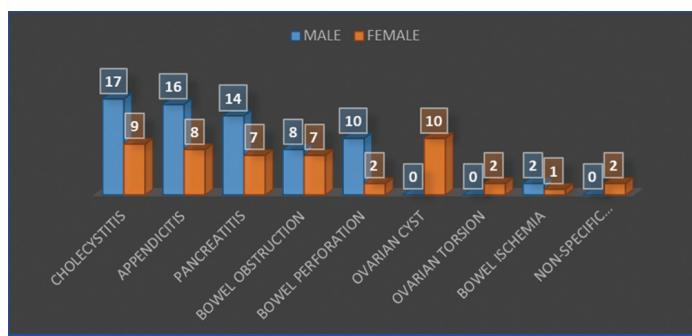
Age group (years)	Male	Female	Total
0-10	1	2	3 (2.6%)
11-20	4	5	9 (7.8%)
21-30	8	10	18 (11.6%)
31-40	10	15	25 (21.7%)
41-50	7	13	20 (17.4%)
51-60	7	9	16 (13.9%)
61-70	5	8	13 (11.3%)
71-80	5	4	9 (7.8%)
81-90	1	1	2 (1.7%)

[Table/Fig-1]: Age-wise distribution of acute abdomen (N=115).

Symptoms	No. of cases	Percentage
Abdominal pain	115	100%
Vomiting	76	66%
Constipation	44	38.3%
Abdominal distension	56	48.7%
Fever	69	60%

[Table/Fig-2]: Clinical presentation of patients.

Cholecystitis was the most common cause of acute abdomen, accounting for 22.6% (n=26) of total cases. The second commonest cause of acute abdomen was appendicitis which was seen in 20.8% (n=24) cases [Table/Fig-3].



[Table/Fig-3]: Number of cases with the gender-wise distribution of pathologies.

CECT showed a sensitivity of 100% in cases of bowel perforation, bowel obstruction, bowel ischaemia, ovarian torsion and cysts. CECT

showed a specificity and accuracy of 100% in diagnosing cases of bowel perforation, ovarian torsion and ovarian cyst [Table/Fig-4].

Pathology	Sensitivity	Specificity	PPV	NPV	Accuracy
Cholecystitis	100%	97.8%	92.9%	100%	98.3%
Appendicitis	96%	98.9%	96%	98.9%	98.3%
Pancreatitis	95.5%	98.6%	95.5%	98.6%	98.3%
Bowel obstruction	100%	99.0%	93.8%	100%	99.1%
Bowel perforation	100%	100%	100%	100%	100%
Ovarian cyst	100%	99.0%	90%	100%	99.1%
Ovarian torsion	100%	100%	100%	100%	100%
Bowel ischaemia	100%	100%	100%	100%	100%

[Table/Fig-4]: Statistical analysis of CECT in various pathologies detected among the study population.

In this study, surgical interventions were done in 80 cases (69.6%) and the remaining cases (n=35; 30.4%) were treated by medical management. The findings of this study showed concordance in 107 (93%) subjects between the final diagnosis and the CT diagnosis.

CT Diagnosis vs Final Diagnosis

In total, 8 discrepancies between the CECT diagnosis and the final diagnosis were seen [Table/Fig-5].

- One case with CECT diagnosis of acute appendicitis and one case with non specific abdominal pain with a clinical history of right iliac fossa pain, but the histopathological findings came out to be mucocele of the appendix and subacute appendicitis.
- Two cases with CECT diagnosis of acute pancreatitis and benign ovarian neoplasm turn out to be malignant on histopathology.
- Two cases with CECT diagnosis of acute on chronic cholecystitis, but histopathological findings came out to be adenomyomatosis and carcinoma gallbladder.

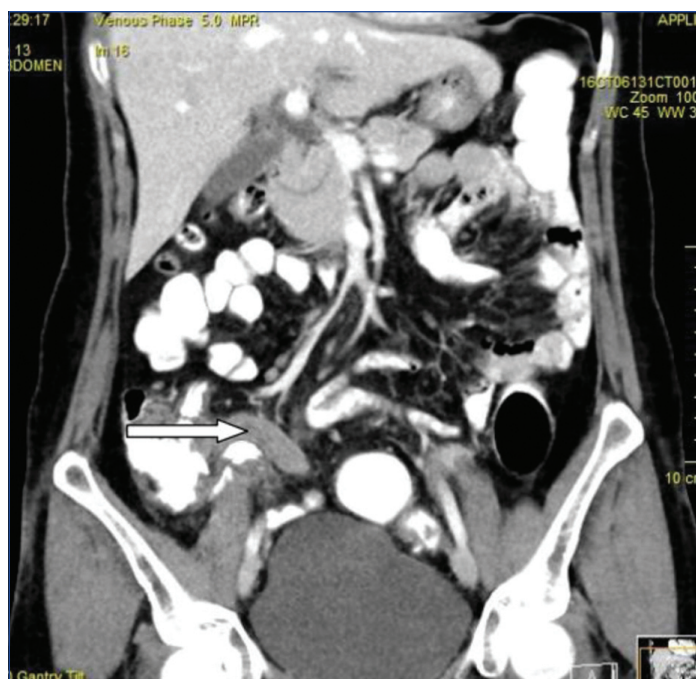
Discordance cases	CECT findings	HPE/Lab/Sx findings	Final diagnosis
1	Acute pancreatitis	Neoplastic cell	Pancreatic neoplasm
2	No abnormality detected	Raised amylase and lipase	Acute pancreatitis
3	Acute cholecystitis	Neoplastic cell	CAGB
4	Acute cholecystitis	Adenomyomatosis	Adenomyomatosis
5	Benign ovarian cyst	Neoplastic cell	Malignant ovarian cyst
6	Acute appendicitis	Mucocele of appendix	Mucocele of appendix
7	No abnormality detected	Subacute appendicitis	Subacute appendicitis
8	Large bowel obstruction	Pseudo-obstruction	Pseudo-obstruction

[Table/Fig-5]: Discrepancies between the CECT diagnosis and the final diagnosis.

DISCUSSION

Acute abdominal pain is defined as the pain in or over the abdominal cavity experienced for anything between a few hours and a few weeks [12]. Since USG may be non diagnostic or difficult to perform in some cases [13,14], the development of CT is the usual next imaging choice. In the present study, the CECT diagnosis was concordant with the final diagnosis in 93% of cases.

In this study, appendicitis was identified in 24 cases [Table/Fig-6]. Acute appendicitis exhibited 96% sensitivity in this study. The sensitivity of acute appendicitis (96%) was consistent with research by Rao PM et al., which discovered that CT had 91% to 100% sensitivity for diagnosing appendicitis [15]. The sensitivity of CECT (100%) for acute cholecystitis was as good as previous study sensitivities, which were 94% for CT [16].

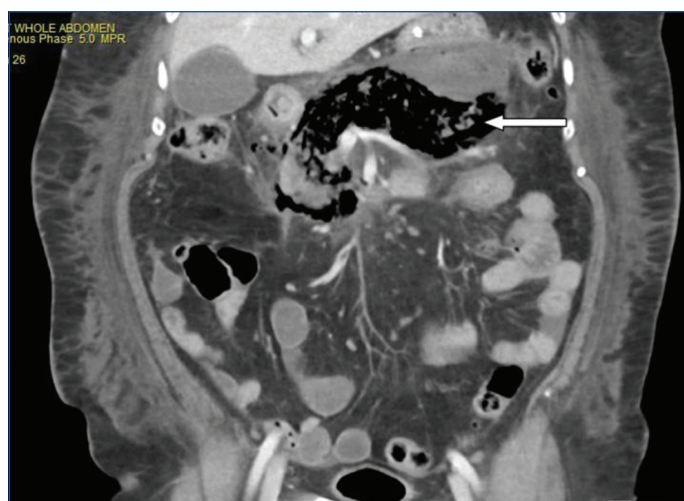


[Table/Fig-6]: Coronal image reveals a thickened and enlarged appendix with a tip on the right side of the pelvis, measuring up to 12 mm in thickness in the right iliac fossa along with minimum fat stranding. There is no evidence of peri-appendiceal fluid accumulation. The enlarged and thickened appendix (White arrow).

Torsion of the ovary causes ischaemia or infarction, both of which have long-term repercussions on fertility. Early detection and surgical intervention are crucial for preserving ovarian function [17]. The clinical signs, on the other hand, may be vague, resembling more common urologic or intestinal abnormalities, and CECT is employed as the primary imaging examination [17,18]. In patients with acute abdomen, bowel obstruction is an important differential diagnosis. Now a days, the CECT abdomen is the most appropriate radiological investigation for assessing suspected small and large bowel obstruction. A CECT scan can determine the degree of bowel obstruction, determine the aetiology of recurrent bowel obstruction, and differentiate between high- and low-grade obstruction. Additionally, CECT aids in evaluating obstruction-related complications like strangulation, bowel ischaemia, and pneumoperitoneum [19].

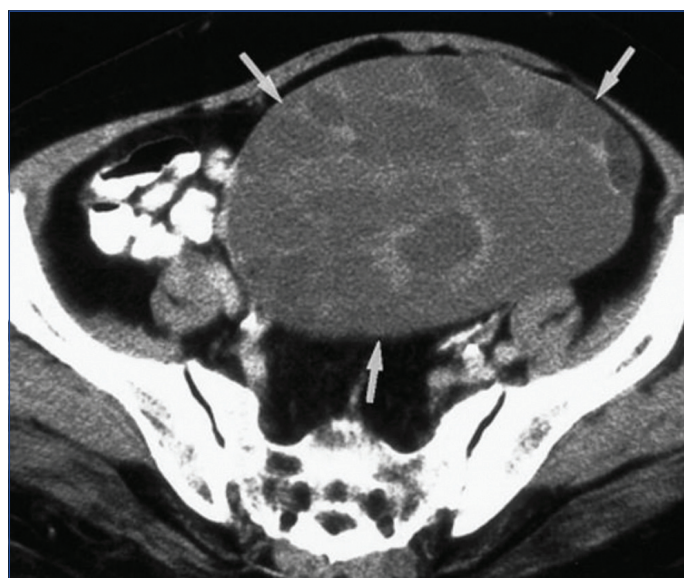In this study, 15 cases of bowel obstruction were diagnosed on CECT. Adhesions were the most prevalent cause of bowel obstruction which is in concordance with other study [20]. However, studies by Sindhvani G et al., Elsayed EE et al., and Mohi JK et al, showed the commonest cause of obstruction to be a malignancy [21-23]. The native patient population and the illness demography could be the reason accountable for the variance in the results. The detection of bowel obstruction with CT has been reported to have a sensitivity and specificity of 96% and 93%, respectively [24-27]. In this study, 14 out of 15 cases of intestinal obstruction were correlated with a final diagnosis with sensitivity, specificity, positive and negative predictive values of 100%, 99.0%, 93.8% and 100%, respectively. Acute pancreatitis is another common aetiology of acute abdominal pain in patients presenting to the ED. The clinical diagnosis of acute pancreatitis requires two of three features: 1) epigastric pain; 2) elevated serum amylase and lipase; and 3) characteristic findings on imaging [28]. There is significant morbidity associated with this condition. CECT characteristics of acute pancreatitis [Table/Fig-7] included size, peri-pancreatic fat stranding, parenchymal necrosis, collection, and calcification. In present study, sensitivity of acute pancreatitis was 95.5%. Similar outcomes are demonstrated by Beger HG et al., [29].

All bowel perforated cases were in concordance with the final diagnosis. As a result, each parameter showed 100% sensitivity, specificity, PPV and NPV, which was comparable to the research



[Table/Fig-7]: Coronal image of acute necrotising emphysematous pancreatitis shows necrosed and replaced by air in the head, neck body, and tail of the pancreas. Surrounding perinephric fat stranding and haziness was noted. Arrow points to the presence of air in the pancreas.

by Potter AW et al., which reported an accuracy of 82% to 90% for predicting the location of perforation by CECT [30]. While ultrasound is the initial modality of choice for acute gynecologic complaints, CT is frequently performed in the emergent setting given its wide availability and is often performed in patients with nonspecific pain [30]. In this study, 10 of the 115 participants had ovarian cysts [Table/Fig-8]. Sensitivity, specificity, PPV and NPV are therefore 100%, 99%, 90% and 100%, respectively. This was compared with Guo B et al., study [31], which reported that in 168 patients, CT had a sensitivity of 83.18% and a specificity of 85.25%.



[Table/Fig-8]: CECT scan (axial image) shows a large, multilocular cystic mass (arrows) with a smooth contour, honeycomb appearance, and heterogeneous attenuation in the locules suggestive of benign mucinous cystadenoma.

Limitation(s)

Not all of the aetiology of the acute abdomen was examined. The sample size for each acute abdomen was quite small. Due to the fact that, the majority of patients were sent for an emergency laparotomy after undergoing a USG assessment, the number of patients who come in for a diagnostic CT scan is quite small. Some patients such as pregnant women were subjected to radiation exposure limitations. One of the constraints was the expense.

CONCLUSION(S)

The CECT can aid the treating clinician to make proper management decisions. It helps to distinguish between surgical candidates and non candidates. Indicated management may vary from emergency surgery to reassurance of the patient and misdiagnosis may easily

result in delayed necessary treatment or unnecessary surgery. With the exception of acute cholecystitis, where USG showed to be extremely sensitive in the diagnosis, CECT may thus be regarded as the preferred imaging method.

REFERENCES

- [1] Silen W, Cope Z. Cope's early diagnosis of the acute abdomen. Oxford University Press, USA; 2005.
- [2] Hastings RS, Powers RD. Abdominal pain in the ED: A 35-year retrospective. *The American Journal of Emergency Medicine*. 2011;29(7):711-16.
- [3] Powers RD, Guertler AT. Abdominal pain in the ED: Stability and change over 20 years. *The American Journal of Emergency Medicine*. 1995;13(3):301-03.
- [4] Stoker J, van Randen A, Laméris W, Boermeester MA. Imaging patients with acute abdominal pain. *Radiology*. 2009;253(1):31-46.
- [5] Gore RM, Miller FH, Peres FS, Yaghami V, Berlin JW. Helical CT in the evaluation of the acute abdomen. *American Journal of Roentgenology*. 2000;174(4):901-13.
- [6] Gans SL, Stoker J, Boermeester MA. Plain abdominal radiography in acute abdominal pain; past, present, and future. *International Journal of General Medicine*. 2012;5:525-33.
- [7] Bolog N, Popiel A, Oancea I, Mangra A, Beuran M, Nicolau E. Multi-detector row spiral CT (MDCT) in bowel-related non traumatic abdominal emergencies. *Romanian Journal of Gastroenterology*. 2003;12(4):319-24.
- [8] Frauenfelder T, Wildermuth S, Marincek B, Boehm T. Nontraumatic emergent abdominal vascular conditions: Advantages of multi-detector row CT and three-dimensional imaging. *Radiographics*. 2004;24(2):481-96.
- [9] Leschka S, Alkadh H, Wildermuth S, Marincek B. Multi-detector computed tomography of acute abdomen. *European Radiology*. 2005;15(12):2435-47.
- [10] Radetic M, DeVita R, Haaga J. When is contrast needed for abdominal and pelvic CT? *Cleveland Clinic Journal of Medicine*. 2020;87(10):595-98.
- [11] De Muzio F, Cutolo C, Granata V, Fusco R, Ravo L, Magglaletti N, et al. CT study protocol optimization in acute non traumatic abdominal settings. *Eur Rev Med Pharmacol Sci*. 2022;26:860-78.
- [12] Binkovitz LA, Unsorfer KM, Thapa P, Kolbe AB, Hull NC, Zingula SN, et al. Pediatric appendiceal ultrasound: Accuracy, determinacy and clinical outcomes. *Pediatric Radiology*. 2015;45:1934-44.
- [13] Choudhary AK, Donnelly LF, Racadio JM, Strife JL. Diseases associated with childhood obesity. *American Journal of Roentgenology*. 2007;188(4):1118-30.
- [14] Ionising Radiation (Medical Exposure) Regulations 2000 (SI 2000 No 1059), London, HMSO, <http://www.opsi.gov.uk/si/si2000/20001059.htm>.
- [15] Rao PM, Rhea JT, Novelline RA. Sensitivity and specificity of the individual CT signs of appendicitis: Experience with 200 helical appendiceal CT examinations. *Journal of Computer Assisted Tomography*. 1997;21(5):686-92.
- [16] Wertz JR, Lopez JM, Olson D, Thompson WM. Comparing the diagnostic accuracy of ultrasound and CT in evaluating acute cholecystitis. *AJR Am J Roentgenol*. 2018;211(2):W92-W97.
- [17] Yaniv RT, Schonmann R, Agizim R, Sharvit M, Herzberger EH, Daykan Y, et al. Correlation between the length of ovarian ligament and ovarian torsion: A prospective study. *Gynecologic and Obstetric Investigation*. 2019;84(1):45-49.
- [18] Sintim-Damoa A, Majmudar AS, Cohen HL, Parvey LS. Pediatric ovarian torsion: Spectrum of imaging findings. *Radiographics*. 2017;37(6):1892-908.
- [19] Stoker J, van Randen A, Laméris W, Boermeester MA. Imaging patients with acute abdominal pain. *Radiology*. 2009;253(1):31-46.
- [20] Singh A, Makkar IK, Thukral CL, Gupta K, Uppal MS. Intestinal obstruction: Role of MDCT with surgical correlation. *Asian Journal of Medical Radiological Research* 2019;6(2):12-16.
- [21] Sindhwani G, Patel V, Jain A, Arora MA, Shah P. Multidetector Computed Tomography (MDCT) in gastrointestinal obstruction: One symptom myriad differentials. *International Journal of Anatomy, Radiology and Surgery*. 2017;6(4):RO45-RO51.
- [22] Elsayed EE, Habib RM, Soltan BS. Role of multidetector computed tomography in the diagnosis of intestinal obstruction. *Menoufia Medical Journal*. 2018;31(4):1456.
- [23] Mohi JK, Kajal S, Singh T, Singh J, Kaur N. Role of imaging in evaluation of intestinal obstruction. *Int J Med Res Rev*. 2017;5(06):593-603.
- [24] Taourel P, Kessler N, Lesnik A, Pujol J, Morcos L, Bruel JM. Helical CT of large bowel obstruction. *Abdom Imaging*. 2003;28(2):267-75.
- [25] Frager D, Rovno HD, Baer JW, Bashist B, Friedman M. Prospective evaluation of colonic obstruction with computed tomography. *Abdom Imaging*. 1998;23(2):141-46.
- [26] Godfrey EM, Addley HC, Shaw AS. The use of computed tomography in the detection and characterisation of large bowel obstruction. *N Z Med J*. 2009;122(1305):57-73.
- [27] Beattie GC, Peters RT, Guy S, Mendelson RM. Computed tomography in the assessment of suspected large bowel obstruction. *ANZ J Surg*. 2007;77(3):160-65.
- [28] Thoeni RF. The revised Atlanta classification of acute pancreatitis: Its importance for the radiologist and its effect on treatment. *Radiology*. 2012;262(3):751-64.
- [29] Beger HG, Maier W, Block S, Büchler M. How do imaging methods influence the surgical strategy in acute pancreatitis? In *diagnostic procedures in pancreatic disease 1986* (pp. 54-60). Springer, Berlin, Heidelberg.
- [30] Potter AW, Chandrasekhar CA. US and CT evaluation of acute pelvic pain of gynecologic origin in nonpregnant premenopausal patients. *Radiographics*. 2008;28(6):1645-59.
- [31] Guo B, Lian W, Liu S, Cao Y, Liu J. Comparison of diagnostic values between CA125 combined with CA199 and ultrasound combined with CT in ovarian cancer. *Oncol Lett*. 2019;17:5523-28.

PARTICULARS OF CONTRIBUTORS:

1. Junior Resident, Department of Radiodiagnosis, Kalinga Institute of Medical Sciences, Bhubaneswar, Odisha, India.
2. Assistant Professor, Department of Radiodiagnosis, Kalinga Institute of Medical Sciences, Bhubaneswar, Odisha, India.
3. Assistant Professor, Department of Radiodiagnosis, Kalinga Institute of Medical Sciences, Bhubaneswar, Odisha, India.
4. Junior Resident, Department of Radiodiagnosis, Kalinga Institute of Medical Sciences, Bhubaneswar, Odisha, India.
5. Professor, Department of Radiodiagnosis, Kalinga Institute of Medical Sciences, Bhubaneswar, Odisha, India.
6. Junior Resident, Department of Radiodiagnosis, Kalinga Institute of Medical Sciences, Bhubaneswar, Odisha, India.
7. Junior Resident, Department of Radiodiagnosis, Kalinga Institute of Medical Sciences, Bhubaneswar, Odisha, India.
8. Junior Resident, Department of Radiodiagnosis, Kalinga Institute of Medical Sciences, Bhubaneswar, Odisha, India.

NAME, ADDRESS, E-MAIL ID OF THE CORRESPONDING AUTHOR:

Matadha Kumaraswamy Suma,
Room No. 69, KIMS Girls Hostel, Patia, Bhubaneswar, Odisha, India.
E-mail: drajeetmadhesia@gmail.com

PLAGIARISM CHECKING METHODS: [Jain H et al.]

- Plagiarism X-checker: Jan 06, 2023
- Manual Googling: Mar 06, 2023
- iThenticate Software: Mar 28, 2023 (8%)

ETYMOLOGY: Author Origin

AUTHOR DECLARATION:

- Financial or Other Competing Interests: None
- Was Ethics Committee Approval obtained for this study? Yes
- Was informed consent obtained from the subjects involved in the study? Yes
- For any images presented appropriate consent has been obtained from the subjects. Yes

Date of Submission: **Jan 04, 2023**
Date of Peer Review: **Feb 06, 2023**
Date of Acceptance: **Mar 29, 2023**
Date of Publishing: **May 01, 2023**