

# Unusual Findings and Outcomes of Balloon Mitral Valvotomy

RAVINDRANATH K SHANKARAPPA<sup>1</sup>, YERISWAMY M CHANNABASAPPA<sup>2</sup>,  
ABDUL REHAMAN<sup>3</sup>, ARUN B SHIVASHANKARAPPA<sup>4</sup>, RAGHAVENDRA MURTHY<sup>5</sup>



## ABSTRACT

Balloon mitral valvotomy is a common procedure done for rheumatic mitral stenosis. However, certain cases may pose challenges and rarely may be life-threatening. Here, three unusual cases of balloon mitral valvotomy are presented. Case 1, a 42-year-old male, had procedural challenge in terms of Interatrial Septal (IAS) fibrotic thickening and calcification, posing difficulty in trans-septal puncture and crossing IAS with valvotomy balloon. Case 2, a 38-year-old female, had bidirectional Ventricular Tachycardia (VT) with a single dose of intravenous digoxin, and stress cardiomyopathy. Case 3, a 49-year-old male, had difficulty in negotiating valvotomy balloon towards apex and in the process, there was left ventricular free wall perforation.

**Keywords:** Bidirectional ventricular tachycardia, Interatrial septum, Left ventricular perforation, Stress cardiomyopathy

## INTRODUCTION

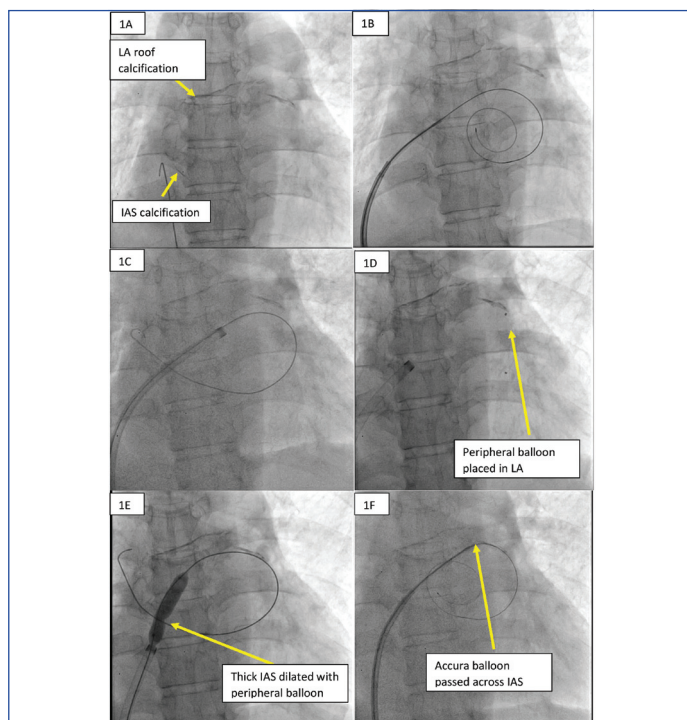
Balloon Mitral Valvotomy (BMV) has evolved over a period, since its introduction by Inoue in 1984 [1]. BMV is commonly performed interventional procedure for Rheumatic Mitral Stenosis (MS). BMV improves the valve orifice by splitting the fused commissures. In addition, it results in fracture of nodular calcium within leaflet structure. BMV has almost replaced surgical Closed Mitral Valvotomy (CMV) for pliable MS. It is associated with challenging steps like trans-septal puncture and rarely, life-threatening complications like cardiac tamponade due to left atrial, left ventricular perforation [2]. Here, three challenging cases of BMV have been presented.

## CASE SERIES

### Case 1

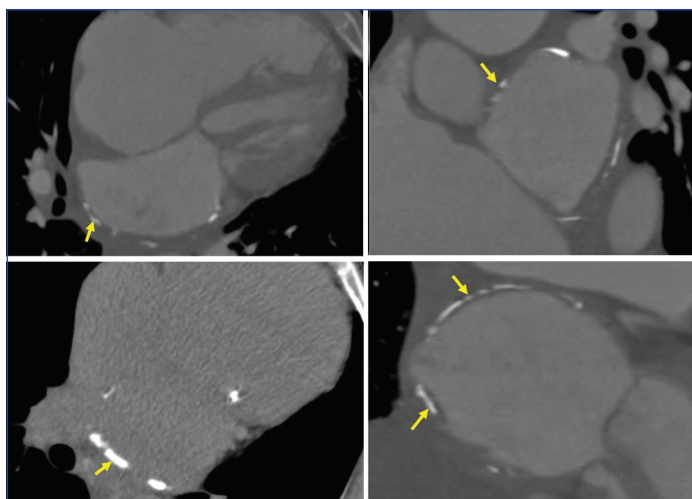
A 42-year-old male presented with dyspnoea for six months. He had Rheumatic Heart Disease (RHD), and had undergone Closed Mitral Valvotomy (CMV) 25 years back. On clinical evaluation, he was diagnosed with severe mitral restenosis, moderate Pulmonary Hypertension (PH) with Atrial Fibrillation (AF). Echocardiography showed severe Mitral Stenosis (MS) with Mitral Valve Orifice Area (MVOA) of 0.8 cm<sup>2</sup> and mild submitral fusion. Mean gradient across mitral valve was 16 mmHg. There was severe Tricuspid Regurgitation (TR) with Pulmonary Artery Systolic Pressure (PASP) of 50 mmHg. He was considered for BMV.

During BMV, there was resistance offered during puncturing of Interatrial Septum (IAS) with Brockenbrough needle. Fluoroscopy showed circumferential calcification of Left Atrium (LA). With difficulty, IAS was punctured, and LA coiled guidewire was introduced and dilated with septal dilator. But again, there was difficulty in crossing IAS with 24 mm Accura balloon. IAS was dilated with septal dilator repeatedly, even after which we could not cross the IAS with Accura balloon. Next, it was decided to dilate the IAS with peripheral balloon. A 0.035" exchange length wire was passed through the puncture made in IAS. Through the Cook's sheath, an 8×40 mm Indigo peripheral balloon was passed over the 0.035 wire and positioned across the IAS and dilated till the disappearance of the waist [Video-1]. 0.035' wire was exchanged with LA-coiled guidewire. Now, the authors could easily pass the Accura balloon across IAS and complete the procedure [Table/Fig-1, Video-1].



**[Table/Fig-1]:** Case 1: Left Atrium (LA) calcification and fibrosis causing difficulty in trans-septal puncture. a): LA calcification involving IAS and roof. b): Difficulty in crossing Accura balloon across IAS. c): 0.035' Exchange length wire passed into LA. d): Peripheral balloon placed in LA. e): Peripheral balloon placed across IAS and dilated. f): Accura balloon passed through the defect in IAS made with peripheral balloon.

Post-BMV, MVOA was 1.6 cm<sup>2</sup>, mean MV gradient decreased to 8 mmHg. Medial commissure was fully split, and lateral commissure was partially split. PASP reduced from 50 mmHg to 30 mmHg. Patient improved symptomatically. Later to assess the LA anatomy, cardiac Computed Tomography (CT) was performed. Circumferential mural calcification was noted in LA, predominantly involving free wall. There was calcification and asymmetrical fibrotic thickening (6-8.5 mm) of IAS [Table/Fig-2, Video-2]. It is unusual to have such marked fibrotic thickening of IAS and calcification, which posed procedural challenge in the form of difficulty in trans-septal puncture and taking valvotomy balloon across the IAS. A peripheral balloon was used to overcome this challenge and completed BMV successfully.

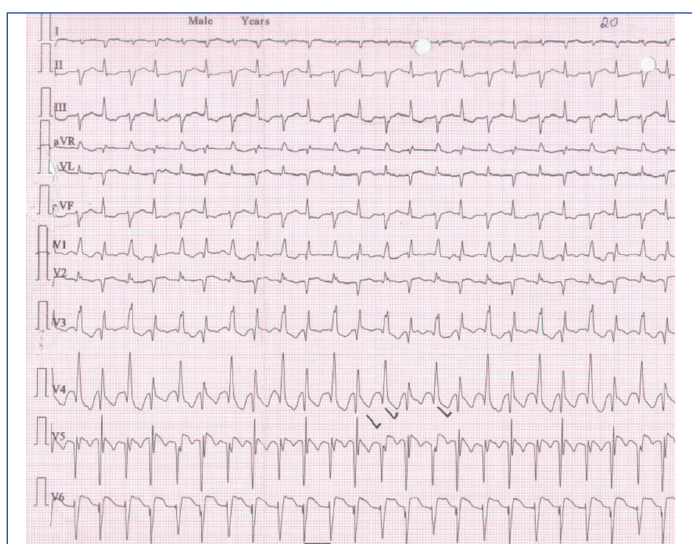


[Table/Fig-2]: LA calcification and fibrosis in case 1 shown in cardiac CT.

**Case 2**

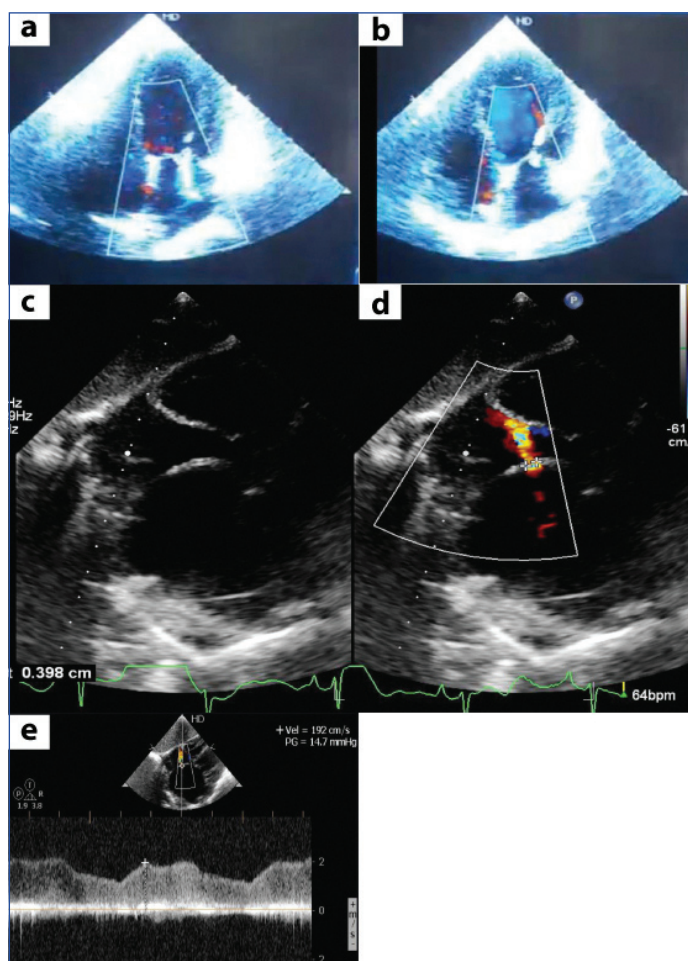
A 38-year-old female presented with dyspnoea for two months, increased since last one week. She was in AF with fast ventricular rate, pulmonary oedema, and cardiogenic shock. She was started on invasive ventilation in view of respiratory failure. Echocardiogram showed dilated LA, right atrium, and Right Ventricle (RV). IAS was thin and bulging towards right atrium. There was thickening of mitral leaflets, restricted mobility of posterior mitral leaflets and doming of anterior mitral leaflets suggesting rheumatic mitral stenosis. MVOA of 0.8 cm<sup>2</sup>. Mean gradient across mitral valve was 13 mmHg. Both the commissures were fused. The leaflets were pliable. There was mild mitral regurgitation (MR) and moderate TR. PASP was suprasystemic measuring 124 mmHg. RV dysfunction was present. There was LA appendage clot protruding into body (type IIB clot) measuring 2.7x1.2 cm. Left ventricular (LV) Ejection Fraction (EF) was 60%.

In view of unstable haemodynamics, she was considered for emergency BMV. Mean LA pressure was 40 mmHg. Mean gradient across mitral valve was 14 mmHg. Mitral valve was dilated with 26 mm Accura balloon, with two inflations done at 22 mm and 23 mm. There was a drop in mean gradient to 7 mmHg and increase in MVOA to 1.4 cm<sup>2</sup> following BMV. PASP reduced to 64 mmHg. There was mild MR, medial commissure was completely split, and lateral commissure partially split. AF with fast ventricular rate still persisted, despite intravenous amiodarone. Intravenous digoxin 0.25 mg was given to control the ventricular rate. But, she developed bidirectional Ventricular Tachycardia (VT) [Table/Fig-3]. She was treated with intravenous potassium chloride. Amiodarone infusion was continued.



[Table/Fig-3]: Electrocardiogram (ECG) showing bidirectional VT in case 2.

After 24 hours of BMV, sinus rhythm was restored and haemodynamics improved. Echo showed basal hypercontractility, with apical ballooning with reduced LVEF of 40% [Table/Fig-4, Video-3]. Also, there was a small, restrictive Atrial Septal Defect (ASD), at the site of trans-septal puncture, with left to right shunt [Table/Fig-4, Video-3]. Left ventricle angiogram showed basal hypercontractility and apical hypokinesia [Video-3]. By day 6, LV systolic function improved. RV systolic function was normalised. PASP reduced to 45 mmHg. Coronary angiogram showed normal epicardial coronaries. The present case was unusual in that the patient with severe MS, presented with cardiogenic shock, which was treated with emergency BMV. She developed bidirectional VT with single dose of intravenous digoxin, had stress induced cardiomyopathy and iatrogenic Lutembacher's syndrome.



[Table/Fig-4]: Case 2 with Stress-induced cardiomyopathy and iatrogenic Atrial Septal Defect (ASD). a,b): Echocardiography apical-4 chamber view with stress-induced cardiomyopathy; c, d): Echocardiography subcostal view showing 3 mm iatrogenic ASD as transeptal puncture site; e): Continuous wave doppler across ASD.

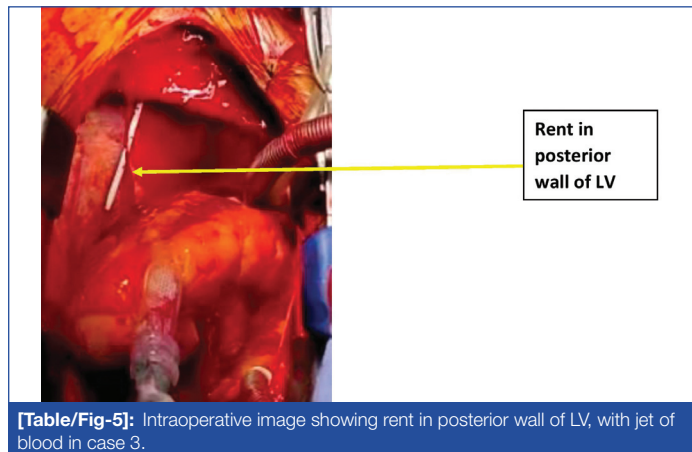
**Case 3**

A 49-year-old male presented with dyspnoea and effort intolerance from six months. He was diagnosed with RHD with severe MS about two months back and was advised mitral valve replacement, for which the patient was not willing. On Echocardiography, MVOA was 0.6 cm<sup>2</sup> with mean gradient of 10 mmHg. Both mitral leaflets were calcified at the tip, extending into chordae. There was severe submitral fusion and mild MR. Wilkin's Echo score was 12. There was trivial TR with PASP of 33 mmHg. As he was not willing for surgery, BMV was considered.

During BMV, there was difficulty in crossing mitral valve and negotiating the 24 mm Accura balloon to LV apex, as there was severe submitral disease. Each time it was getting entangled in submitral apparatus. Repeat attempts were made to take the balloon to LV apex. Patient suddenly became dyspnoeic and developed hypotension. Echocardiography showed large pericardial effusion with tamponade, suggesting cardiac perforation. Immediately, pericardiocentesis and

auto-transfusions were done. But there was rapid reaccumulation of haemopericardium. Immediately, cardiothoracic surgical team was consulted and taken for emergency surgery. Intraoperatively, 3 mm rent in posterior wall of LV was noted, with jet of blood [Table/Fig-5, Video-4]. The defect was repaired with felt. Mitral valve was replaced with 27 mm St. Jude's mechanical prosthetic valve. However, patient succumbed to disseminated intravascular coagulation on day five.

Key findings and outcomes of all the cases are summarised in [Table/Fig-6].



**[Table/Fig-5]:** Intraoperative image showing rent in posterior wall of LV, with jet of blood in case 3.

| Characteristics and outcomes       | Case 1   | Case 2   | Case 3  |
|------------------------------------|--|--|---|
| Age (years)/ Gender                | 42/Male  | 38/Female  | 49/Male   |
| Procedural challenges and findings | IAS* fibrosis and calcification causing difficulty in crossing BMV balloon | Cardiogenic shock, LA <sup>+</sup> appendage clot, post-BMV Stress induced cardiomyopathy, iatrogenic ASD <sup>‡</sup> , bidirectional ventricular tachycardia | Calcified mitral leaflets, and severe submitral disease causing difficulty in negotiating BMV balloon to LV? apex- LV perforation |
| Overcoming the challenge           | Dilatation of IAS with peripheral balloon                                  | Emergency BMV  | Repair of LV rent and mitral valve replacement  |
| Outcome                            | BMV <sup>†</sup> completed and discharged                                  | BMV completed, patient improved and discharged   | Succumbed   |

**[Table/Fig-6]:** Key characteristics and outcomes of the cases.

\*IAS: Interatrial septum, <sup>†</sup>BMV: Balloon mitral valvotomy, <sup>‡</sup>LA: Left atrium, <sup>§</sup>ASD: Atrial septal defect, LV: Left ventricle

## DISCUSSION

Case 1 was associated with difficulty in obtaining trans-septal puncture. The present case had rare finding of LA calcification, which is a relatively uncommon complication of long-standing RHD [3]. Calcification commonly involves LA appendage, LA free wall and mitral valve apparatus and is called porcelain atrium or coconut atrium [2]. IAS is rarely involved in calcification, which was seen in the present case. Thick fibrotic IAS, measuring 6-8.5 mm was another rare finding noted in this case, which posed difficulty in trans-septal puncture. In these cases, application of surgical electrocautery at the hub of Brokenbrough needle or the use of radiofrequency needle can be used to facilitate trans-septal puncture [4,5]. Despite a tremendous surge in interventional procedures utilising trans-septal puncture, IAS thickness assessment has not received much attention and is a less studied entity. Interatrial septum anatomy can be evaluated with transthoracic and trans-oesophageal Echocardiography [6], cardiac CT [7], magnetic resonance imaging [8] and intracardiac Echocardiography [9]. Pre-BMV assessment of IAS thickness helps in better planning of the procedure.

Emergency BMV in patient with very severe MS, like case 2 is challenging. Presence of AF with fast ventricular rate, cardiogenic

shock and LA clot (Type IB) were the challenges [10]. Following BMV, the haemodynamics improved. To control ventricular rate, digoxin was used. But she developed bidirectional VT, which is unusual with a single dose. Probably, due to low body weight, decreased renal clearance, as the patient was in cardiogenic shock and relatively low serum potassium (serum potassium=3.5 mEq/L), she might have developed digitalis toxicity at lower dose. She also developed stress cardiomyopathy, following BMV. There are case reports of Takotsubo cardiomyopathy following elective mitral valve surgeries [11,12]. But, its occurrence following BMV has not been reported in literature. Apart from this, patient also had iatrogenic ASD. However, it was not haemodynamically significant.

Case 3 had severe rheumatic MS with severe submitral disease and calcified leaflets. Hence, it was not an ideal case for BMV. During BMV, while crossing the mitral valve with Accura balloon, LV posterior wall perforation happened. The most frequent cause of BMV-related death has been LV perforation. This was previously associated with the double balloon technique, which requires insertion of LV guidewires [13]. LV perforation was also reported with metallic commissurotome [14]. Its incidence has come down substantially with the introduction of Inoue and Accura balloon. LV perforation with Accura balloon is not reported in literature. In the present case, because of severe submitral disease, possibly balloon might had been entangled in between the chordae and balloon tip might had been forced towards LV posterior wall causing perforation.

## CONCLUSION(S)

The BMV is a very useful and life-saving procedure in emergency situations. However, appropriate case selection, by preprocedural Echocardiography is important to improve the success rate and to avoid inadvertent complications. Rarely, one can encounter unusual findings during BMV, which need to be addressed appropriately.

## REFERENCES

- [1] Inoue K, Owaki T, Nakamura T, Kitamura F, Miyamoto N. Clinical application of transvenous mitral commissurotomy by a new balloon catheter. *J Thorac Cardiovasc Surg.* 1984;87(3):394-02.
- [2] Harikrishnan S. Percutaneous mitral valvotomy- Indications, Contraindications and Mechanisms. In: Harikrishnan S. Percutaneous mitral valvotomy. 2017:60-66.
- [3] Lee WJ, Son CW, Yoon JC, JO HS, Son JW, Park KH, et al. Massive left atrial calcification associated with mitral valve replacement. *J Cardiovasc Ultrasound.* 2010;18(4):151-53.
- [4] Gowda ST, Qureshi AM, Turner D, Madan N, Weigand J, Lorber R, et al. Radiofrequency puncture using surgical electrocautery in children and adults with and without complex congenital heart disease. *Catheter Cardiovasc Interv.* 2017;90(3):E46-E54.
- [5] Tokuda M, Yamashita S, Matsuo S, Kato M, Sato H, Oseto H, et al. Radiofrequency needle for transseptal puncture is associated with lower incidence of thromboembolism during catheter ablation of atrial fibrillation: Propensity score-matched analysis. *Heart Vessels.* 2018;33(10):1238-44.
- [6] Agmon Y, Meissner I, Tajik AJ, Seward JB, Petterson TM, Christianson TSH, et al. Clinical, laboratory, and transesophageal echocardiographic correlates of interatrial septal thickness: A population-based transesophageal echocardiographic study. *J Am Soc Echocardiogr.* 2005;18(2):175-82.
- [7] Yasunaga D, Hamon M. MDCT of interatrial septum, *Diagn Interv Imaging.* 2015;96(9):891-99.
- [8] Teo KS, Disney PJ, Dundon BK, Worthely MI, Brown MA, Sanders P, et al. Assessment of atrial septal defects in adults comparing cardiovascular magnetic resonance with transoesophageal echocardiography. *J Cardiovasc Magn Reson.* 2010;12(1):44.
- [9] Hijazi ZM, Shivkumar K, Sahn DJ. Intracardiac echocardiography during interventional electrophysiological cardiac catheterisation. *Circulation.* 2009;119(4):587-96.
- [10] Manjunath CN, Srinivasa KH, Ravindranath KS, Manohar JS, Prabhavathi B, Dattatreya PV, et al. Balloon mitral valvotomy in patients with mitral stenosis and left atrial thrombus. *Catheter Cardiovasc Interv.* 2009;74:653-61.
- [11] Devesa A, Hernández-Estefanía R, Tuñón J, Aceña A. Takotsubo syndrome after mitral valve surgery: A case report. *European Heart Journal-Case Reports.* 2020;4(6):01-05.
- [12] Blázquez JA, González JM, Dalmau MJ, López J. Takotsubo cardiomyopathy after elective mitral valve replacement. *Interact Cardiovasc Thorac Surg.* 2010;11(1):117-19.

[13] Harrison JK, Wilson JS, Hearne SE, Bashore TM. Complications related to percutaneous transvenous mitral commissurotomy. *Cathet Cardiovasc Diagn.* 1994;Suppl 2:52-60.

[14] Harikrishnan S, Bhat A, Tharakan J, Titus T, Kumar A, Sivasankaran S, et al. Percutaneous transvenous mitral commissurotomy using metallic commissurotome: Long-term follow-up results. *J Invasive Cardiol.* 2006;18(2):54-58.

#### PARTICULARS OF CONTRIBUTORS:

1. Professor, Department of Cardiology, Sri Jayadeva Institute of Cardiovascular Sciences and Research, Bengaluru, Karnataka, India.
2. Associate Professor, Department of Cardiology, Sri Jayadeva Institute of Cardiovascular Sciences and Research, Bengaluru, Karnataka, India.
3. Assistant Professor, Department of Cardiology, Sri Jayadeva Institute of Cardiovascular Sciences and Research, Bengaluru, Karnataka, India.
4. Assistant Professor, Department of Cardiology, Sri Jayadeva Institute of Cardiovascular Sciences and Research, Bengaluru, Karnataka, India.
5. Associate Professor, Department of CTVS, Sri Jayadeva Institute of Cardiovascular Sciences and Research, Bengaluru, Karnataka, India.

#### NAME, ADDRESS, E-MAIL ID OF THE CORRESPONDING AUTHOR:

Dr. Arun B Shivashankarappa,  
Shree Mallikarjuna, #K41, Upkar Meadows Layout, Kyalasanahalli,  
Jigani Anekal Taluk, Bengaluru, Karnataka, India.  
E-mail: arunbsmedicine@gmail.com

#### PLAGIARISM CHECKING METHODS: [Jain H et al.]

- Plagiarism X-checker: Aug 08, 2022
- Manual Googling: Oct 14, 2022
- iThenticate Software: Oct 15, 2022 (5%)

#### ETYMOLOGY: Author Origin

#### AUTHOR DECLARATION:

- Financial or Other Competing Interests: None
- Was informed consent obtained from the subjects involved in the study? Yes
- For any images presented appropriate consent has been obtained from the subjects. Yes

Date of Submission: **Jul 31, 2022**

Date of Peer Review: **Sep 15, 2022**

Date of Acceptance: **Oct 18, 2022**

Date of Publishing: **Dec 01, 2022**