

Role of Ovarian Artery to Uterine Artery Anastomosis in Uterine Artery Embolisation: A Retrospective Study

VASANTHAMANI PALANISAMY¹, ALAMELU MAHALINGAM², NACHIAPPAN RAMIAH³, PERIYAKARUPPAN ALAGAPPAN⁴, DEVIMEENAL JAGANNATHAN⁵



ABSTRACT

Introduction: Uterine Artery Embolisation (UAE) is now extensively recognised as a treatment for uterine fibroids, uterine artery pseudoaneurysms, and Uterine Arterio-Venous Malformations. The occurrence of collateral circulation from the ovarian artery to the uterine artery is one of the reasons for the failure of the process. The occurrence of ovarian failure and premature menopause after the UAE is high in patients with Utero-ovarian Artery (UOA) anastomosis.

Aim: To classify UOA as per Razavi MK et al., angiographic classification and to determine the presence of such anastomosis in UAE procedure failure cases.

Materials and Methods: A retrospective study was done for a period of two years from November 2017 to October 2019 in the Department of Radiodiagnosis, Government Kilpauk Medical College, Chennai, Tamil Nadu, India and Department of Interventional Radiology, Govt. Omandurar Multispeciality, Chennai, Tamil Nadu. UAE was performed with Poly Vinyl

Alcohol (PVA) microparticles (300 to 500 µm in size) followed by capping with a gelatin sponge in all 25 cases and coils were used in three cases. The presence or absence of UOA and four different types as per Razavi MK et al., angiographic classification were noted.

Results: Among 25 cases who underwent UAE, 14 had UOA. The majority (six cases) were type Ib, five cases were type Ia, two cases were type II and one case was type III. The bilateral anastomosis was noted in one case with type Ia and Ib on either side. Eight cases with UOA had successful embolisation. The UAE was successful in 16 cases, and failed in nine cases. Among various causes for failure, six out of nine were due to UOA. Among six failure cases of UOA, two cases were Type Ia, two cases were Type Ib, one case was Type II and one case was Type III anastomosis.

Conclusion: The UOA is one of the major risk factors in the procedural failures of the UAE. Identification avoids non target ovarian embolisation.

Keywords: Failure of uterine artery embolisation, Ovarian embolisation, Polyvinyl alcohol microparticles, Utero ovarian collateral circulation

INTRODUCTION

The UAE is an extensively known treatment for uterine fibroids, as an alternative to hysterectomy or myomectomy [1-3]. The other indications of UAE procedure include abnormal uterine bleeding, uterine artery pseudoaneurysm, and Uterine Arterio-Venous Malformations (AVM). The UAE procedure was extensively studied for its safety and effectiveness and is now widely accepted as a treatment option for fibroids by the American Congress of Obstetricians and Gynaecologists (ACOG) [4]. Preprocedural thorough evaluation includes menstrual and obstetric history, other medical histories, and physical examination. Most of the cases require bilateral uterine artery catheterisation and embolisation [5]. Among numerous reasons for procedural failure, the occurrence of collateral circulation from the ovarian artery to the uterine artery has been concerned as one of them [6,7]. The occurrence of ovarian failure and premature menopause after the UAE procedure is high in patients with UOA anastomosis [6]. Sheikh GT et al., analysed, postembolisation ovarian function and concluded that protective coiling can prevent ovarian failure [7]. For this the abnormal anastomoses have to be reliably classified. Minimal data is available regarding the importance and frequency of such anastomoses and high failure rates. So, this study was conducted with an aim to classify ovarian artery to uterine artery anastomosis and compare the presence of such anastomosis with UAE procedure failure.

MATERIALS AND METHODS

The present study was a retrospective cohort study done in the Department of Radiodiagnosis, Government Kilpauk Medical

College, Chennai, Tamil Nadu, India and Department of Interventional Radiology, Govt. Omandurar Multispeciality, Chennai, Tamil Nadu, India for a period of two years from November 2017 to October 2019. The analysis of the data was done in April 2022. Institutional ethical clearance was obtained (42/2019 dated 10/12/2019).

The study included all cases done in the study period. It includes all 25 cases, amongst which 20 were cases of uterine fibroid and five were cases of Uterine Arterio-Venous malformation.

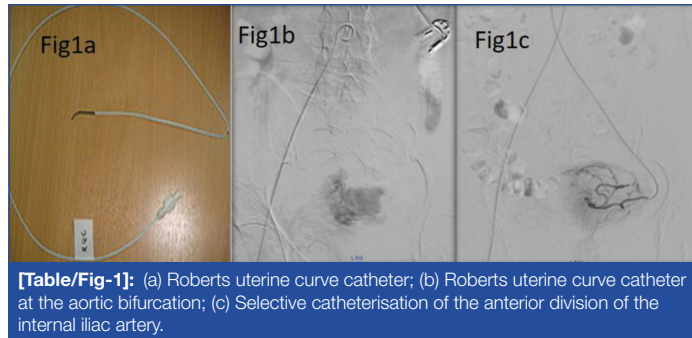
Inclusion criteria: For UAE, the inclusion criteria were patients presenting with hypermenorrhoea, symptomatic fibroid uterus, and Uterine AVM.

Exclusion criteria: Large leiomyoma (>10 cm) or multiple leiomyomas, malignant tumour in the uterus or adnexa, active pelvic inflammatory disease, pregnancy, allergy to iodine, and cases with renal failure were excluded from the study.

Pre-embolisation evaluation includes history to identify medical and gynaecological co-morbidities like anaphylactic reaction, coagulopathy, renal insufficiency, diabetes, hypertension, pelvic infection, previous surgeries, and a physical examination (Pulse, Blood Pressure (BP), abdominal examination, and Per vaginal examination). Radiological imaging includes Transabdominal and Transvaginal Ultrasound in conjunction with colour and pulsed Doppler ultrasound. Magnetic Resonance Imaging (MRI) was performed in all cases to assess the location of fibroid within the uterus, its number and size, the presence or absence of fibroid enhancement, associated adenomyosis, malignancies, and vascular malformations such as pseudoaneurysms and AVMs.

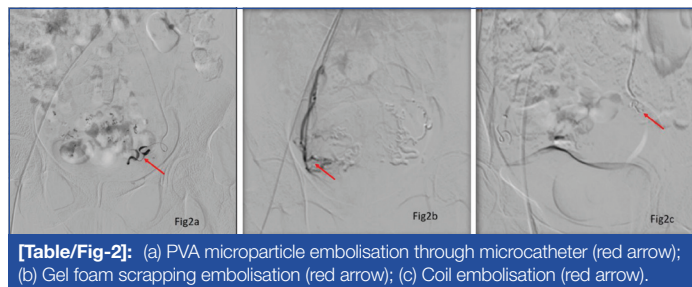
Embolisation

All patient access was through the right common femoral artery. In six cases pigtail aortogram was done to identify the ovarian artery. Bilateral uterine artery selective catheterisation was done using Roberts Uterine Curve Catheter 5Fr [Table/Fig-1a] in 19 cases. A 4-F Glide cobra catheter or a 5-F Cobra C2 catheter were alternative catheters used to selectively catheterise the anterior division of the internal iliac artery and into the uterine artery in six cases. Internal iliac arteriography [Table/Fig-1b,c] was done to localise the origin of the uterine arteries. Embolisation was performed with the catheter tip beyond the origin of the cervicovaginal branch in most cases, excluding it from the embolisation, to prevent the occurrence of dyspareunia.



[Table/Fig-1]: (a) Roberts uterine curve catheter; (b) Roberts uterine curve catheter at the aortic bifurcation; (c) Selective catheterisation of the anterior division of the internal iliac artery.

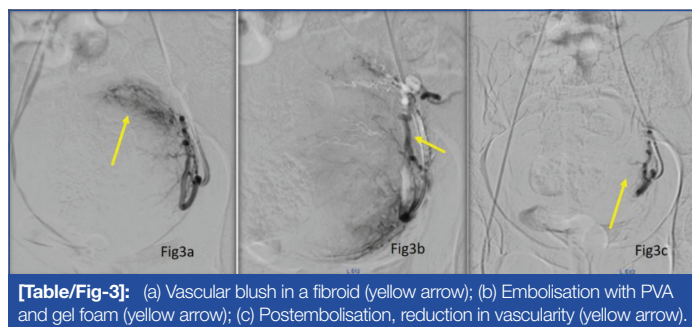
Embolic materials used were PVA microparticles [Table/Fig-2a] 300 to 500 µm in size followed by scrapings with a gel foam [Table/Fig-2b] of 6-25 mL depending upon the size of the fibroid and vascularity in all the cases and coils were used in three cases [Table/Fig-2c]. In cases of catheter induced vasospasm, a microcatheter (4-5 F) was used.



[Table/Fig-2]: (a) PVA microparticle embolisation through microcatheter (red arrow); (b) Gel foam scraping embolisation (red arrow); (c) Coil embolisation (red arrow).

Embolisation Endpoint

The endpoint of UAE [Table/Fig-3a-c] was to have a still column of contrast in the uterine artery, with only a stump of the uterine artery being filled with contrast, when the internal iliac artery was injected. The gel foam scrapings aid to cause complete occlusion of the uterine artery. It also stops the PVA particles from being drawn out of the uterine artery, and thereby non target embolisation.



[Table/Fig-3]: (a) Vascular blush in a fibroid (yellow arrow); (b) Embolisation with PVA and gel foam (yellow arrow); (c) Postembolisation, reduction in vascularity (yellow arrow).

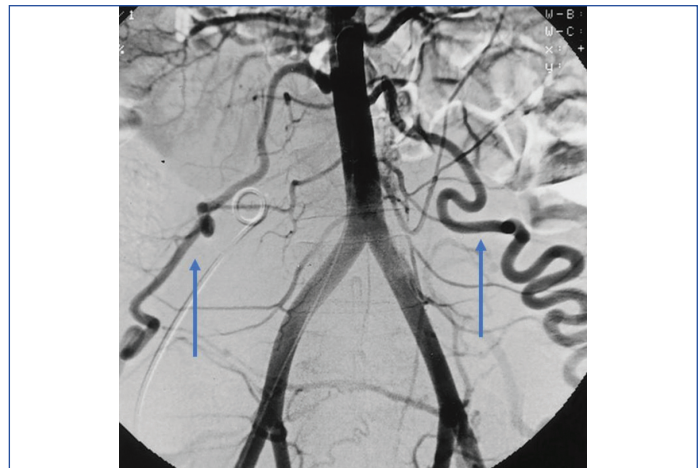
Postembolisation

Postembolisation follow-up was done in all the study cases at 1 day, 3 days, 7 days 1, 3, 6, 12 months and 18 months. They were asked to report back immediately if any adverse events occurred. Follow-up was done to assess the efficacy and long-term effects of UAE. The procedure was considered successful if the woman was free of heavy bleeding. The presence or absence of UOA was noted, classified as per Razavi MK et al., angiographic classification [6].

In Type I UOA-The ovarian artery is a major source of ovarian blood supply in the fibroids by means of direct anastomosis with the intramural uterine artery.

Type Ia UOA-No evidence of retrograde reflux in the direction of the ovary on selective uterine angiograms.

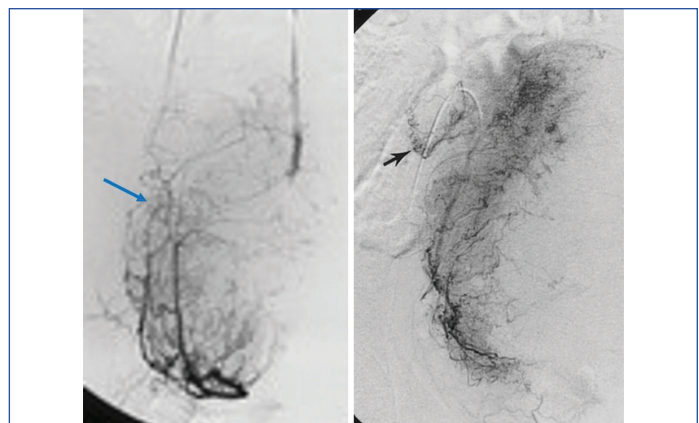
Type Ib UOA-Reflux is seen on pre-embolisation selective uterine angiograms [Table/Fig-4].



[Table/Fig-4]: Uterine ovarian anastomosis-Type Ib UOA (blue arrow-ovarian artery).

Type II UOA-Fibroids are directly supplied by the ovarian artery [Table/Fig-5].

Type III UOA-Selective uterine angiograms show tubal artery flow is towards the ovary [Table/Fig-6].



[Table/Fig-5]: Uterine ovarian anastomosis Type II UOA (blue arrow). **[Table/Fig-6]:** Uterine ovarian anastomosis Type III UOA Black arrow- tubular vessel going towards ovary when uterine artery injection was given, suggestive of type III. (Images from left to right)

STATISTICAL ANALYSIS

The collected data were analysed using Statistical Package for the Social Sciences (SPSS) version 20.0 software. Descriptive statistics were used.

RESULTS

The mean age was 34.36±13.97 years. Most of the patients 13 (52%) were in the age group of 21-30 years [Table/Fig-7].

Age group (years)	Number of cases (%)
≤20	1 (4)
21-30	13 (52)
31-40	4 (16)
41-50	3 (12)
51-60	2 (8)
61-70	1 (4)
71-80	1 (4)

[Table/Fig-7]: Age distribution of cases.

The presenting symptoms were pressure symptoms such as increased frequency of micturition in four patients, pelvic pain in 10 patients and menorrhagia in 18 patients. Among 25 cases who underwent UAE, 14 cases had uterine artery to ovarian artery anastomosis. Majority (six cases) were type Ib, five cases were type Ia, two cases were type II and one case was type III. Bilateral anastomosis was noted in one case with type Ia and Ib on either side.

Eight cases with UOA had successful embolisation. The procedure of UAE was successful in 16 cases, and failed in nine cases. Among various causes for procedural failure, six out of nine were due to UOA anastomosis. Among six cases of UOA anastomosis failure, two cases were Type Ia, two cases were Type Ib, one case was Type II and one case was Type III anastomosis [Table/Fig-8]. Among three other causes of failure, there were two cases of adenomyoma and the cause was not known in one. The complications noted were: One patient had internal iliac artery dissection during the procedure and one patient had fibroid passage. Fifteen patients had pelvic pain and low-grade fever which was managed with analgesics and antipyretic.

Type of anastomosis	Number of cases	Successful embolisation	Failed procedure
Type Ia	5	3 (22%)	2 (14%)
Type Ib	6	4 (29%)	2 (14%)
Type II	2	1 (7%)	1 (7%)
Type III	1	0	1 (7%)
Total	14	8 (58%)	6 (42%)

[Table/Fig-8]: Distribution of various types of UOA among successful and failed embolisation.

DISCUSSION

Many women had significant reduction in pain after UAE. Significant decrease was noted in bulk symptoms like abdominal wall distortion and pressure symptoms. Appreciable improvement was seen with menorrhagia [8,9]. Uterine embolisation is one of the uterine-sparing options [10]. UAE can be done preoperatively to reduce the bleeding complications perioperatively [11]. Goodwin SC et al., assessed the outcomes in long-term after UAE in a large cohort and states that UAE helps in durable improvement in the quality of life in symptomatic fibroids [12].

With the increasing use of calibrated microsphere embolic agents, embolisation procedure has become technically more easier [13], since it provides a predictable level of embolisation and minimises the incidence of clogging of both standard and microcatheters, which is a common problem with standard PVA preparations.

The causes of clinical failure of UAE have not been well studied and are multifactorial. Among various collaterals supplying uterus, ovarian artery is the major source of collateral blood vessel supply to uterine fibroids [14]. If not addressed appropriately, will cause postprocedural complications and failure. In 40% of cases, ovarian arteries supply the ovaries, 56% by both ovarian and uterine arteries, and 4% by uterine arteries alone [15,16]. Among various aetiologies posed for the presence of uteroovarian anastomosis, the dependence of the ovary on the uterine artery may be due to congenital absence of the ovarian artery. The occlusive lesions affecting the ovarian artery or the aorta, or ovarian abnormalities such as tumour or inflammatory conditions cause the recruitment of additional blood supply from the uterine artery [16]. Non visualisation of an ovarian artery-to-uterine artery anastomosis at selective angiography does not indicate the absence of such a connection.

In present study, of 14 cases with uterine ovarian anastomosis, five cases with type Ia, six cases with type Ib, two cases with type II and one case with type III anastomosis. In a similar study by Razavi MK et al., [6], 33 cases had type I anastomosis, six type II and 10 type III anastomosis, out of 76 consecutive cases undergoing UAE. The incidence of type I anastomosis was higher in this study,

similar to present. Kim HS et al., assessed the long-term outcomes (more than three years period) in young patients (less than 40 years old) who underwent UAE with and without UOA. He concluded that there is a significant improvement in symptoms related to fibroids. There was 27.5% chance of repeat interventions being needed if UOA was found in young women [17].

In Goodwin SC et al., study type Ia anastomosis was unlikely to be a source of procedural failure. Type II anastomosis- can be a cause of clinical failure due to incomplete fibroid embolisation [12]. In the present study, the failure rate of the procedure is less with type I anastomosis. In a study by Lanciego C et al., among 202 cases who underwent UAE, 104 cases were with UOA, amongst them, 38 anastomoses were bilateral, and 66 were unilateral. The most common was type III (66 cases) anastomosis followed by (22 cases) of type Ia and (18 cases) of type Ib. No type II was reported in this study. Twenty-seven women (14%) had amenorrhoea during a 5-year follow-up after UAE (3% of women were <45 years old). There were 10 cases of clinical failure with a median follow-up of >4 years [18].

Kim HS et al., demonstrated the correlation between utero-ovarian anastomosis at angiography with its histologic effect on patients who underwent UAE with or without Ovarian Artery Embolisation (OAE) for symptomatic uterine leiomyomata. In patients without utero-ovarian anastomosis angiography do not show particles in the ovary [19]. Another Kim HS et al., study on effects of utero-ovarian anastomoses on clinical outcomes, shows incidence of anastomoses on angiography was 40.3%. Although the overall repeat intervention rate after initial UAE is only 5.6%, higher incidence of repeat intervention rates after UAE were noted only in cases with UOA [20].

When the ovarian artery gives away collateral vessels to the uterus, it is important for the interventional radiologist to ensure that sufficient embolic material gets to the uterine fundus, beyond the point of ovarian artery inflow. Careful monitoring of the injection pressure during embolisation is mandatory, so that only minimal reflux occurs across the anastomosis and that embolic material does not get beyond the anastomosis. A small amount of reflux is allowed and then the refluxed material gets washed back into the uterus. Embolic material is taken back to the fundus by the ovarian artery inflow. The ovary escapes embolisation, it is found few centimeters proximal to the utero-ovarian anastomosis.

Embolisation using large gelatine sponge pledgets of the proximal ovarian artery has shown to decrease the filling pressure into the uterus, enough to provide a good clinical result without endangering the ovaries [21,22]. Embolisation of the ovarian artery collateral supply with relatively large gel foam particles (more than 500 to 600 µm) is also considered to be effective since these particles are too large to enter the ovarian vascular bed and hence will bypass the ovary and go into the uterine vascular bed [23]. A branch inferior epigastric artery-anatomically artery of the round ligament, may also supply the uterus. This vessel can very well be embolised with no or little fear of complications [24].

Ovarian failure is not the only reason for amenorrhoea, ischaemic endometrial damage from UAE is also a known cause [25]. Many authors have suggested routine pre-embolisation aortography to assess the ovarian arteries status and their branches to uterus, so that proper preprocedural planning can be done and adequate embolisation of supplying collaterals is ensured [9].

Limitation(s)

Limited sample size, retrospective nature of the study, selection bias since, the cases were taken from a tertiary centre and no attempt was done to correlate the occurrence of these anastomoses to other anatomic or physiologic factors.

CONCLUSION(S)

The UOA is considered one of the major risk factors in procedural failures of UAE. A routine abdominopelvic angiogram before and immediately after embolisation is recommended. The success of the UAE lies in the identification of the normal anatomical course of the uterine artery and the main variations in the arterial course. Identification of UOA anastomosis is helpful to avoid non target embolisation of ovarian artery.

REFERENCES

- [1] Lohle PN, Voogt MJ, De Vries J, Smeets AJ, Vervest HA, Lampmann LE, et al. Long-term outcome of uterine artery embolization for symptomatic uterine leiomyomas. *J Vasc Interv Radiol.* 2008;19(3):319-26.
- [2] Walker WJ, Barton Smith P. Long-term follow-up of uterine artery embolisation-an effective alternative in the treatment of fibroids. *BJOG.* 2006;113(4):464-68.
- [3] Spies JB, Cornell C, Worthington-Kirsch R, Lipman JC, Benenati JF. Long-term outcome from uterine fibroid embolization with tris-acryl gelatin microspheres: Results of a multicenter study. *J Vasc Interv Radiol.* 2007;18(2):203-07.
- [4] American College of Obstetricians and Gynecologists. ACOG practice bulletin. Alternatives to hysterectomy in the management of leiomyomas. *Obstet Gynecol.* 2008;112(2 Pt 1):387-400.
- [5] Bulman JC, Ascher SM, Spies JB. Current concepts in uterine fibroid embolization. *Radiographics.* 2012;32(6):1735-50.
- [6] Razavi MK, Wolanske KA, Hwang GL, Sze DY, Kee ST, Dake MD, et al. Angiographic classification of ovarian artery-to-uterine artery anastomoses: Initial observations in uterine fibroid embolization. *Radiology.* 2002;224(3):707-12.
- [7] Sheikh GT, Najafi A, Cunier M, Hess TH, Binkert CA. Angiographic detection of utero-ovarian anastomosis and influence on ovarian function after uterine artery embolization. *Cardiovasc Intervent Radiol.* 2020;43(2):231-37. Doi: 10.1007/s00270-019-02305-7. Epub 2019; PMID:31531692.
- [8] Goodwin SC, Vedantham S, McLucas B, Forno AE, Perrella R. Preliminary experience with uterine artery embolization for uterine fibroids. *J Vasc Interv Radiol.* 1997;8(4):517-26.
- [9] Vedantham S, Sterling KM, Goodwin SC, Spies JB, Shlansky-Goldberg R, Worthington-Kirsch RL, et al. Uterine fibroid embolization: Preprocedure assessment. *Techniques in Vasc Interv Radiol.* 2002;5(1):02-16.
- [10] Stokes LS, Wallace MJ, Godwin RB, Kundu S, Cardella JF. Quality improvement guidelines for uterine artery embolization for symptomatic leiomyomas. *J Vasc Interv Radiol.* 2010;21(8):1153-63.
- [11] Ravina JH, Ciraru-Vigneron N, Bouret JM, Herbreteau D, Houdart E, Aymard A, et al. Arterial embolisation to treat uterine myomata. *The Lancet.* 1995;346(8976):671-72.
- [12] Goodwin SC, Spies JB, Worthington-Kirsch R, Peterson E, Pron G, Li S, et al. Uterine artery embolization for treatment of leiomyomata: Long-term outcomes from the FIBROID Registry. *Obstet Gynecol.* 2008;111(1):22-33.
- [13] Levine A, Kim D, Termin P, Worthington-Kirsch RL. Comparison of embosphere and PVA embolization agents in a porcine renal model. *Cardiovasc Interv Radiol.* 2001;24:S168.
- [14] Worthington-Kirsch RL. Uterine artery embolization: State of the art. *Semin Intervent Radiol.* 2004;21(1):37-42.
- [15] Borell U, Fernstrom I. The ovarian artery. *Acta Radiologica.* 1954;42(4):253-65. Doi: 10.3109/00016925409174484.
- [16] Saraiya PV, Chang TC, Pelage JP, Spies JB. Uterine artery replacement by the round ligament artery: An anatomic variant discovered during uterine artery embolization for leiomyomata. *J Vasc Interv Radiol.* 2002;13(9):939-41.
- [17] Kim HS, Paxton BE, Lee JM. Long-term efficacy and safety of uterine artery embolization in young patients with and without uteroovarian anastomoses. *J Vasc Interv Radiol.* 2008;19(2):195-200.
- [18] Lanciego C, Diaz-Plaza I, Ciampi JJ, Cuena-Boy R, Rodríguez-Martín N, Maldonado MD, et al., Utero-ovarian anastomoses and their influence on uterine fibroid embolization. *J Vasc Interv Radiol.* 2012;23(5):595-01.
- [19] Kim HS, Thonse VR, Judson K, Vang R. Utero-ovarian anastomosis: Histopathologic correlation after uterine artery embolization with or without ovarian artery embolization. *J Vasc Interv Radiol.* 2007;18(1):31-39.
- [20] Kim HS, Tsai J, Patra A, Lee JM, Griffith JG, Wallach EE, et al., Effects of utero-ovarian anastomoses on clinical outcomes and repeat intervention rates after uterine artery embolization. *J Vasc Interv Radiol.* 2006;17(5):783-89.
- [21] Marret H, Alonso AM, Cottier JP, Tranquart F, Herbreteau D, Body G, et al. Leiomyoma recurrence after uterine artery embolization. *J Vasc Interv Radiol.* 2003;14(11):1395-99.
- [22] Andrews RT, Bromley PJ. Successful embolization of collaterals from the ovarian artery during uterine artery embolization for fibroids: A case report. *Pfister MEJ Vasc Interv Radiol.* 2000;11(5):607-10.
- [23] Binkert CA, Andrews RT, Kaufman JA. Utility of nonselective abdominal aortography in demonstrating ovarian artery collaterals in patients undergoing uterine artery embolization for fibroids. *J Vasc Interv Radiol.* 2001;12(7):841-45.
- [24] Worthington-Kirsch RL, Hughes LA. Uterine artery embolization-vascular anatomic considerations and procedure techniques. In: *Uterine fibroids 2003*:83-90. Cambridge University Press, Cambridge, United Kingdom.
- [25] Marx M, Wack JP, Baker EL, Stevens SK, Barakos JA. Ovarian protection by occlusion of uteroovarian collateral vessels before uterine fibroid embolization. *J Vasc Interv Radiol.* 2003;14(10):1329-32.

PARTICULARS OF CONTRIBUTORS:

1. Dean, Government Kilpauk Medical College Hospital, Chennai, Tamil Nadu, India.
2. Postgraduate Student, Department of Radiology, Government Kilpauk Medical College Hospital, Chennai, Tamil Nadu, India.
3. Assistant Professor, Department of Biochemistry, Madras Medical College, Chennai, Tamil Nadu, India.
4. Consultant Interventional Radiologist, Department of Intervention Radiology, Government Omandurar Medical College, Chennai, Tamil Nadu, India.
5. Professor and Head, Department of Radiology, Government Kilpauk Medical College Hospital, Chennai, Tamil Nadu, India.

NAME, ADDRESS, E-MAIL ID OF THE CORRESPONDING AUTHOR:

Dr. Devimeenal Jagannathan,
No-10, Poonamalle High Road, Kilpauk, Chennai, Tamil Nadu, India.
E-mail: devinachi@gmail.com

PLAGIARISM CHECKING METHODS: [Jain H et al.]

- Plagiarism X-checker: Jun 11, 2022
- Manual Googling: Sep 24, 2022
- iThenticate Software: Oct 11, 2022 (25%)

ETYMOLOGY: Author Origin

AUTHOR DECLARATION:

- Financial or Other Competing Interests: None
- Was Ethics Committee Approval obtained for this study? Yes
- Was informed consent obtained from the subjects involved in the study? Yes
- For any images presented appropriate consent has been obtained from the subjects. Yes

Date of Submission: **May 23, 2022**

Date of Peer Review: **Jul 28, 2022**

Date of Acceptance: **Oct 17, 2022**

Date of Publishing: **Dec 01, 2022**