

# Accessory Mandibular Foramina: Prevalence, Embryological Basis and Surgical Implications

B.V. MURLIMANJU, LATHA V. PRABHU, M.D. PRAMEELA, C. MOHAMMED ASHRAF, ASHWIN KRISHNAMURTHY, C. GANESH KUMAR

## ABSTRACT

**Introduction:** Our objective was to determine the incidence of accessory mandibular foramina (MA) in mandibles of south Indian origin.

**Methods:** The study comprised 67 adult, human, dry mandibles which were procured from the departments of anatomy of our university. The prevalence rate and the laterality were analyzed.

**Results:** The accessory mandibular foramina were observed in 11 mandibles (16.4%). They were present unilaterally in 6

(8.9%) mandibles (3 on the right side and 3 on the left side) and bilaterally in 5 (7.5%) cases. The accessory foramen was single in 9 cases and it was found to be double in 2 cases.

**Conclusion:** In the current study, the incidence rate of the accessory mandibular foramina was 16.4%. The morphological knowledge of these foramina is important as they transmit the branches of the nerves which supply the roots of the teeth. The local anaesthetic drug which is given in this region may fail if these nerves or their branches pass through the accessory foramina.

**Key Words:** Accessory foramen; anaesthesia; foramina; inferior alveolar nerve; mandible

## KEY MESSAGE

- The current study observed that some of the mandibles (16.4%) had accessory foramina (two or three mandibular foramina). These foramina are clinically important as they can lead to diagnostic and therapeutic misinterpretations. The operating surgeons should be aware of these foramina and they should plan the anaesthesia at an appropriate site.

## INTRODUCTION

The mandibular foramen (MF) is a prominent feature [1] on the medial surface of the ramus of the mandible which is located just above its centre [2]. There are a few cases which have been reported on the accessory mandibular foramina (AMF) and the incidence of the AMF has been found to be greater on the medial surface than on the lateral surface [3-5]. The branches of the facial, mylohyoid, buccal and the transverse cervical cutaneous nerves are known to pass through these accessory foramina [2]. Przystanska and Bruska [6] studied these foramina immunohistochemically and proved that their contents included an artery and a nerve. Injecting an anaesthetic solution into the pterygomandibular region where the inferior alveolar nerve is found in the MF, is an anaesthetic technique which is commonly employed in the dental clinic. It was reported that the local anaesthesia which was given during dental extractions might fail if the branches of the inferior alveolar nerve pass through these accessory foramina and thus escape the drug. The AMF are also known to provide the route for tumour spread following radiotherapy [7-10]. Since detailed anatomical studies are not found in the literature, this osteological investigation was undertaken. The objective of this study was to assess the morphology of AMF and to determine the prevalence of AMF in south Indian mandibles.

## MATERIALS AND METHODS

The study included 67 (37 male and 30 female) dry human mandibles of south Indian origin, which were procured from the

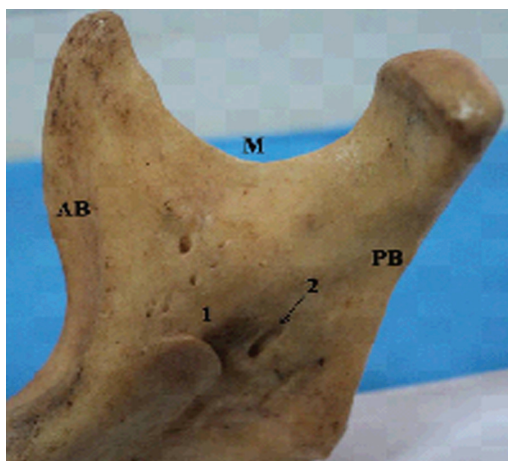
departments of anatomy of our university. All were adult mandibles, the exact ages of which were unknown. The mandibles were observed for the presence of AMF and if they were present, a further observation was made about their numbers. Their prevalence rate and laterality were also analyzed. A magnifying lens was used for the observations.

## OBSERVATIONS

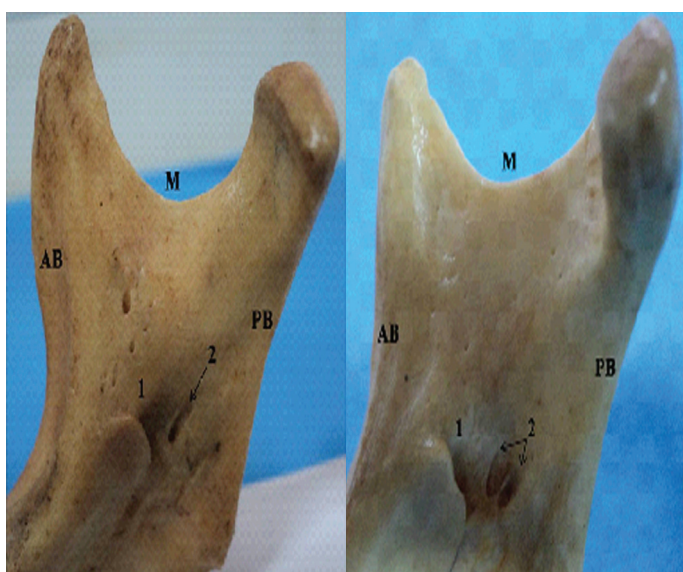
From our observations, it was found that the accessory mandibular foramen [Table/Figs 1 and 2] was present in 11 mandibles (16.4%). It was present unilaterally in 6 (8.9%) mandibles (3 on the right side and 3 on the left side) and bilaterally in 5 (7.5%) cases. The gender wise frequency was recorded as 6:5 in the male and female mandibles. The accessory foramen was single [Table/Fig 1] in 9 cases and double in 2 cases [Table/Fig 2]. In all the cases, the accessory foramen was directed downwards towards the alveolar margin. Mandibles with an absent mandibular foramen were not observed.

## DISCUSSION

The morphological knowledge of the MF is of paramount importance during the dental procedures of the lower jaw, as structures that go through this foramen should be preserved. The AMF are known to transmit the branches of the inferior alveolar nerve. It has been described that the presence of an AMF in the mandible also indicates that extra blood vessels traverse it, which supply the bone [11]. Hence, the passage of the blood vessels and nerves



**[Table/Fig-1]:** Photograph of the medial surface of the right half of the mandible showing a single accessory mandibular foramen (2). (1- mandibular foramen; AB- anterior border, PB- posterior border, M- mandibular notch)



**[Table/Fig-2]:** Photograph of the medial surface of the right half of the mandible showing two accessory mandibular foramina (2). (1- mandibular foramen, AB- anterior border, PB- posterior border, M- mandibular notch)

makes the AMF clinically important. It was reported that in 60% of the cases, the mandibular canal was found to have the entire inferior alveolar nerve passing through it, while in the remaining 40% cases, the nerves were found to be scattered [12]. This observation of the spread of the inferior alveolar nerve suspects the possible presence of some other nerves which pass through the mandibular canal, probably the nerves to the mylohyoid [11]. Das and Suri [3] passed a metallic wire through the AMF and examined the mandible radiographically. They observed that the canal which led from the AMF had terminated close to the root of the 3rd molar. This alternate route of passage of the nerves through the AMF and their supply to the 3rd molar might lead to the failure of the nerve block during dental surgeries. Lew et al. [13] reported a case in which the presence of an accessory canal resulted in inadequate anaesthesia at the time of the inferior alveolar nerve block. Hence, it is obvious that the awareness of the presence of these AMF is important for achieving a successful inferior alveolar nerve block. Some authors advised that the anaesthesia could be best performed at a higher level before the division of the mandibular nerve [14] by using a technique which is known as the Gow-Gates

technique [15]. The embryological basis of the occurrence of the AMF and the fact that during the development, initially there will be three inferior alveolar nerves which innervate each of the 3 groups of the mandibular teeth, have been explained [16]. Later, there will be fusion of these nerves and a single inferior alveolar nerve is formed. The incomplete fusion of these 3 nerves leads to the development of double mandibular canals [16]. From the clinical observations, it has been found that there is a wide range of incidence of the bifid mandibular canals which are reported between 0.08% and 15.6% [17]. But the anatomical reports about this subject are not available in literature. In the present study, the incidence of the AMF was slightly higher as compared to other studies and it might be because of racial variations.

It has been found that the presence of the AMF makes it more vulnerable to the perineural spread of the tumour cells from the cortical to the cancellous part of the bone following radiotherapy [4]. The knowledge of the AMF may thus be important for the radiotherapists while planning radiation therapy. During surgical procedures which involve the ramus of the mandible, it is important to be familiar with the incidence and the configuration of these foramina, since complications including unexpected bleeding, paraesthesia and traumatic neuroma are known to occur because of trauma to the accessory canal [17]. The surgeons who perform the conservative rim resection procedures should keep in mind about the tumour involvement in the region of the AMF and they can plan the surgical procedure accordingly [3]. This knowledge is also important for orthognathic or reconstructive surgeries of the mandible and dental implant procedures [10,18]. It was suggested that the morphology of the MF should be included in the orthodontic and anthropological evaluation of normal and pathological mandibles [19]. A great majority of the authors suggest that the imperfectness in the attainment of anaesthesia of the inferior alveolar nerve is due to improper localization of the mandibular foramen and the lack of notice of its variations [20], which shows the lack of the professional studies of anatomy [21]. Since the clinical interest about the AMF is extensive and as the anatomical references are not available, we aimed to submit this investigation for the medical and dental literature. These findings may be helpful to the oral maxillo-facial surgeons and oncologists in their clinical practice. We suggest that the surgeons who perform extraction procedures of the lower jaw should be aware of these accessory foramina and thus plan anaesthesia at an appropriate anatomical site. By pinpointing these anatomical variations, it is possible to take the necessary precautions during surgeries and avoid damaging the important neurovascular structures.

## REFERENCE LIST

- [1] Fabian FM: Observation of the position of the lingula in relation to the mandibular foramen and the mylohyoid groove. *It J Anat Embryol.* 2006; 111: 151-58.
- [2] Gray H, Williams PL, Bannister LH, Berry MM, Collins P, Dyson M, Dussek JE, Ferguson MWJ, et al : (eds) *Gray's Anatomy: 38 edition.* London, Churchill Livingstone, 1995, pp 576-7
- [3] Das S, Suri RK: An anatomico-radiological study of an accessory mandibular foramen on the medial mandibular surface. *Folia Morphol.* 2004; 63: 511-13.
- [4] Fanibunda K, Matthews JNS: Relationship between accessory foramina and tumour spread in the lateral mandibular surface. *J Anat.* 1999; 195: 185-90.
- [5] Haveman CW, Tebo HG: Posterior accessory foramina of the human mandible. *J Prosthetic Dentistry.* 1976; 35: 462-8.
- [6] Przystanska A, Bruska M: Accessory mandibular foramina: histological and immunohistochemical studies of their contents. *Arch Oral Biol.* 2010; 55: 77-80.
- [7] Browne JS, Browne RM: Factors influencing the pattern of invasion

of the mandible by oral squamous cell carcinoma. Intern J Oral Maxillofacial Surg. 1995; 24: 417–26.

- [8] Lukinmaa PL, Hietanen J, Soderholme AL, Lindqvist C: The histologic pattern of bone invasion by squamous cell carcinoma of the mandibular region. Br J Oral Maxillofac Surg. 1992; 30: 2–7.
- [9] Mc Gregor DA, Mac Donald DG: Routes of entry of squamous cell carcinoma into the mandible. Head Neck Surg. 1987; 10: 294–301.
- [10] Slootweg PJ, Muller H: Mandibular invasion by squamous cell carcinoma. J Craniomaxillary Surg. 1989; 17: 69–74.
- [11] Jeyaseelan N, Sharma JK: A morphological study of unnamed foramina in the North Indian human mandibles and their possible role in neurovascular transmission. Int J Oral Surg. 1984; 13: 239–42.
- [12] Olivier E: Le canal dentaire inferior et son nerf chez Padulte. Anns Anat Path Anat Norm Med Chir. 1927; 4: 975–87.
- [13] Lew K, Townsen G: The failure to obtain adequate anaesthesia is associated with a bifid mandibular canal: a case report. Aust Dent J. 2006; 51: 86–90.
- [14] Sanchis JM, Penarrocha M, Soler M: The bifid mandibular canal. J Oral Maxillofac Surg. 2003; 61: 422–24.
- [15] Meechan JG: How to overcome failed local anaesthesia. Br Dent J. 1999; 186: 15- 20.
- [16] Chavez ME, Mansilla J, Pompa JA, Kjaer I: The human mandibular canal arises from three separate canals, innervating different tooth groups. J Dent Res. 1996; 75: 1540–44.
- [17] Kuribayashi A, Watanabe H, Imaizumi A, Tantanapornkul W, Katakami K, Kurabayashi T, et al: Bifid mandibular canals: cone beam computed tomography evaluation. Dentomaxillofacial Radiology. 2010; 39: 235–39.
- [18] Quattrone G, Furlini E, Bianciotto M: Bilateral bifid mandibular canal: Presentation of a case. Minerva Stomatol. 1989; 38: 1183–5.
- [19] Palsson SR, Kjaer I: Morphology of the mandibular canal and the angulation between the mandibular and mental canals in dry skulls. Eur J Orthodont. 2009; 31: 59–63.
- [20] Simon B, Komives O: Dimensional and positional variations of the ramus of the mandible. J Dent Res. 1938; 17: 125-49.
- [21] Marzola C: Anestesiologia. 3 edition. Sao Paulo, Pancast, 1999, pp 323

#### AUTHOR(S):

1. Dr. B.V. Murlimanju
2. Dr. Latha V. Prabhu
3. Dr. M.D. Prameela
4. Dr. C. Mohammed Ashraf
5. Dr. Ashwin Krishnamurthy
6. Dr. C. Ganesh Kumar

#### PARTICULARS OF CONTRIBUTORS:

1. Corresponding Author
2. MD, Professor and Head, Department of Anatomy, Manipal University, Centre for Basic Sciences, Kasturba Medical College, Mangalore, Karnataka, India.
3. MD, Asst. Professor, Department of Anatomy, Manipal University, Centre for Basic Sciences, Kasturba Medical College, Mangalore, Karnataka, India.
4. Postgraduate Student, Department of Anatomy, Manipal University, Centre for Basic Sciences, Kasturba Medical College, Mangalore, Karnataka, India.
5. MD, Associate Professor, Department of Anatomy, Manipal University, Centre for Basic Sciences, Kasturba Medical College, Mangalore, Karnataka, India.
6. MD, Asst. Professor, Department of Anatomy, Manipal University, Centre for Basic Sciences, Kasturba Medical College, Mangalore, Karnataka, India.

#### NAME, ADDRESS, TELEPHONE, E-MAIL ID OF THE CORRESPONDING AUTHOR:

Dr. BV Murlimanju  
MD, Assistant Professor, Department of Anatomy,  
Kasturba Medical College, Manipal University,  
Mangalore – 575004, India.  
Telephone No. : 91 824 2211746  
Telefax No. : 91 824 2421283  
E-mail: flutesnowmm@gmail.com

#### DECLARATION ON COMPETING INTERESTS:

No competing Interests.

Date of Submission: **Jan 11, 2011**  
Date of per review: **Mar 31, 2011**  
Date of acceptance: **Aug 08, 2011**  
Date of Publishing: **Nov. 11, 2011**