

# A Rare Case of Takayasu's Arteritis with Hyperthyroidism

MOHAMMED ASHRAF, SAYYID M.K., R. ARUNACHALAM, ANITHA SEQUEIRA, VEERENDRA H.K.

## ABSTRACT

Both Takayasu's arteritis and hyperthyroidism are of uncertain aetiologies. An autoimmune mechanism has been implicated in both these diseases. We had a patient who presented with both the diseases simultaneously. A 23 year old female patient was admitted with a history of generalised weakness and exertional breathlessness since 15 days. On physical examination, she was found to have pallor and absent pulses in the upper limbs. An early diastolic murmur with S3 was heard on cardiac examination. The diagnosis of aortic regurgitation (AR) with congestive cardiac failure (CCF) due to Takayasu's arteritis was made. The blood investigations showed elevated ESR and C-reactive protein (CRP). 2DEcho showed global hypokinesia ultrasonography

(USG) of the neck showed diffuse goiter. The thought field therapy (TFT) showed that thyroid stimulating hormone (TSH) was 0.01 ug/ml, T4 was 19.18 ug/ml and that TPO was normal but the thyroglobulin antibody levels were elevated (761 U). MDCT showed diffuse stenosis in the bilateral subclavian artery, an aberrant right subclavian artery, the narrowing of the left vertebral, celiac and superior mesenteric arteries and multiple chest wall and intra-abdominal collaterals. She was put on steroids, antithyroid drugs and antiplatelets. One and a half year later, she presented with renovascular hypertension (HTN), and her aortogram showed bilateral renal lesions also. She then underwent angioplasty of the right subclavian and both the renal arteries. She is presently under regular follow up and is doing well.

**Key Words:** Takayasu's arteritis , Hyperthyroidism, Autoimmune

## INTRODUCTION

Takayasu's arteritis (TA) is an aortoarteritis of unknown aetiology, resulting in segmental stenosis, occlusion, dilatation and aneurysm, which primarily affect the aorta and its branches and occasionally the pulmonary and the coronary arteries. The manifestations can range from asymptomatic to catastrophic, with dizziness, hypertension, claudication, cerebral infarction, chest pain and dyspnoea. The incidence of TA is about 2/10,000 person-years, with a ten-fold predominance in women, especially in those under 40 years of age. The female gender along with the reproductive age group and an Asian origin are the known factors which are associated with a higher disease prevalence [1].

The diagnosis of Takayasu's arteritis is always challenging, as the clinical presentation may vary considerably. Takayasu's arteritis may also mimic idiopathic inflammatory diseases such as Behçet's syndrome, giant cell arteritis and sarcoidosis or infections (e.g. tuberculosis, syphilis). In 1990, the American College of Rheumatology (ACR) suggested a set of criteria for the diagnosis of Takayasu's arteritis. The criteria include (a) age less than 40 years, (b) claudication of an extremity, (c) decreased brachial artery pulse, (d) systolic blood pressure difference of more than 10 mmHg between the left and right arm, (e) a bruit over the subclavian arteries or the aorta and (f) angiographic evidence of the narrowing or occlusion of the aorta or its primary or proximal branches. The presence of three of these six criteria is required for the diagnosis of TA [2].

## CASE REPORT

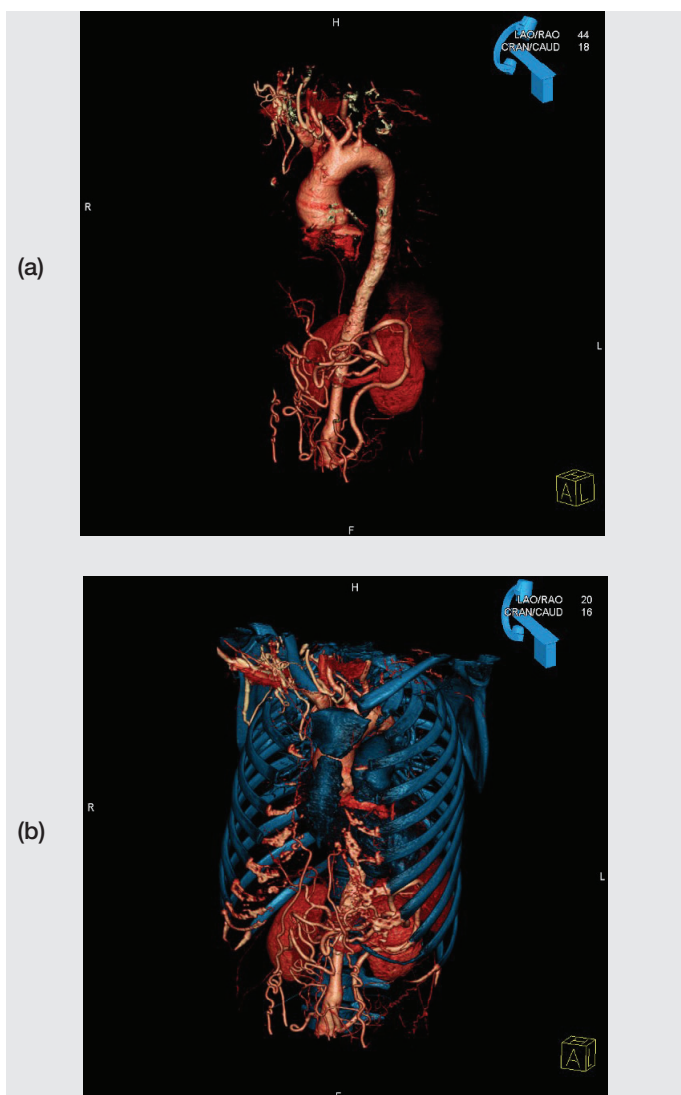
A 30 year female presented to our hospital in January 2009 with gradually progressive breathlessness and generalized fatigability of 15 days duration. There was no history of claudication, chest pain, fever, joint pains or rashes.

On physical examination, she was found to be pale and her blood pressure could not be recorded as the pulses were not felt in both the upper limbs. However, the blood pressure which was recorded in the lower limbs was normal. A carotid bruit was heard. On cardiac examination, she was found to have a left ventricular third heart sound and an early diastolic murmur of aortic regurgitation. Bilateral coarse crackles were heard on the respiratory system examination. Based on the ACR criteria, 1990, our patient has fulfilled five out of the six criteria. The clinical diagnosis of aortic regurgitation with congestive cardiac failure, probably due to Takayasu arteritis was considered.

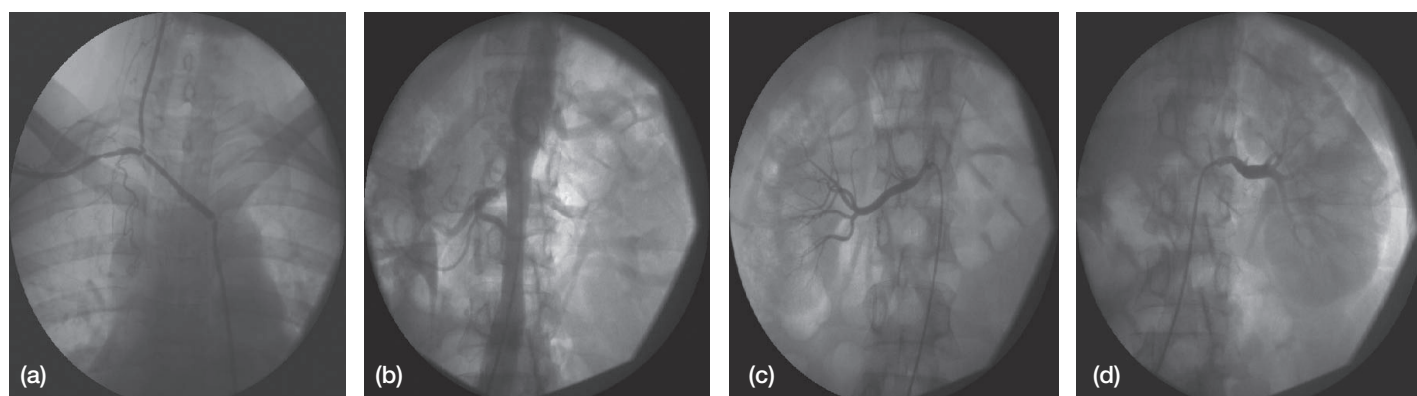
Lab investigations revealed normal blood counts, blood urea, serum creatinine and electrolytes. ESR and the C-reactive protein levels were elevated. The liver function tests and the lipid profile were normal. She was further worked up for vasculitis, which revealed a normal ASO titre, ANA, Antids DNA, ANCA and APLA. The Mantoux test which was done was negative. The chest X-ray revealed pulmonary congestion. The ECG was normal. 2DECHO revealed concentric LVH, moderate aortic regurgitation, LV global hypokinesia and moderate LV dysfunction with EF-43%. Ultrasound of the neck showed diffuse goiter. The thyroid function tests revealed T3- 2.34, T4-19.18 and TSH-0.01. The TPO antibodies were normal and the thyroglobulin antibody levels were elevated (761 U/ml). A sixty four slice MDCT revealed diffuse stenosis of the bilateral subclavian artery, an aberrant right subclavian artery, mild narrowing of the abdominal aorta, narrowing celiac and superior mesenteric arteries and multiple chest wall and intra-abdominal collaterals, which were suggestive of aortoarteritis.

The patient was treated conservatively with diuretics, corticosteroids, antiplatelets and antithyroid drugs. She was under

regular follow up since then and is doing well. Her thyroid functions were monitored regularly. She was admitted to our hospital for the second time in August 2010 with a history of generalised weakness. She was found to have renovascular hypertension. During this admission, an aortogram was done, which showed narrowing of both the subclavian arteries, diffusely narrowed thoracic and abdominal aortas and both the renal arteries. She underwent stenting of both the renal arteries and the right subclavian artery. She was started on anticoagulants, antiplatelets and antihypertensives. She was advised to continue with steroids and the antithyroid drugs.



**[Table/Fig-1a, b]:** CT angios showing bilateral subclavian artery diffuse stenosis, aberrant right subclavian artery, mild narrowing of the abdominal aorta, narrowing celiac and superior mesenteric artery and multiple chest wall and intra-abdominal collaterals.



**[Table/Fig-2a, b, c & d]:** Aortogram pictures showing narrowing of the right subclavian artery, diffusely narrowed abdominal aorta and both the renal arteries.

## DISCUSSION

Takayasu's arteritis is also known as 'pulseless disease', occlusive thromboaropathy and Martorell's syndrome. Takayasu's arteritis is a disease of young, oriental females with probable genetic and infectious strands to the aetiology. There are very few case reports till date of Takayasu's Arteritis in combination with hyperthyroidism. Kattaneh [3] and colleagues published two case reports of hyperthyroidism in patients with Crohn's disease and Takayasu's arteritis. The association of these three diseases could be possibly be explained by the genetic predisposing factors and the disease-related iodine deficiency, both involving the Nuclear Factor kappaB pathway. A similar association was reported by Umh [4] and colleagues who had isolated pulmonary Takayasu's Arteritis which was combined with pulmonary thromboembolism and hyperthyroidism in Korea. Dong RP [5] and his colleagues have studied the close association between the HLA DP antigen and Takayasu's arteritis.

The disease is named after Dr. Mikito Takayasu, who in 1908 described it as a wreathlike appearance of retinal vessels with the absence of radial pulse [6]. Takayasu's arteritis is rare but it is most commonly seen in Japan, South East Asia, India and Mexico and till date, 5000 patients have been registered. Takayasu's arteritis appears to be far commoner in India. Some study groups have shown around 50 new cases annually at a major government hospital in Mumbai [6]. They have postulated tuberculosis as the aetiology in some patients. The four most important complications are Takayasu's retinopathy, secondary hypertension, aortic regurgitation and aneurysm formation [6, 7]. The overall five year survival rate after diagnosis was 83.1% [7].

Takayasu's arteritis has been associated with different human leucocyte antigen (HLA) alleles in different populations<sup>(5)</sup>. The HLA association is thought by some to strengthen the argument in favour of an autoimmune pathogenesis. However, no specific autoantigens have yet been identified. Further research is needed to confirm autoimmunity as the aetiology of this disease.

The survival is better in patients without a progressive course and in those below 35 years of age. Early diagnosis with proper medical or surgical management is essential for a good prognosis.

## REFERENCES

- [1] Nosratinia H, Takayasu Arteritis, *Pak J Med Sci*; July–September 2004;20/ 3:248-250.
- [2] Deshpande J. Non-specific aortoarteritis. *J Postgrad Med* 2000; 46:1.
- [3] Kattaneh A, Prevot S, Biaggi A, Stirnemann J, Fain O, Hocqueloux L, et al., Hyperthyroidism in two patients with Crohn's disease and Takayasu's arteritis. *Scand J Gastroenterol*. 2003 Aug; 38(8):901-3.

- [4] Uhm J S, Kwon J H, Kim T W, Ji J S, Kim J W, Kim S J et al., A Case of Isolated Pulmonary Takayasu's Arteritis Combined with Pulmonary Thromboembolism and Hyperthyroidism. *The Korean Academy of Tuberculosis and Respiratory Diseases*. 2004 August; 57: 188-192.
- [5] Dong RP, Kimura A, Numano F, Yajima M, Hashimoto Y, Kishi Y, Nishimura Y, Sasazuki T. HLA-DP antigen and Takayasu's arteritis. *Tissue Antigens*. 1992 Mar; 39(3):106-10.
- [6] Johnston S L, Lock R J, Gompels M M. Takayasu's arteritis: a review. *J Clin Pathol* 2002; 55:481-486.
- [7] Chau E MC, Wang E, , Chiu C SW, Chow W-, Non-Infectious Aortitis: an Important Cause of Severe Aortic Regurgitation. *Asian Cardiovasc Thorac Ann* 2006; 14:177-182.

**AUTHOR(S):**

1. Dr. Mohammed Ashraf
2. Dr. Sayyid M.K.
3. Dr. Col R. Arunachalam
4. Dr. Anitha Sequeira
5. Dr. Veerendra HK

**PARTICULARS OF CONTRIBUTORS:**

1. Assistant Professor, Department of Medicine  
Fr. Muller Medical College, Mangalore
2. Assistant Professor, Department of Medicine  
Fr. Muller Medical College, Mangalore
3. Professor, Department of Medicine  
Fr. Muller Medical College, Mangalore
4. Post graduate ,Department of Medicine  
Fr. Muller Medical College, Mangalore.
5. Assistant Professor, Department of Medicine  
Fr. Muller Medical College, Mangalore

**NAME, ADDRESS, TELEPHONE, E-MAIL ID OF THE CORRESPONDING AUTHOR:**

Dr. Mohammed Ashraf  
Assistant Professor, Department of Medicine  
Fr. Muller Medical College, Mangalore, India.  
Phone: 9448428974  
E-mail: drashrafmedd@hotmail.com.

**DECLARATION ON COMPETING INTERESTS:**

No competing Interests.

Date of Submission: **Mar 03, 2011**  
Date of Peer Review: **Apr 05, 2011**  
Date of Acceptance: **Apr 05, 2011**  
Online First: **Jun 25, 2011**