

Superficial Brachial Artery with a High Origin of Profunda Brachii and Common Interosseous Artery: A Case Report

RAJAN KUMAR SINGLA, MONIKA LALIT

ABSTRACT

Variations in the arterial pattern of the upper limb are observed frequently and may be seen in routine dissections or in clinical practice. These have important influences on the predisposition to illness, clinical examination, investigations and patient management, including operative surgery. The knowledge of such a variability is however not only desirable, but also essential. In this article, the superficial brachial artery with a high origin of profunda Brachii and the common Interosseous artery is being reported. The axillary artery in its third part gave the profunda

brachii artery and continued as the brachial artery which crossed the median nerve superficially from the medial to the lateral side, in the middle of the arm, as the superficial brachial artery. In the lower one third of the arm, it gave a branch of almost equal calibre, which coursed laterally and continued in the forearm as the common interosseous artery. Then, just at the base of the cubital fossa, it divided into the radial and the ulnar arteries. These arteries may also be mistaken for veins and the results may be disastrous, like gangrene or loss of the hand. Its ontogeny and clinical implications have been discussed in detail.

Key Words: Superficial Brachial Artery, Profunda Brachii Artery, Common Interosseous Artery

INTRODUCTION

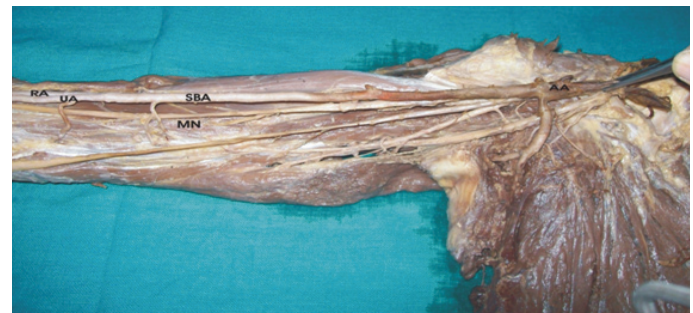The principle arteries of the upper extremity vary widely in their origin and course. Thus, variation is a rule rather than an exception. Some of such variations include a high origin of arteria profunda brachii from the axillary artery instead of the brachial artery and the superficial brachial artery where the brachial artery crosses the median nerve superficially from the medial to the lateral side or the high origin of the radial or the ulnar arteries. One such case was found in the Department of Anatomy, Govt. Medical College, Amritsar, Punjab, India, where multiple vascular anomalies were seen in the same limb and the same is being reported here.

CASE REPORT

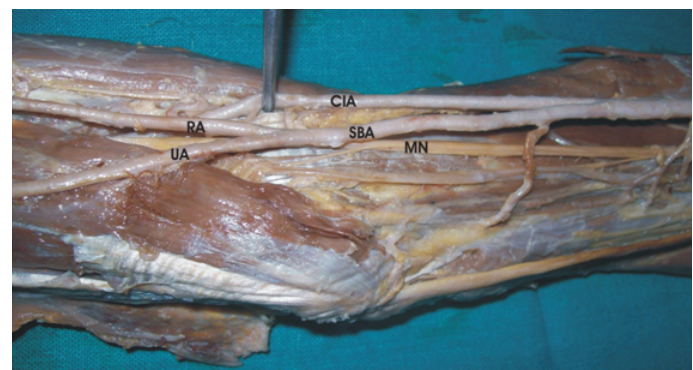
In the right upper limb of a 60 year old male cadaver, the axillary artery in its third part gave the profunda brachii artery and continued as the brachial artery. The former entered the radial groove along with the radial nerve, whereas the later crossed the median nerve superficially from the medial to the lateral side in the middle of the arm as the superficial brachial artery. In its course in the arm, it gave muscular branches to the muscles of the arm. About 9 cm proximal to the intercondylar line, it gave a branch which continued laterally and distally in the forearm as the common interosseous artery. Then, just at the base of the cubital fossa, it bifurcated into the radial and the ulnar arteries. The radial artery coursed normally, while the ulnar artery crossed the common flexor origin of the forearm muscles superficially to reach its destination between the flexor carpi ulnaris and the flexor digitorum superficialis. [Table/Fig-1 & 2]

DISCUSSION

The superficial brachial artery is so called because it runs superficial to the median nerve, whereas usually the brachial artery runs deep to the median nerve. The superficial brachial artery may replace the main trunk as was seen in the present case, or it may be accompanied by an equally important, less important or



[Table/Fig-1]: Showing Axillary Artery continuing as superficial brachial Artery



[Table/Fig-2]: Showing superficial brachial artery giving common interosseous artery and itself dividing into radial and ulnar arteries

more important trunk running parallel and deep into the median nerve in the normal position [1]. These superficial brachial arteries may continue in the cubital fossa and bifurcate as usual into the radial and the ulnar arteries, both the radial and the ulnar arteries running a superficial course in the forearm [2], with the deep division continuing in the forearm as the Interosseous complex [3]. Another type of variant is also seen, where the brachial artery gives a superficial branch in the arm, which continues in the forearm as

the common interosseous artery, while the brachial artery divides into the radial and the ulnar arteries at the normal position [4]. Our case was partially so, in that the common interosseous artery came from the superficial brachial artery, about 9 cm proximal to the intercondylar line. However, there was no deep component and the superficial brachial artery itself terminated into the radial and the ulnar arteries, both running a superficial course in the forearm.

The incidence of the superficial brachial artery is reported to vary between 0.2 and 19.7% (see [Table/Fig-3])

Manners Smith [16] opined that many of the variations which are noted in man, represent a retention or the reappearance of primitive patterns and this is in consonance with the view that ontogeny repeats phylogeny. Arey [16] [17] is of view that the anomalous blood vessels may be due to any of the following:

1. The choice of unusual paths in the primitive vascular plexuses
2. The persistence of vessels which are normally obliterated
3. The disappearance of vessels which are normally retained
4. Incomplete development
5. Fusions and absorption of the parts which are usually distinct

Ontogeny of the superficial brachial artery was first described by Senior in 1926 [18] and this was later on modified by Baeza et al in 1995 [15]. According to Baeza et al [15], the arteries of the upper limb develop as follows: [See Table/Fig-4]

- The superficial brachial artery is a consistent embryonic vessel that plays an important role in the normal arterial morphogenesis of the upper limb.
- The superficial brachial artery has two terminal branches, a medial one which is a superficial antebrachial artery and a lateral one which continues in the forearm as a part of the definitive radial artery [7],[19].
- The superficial antebrachial artery divides into two terminal branches- the median and the ulnar arteries [7],[18],[19]. Each of these branches anastomoses with a corresponding branch of the primitive axial artery, which are trunks in the origin of the median and the ulnar arteries respectively. Gradually, the trunks of deep origin attain a haemodynamic predominance and the superficial antebrachial artery, together with a preanastomotic segment of its terminal branch, retrogresses. Therefore, two segments can be distinguished in both the median and the ulnar arteries; a proximal or deep one which corresponds to the trunks of origin in the primitive axial artery and another distal or superficial one which represents the postanastomotic segment of the terminal branch of the superficial antebrachial artery.

Sl. No.	Name of Author	Year	Percentage
1.	Quains [5]	1844	0.2
2.	Gruber [6]	1848	0.4
3.	Muller [7]	1903	1.0
4.	Degarís and Swartley [8]	1928	9.0
5.	Miller [9]	1939	3.0
6.	Treves and Rogers [4]	1947	15.0
7.	Mc Cormack et al [10]	1953	5.75
8.	Skopakoff [11]	1959	19.7
9.	Lanz and Wachsmuth [12]	1959	25.0
10.	Keen [2]	1961	12.3 or 3.6
11.	Fuss et al [13]	1985	17.0
12.	Lippert and Pabst [14]	1985	22.0
13.	Baeza et al [15]	1995	11.9
14.	Present Case	2010	Single Case

[Table/Fig-3]: Incidence of Superficial Brachial Artery

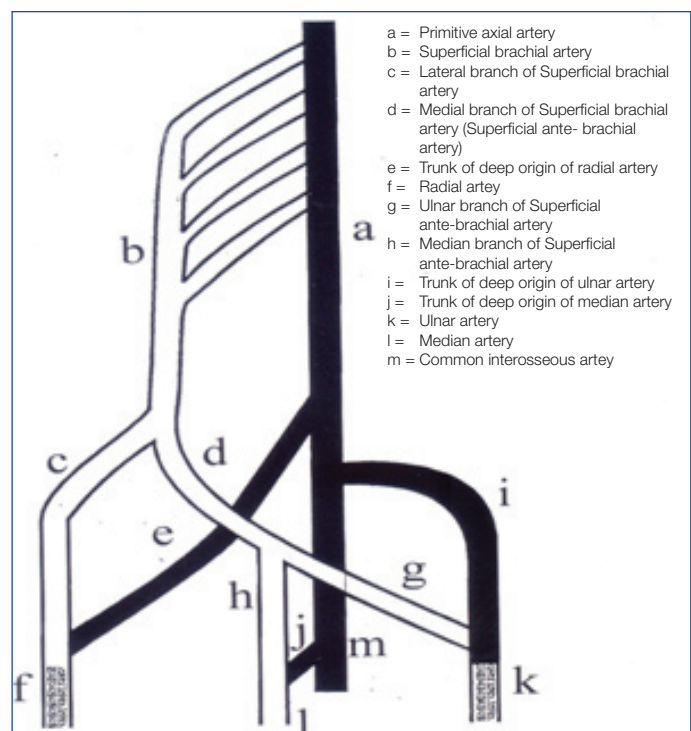
- The radial artery usually develops in a similar way as the median and the ulnar arteries. Thus, the lateral terminal branch of the superficial brachial artery anastomoses with a trunk for a deep origin of the radial artery in the primitive axial artery. A deep, haemodynamic predominance determines the regression of those superficial arterial segments which are located proximal to the anastomosis, while the distal segments persist as a part of the radial artery. This statement is in agreement with that which was given by Senior and Singer [18],[20]. However, they defined the superficial branch of the anastomosis as the proper superficial brachial artery and not as its lateral, terminal branch. This difference may be justified by the fact that once the anastomosis between the trunk for the deep origin of the radial artery and the lateral branch of the superficial brachial artery is made, the definitive patterns of the median and ulnar arteries have already been established [18], [20].

This explanation stands a good stead as far as the origin of the radial and the ulnar arteries from the superficial brachial artery are concerned. However, an origin of the common interosseous artery from the superficial brachial artery can not be explained on the basis of this. For this, a slight modification in Baeza et al's [15] model of development of the human brachio antebrachial system is recommended as follows [See Table/Fig-5]:

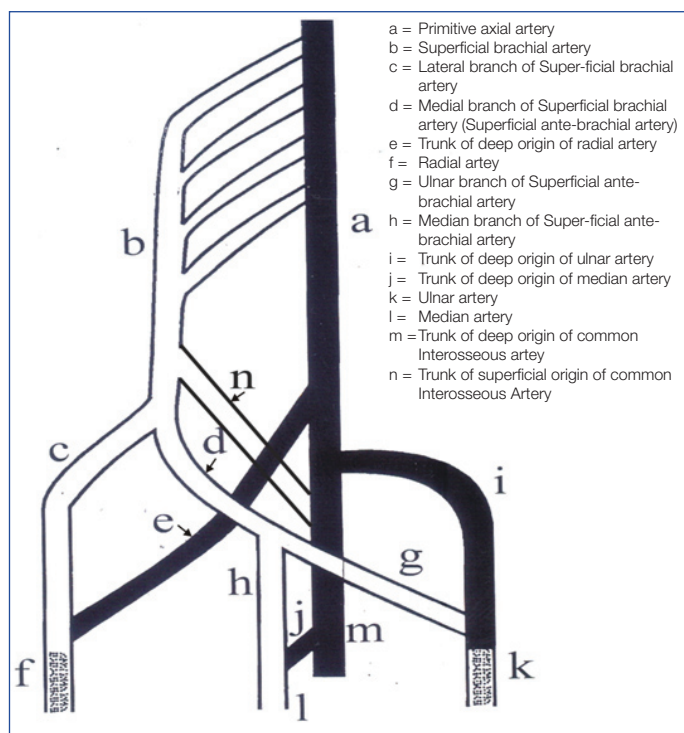
The superficial brachial artery, before dividing into its two terminal branches (Stage II of Baeza et al ,1995), gives a branch (n in Fig II) which joins the axial artery, distal to the origin of the deep component of the radial and the ulnar arteries. Usually, this component also disappears, as the haemodynamic preference goes for the deep component of the axial artery. But in the present case, this component persisted and the deep component disappeared, leading to an origin of the common interosseous artery from the superficial brachial artery.

CLINICAL SIGNIFICANCE

The presence of the large, common interosseous artery provides enough blood supply to the upper limb to prevent any ischaemia in



[Table/Fig-4]: Baeza et al 1995, modifications in development of Human Brachio antebrachial system



[Table/Fig-5]: Development of Superficial Brachial Artery as in the present case

an event of occlusion of the superficial brachial artery. The superficial brachial artery, as well as the superficial position of the ulnar and the radial arteries not only makes them more vulnerable to trauma and thus to bleeding, but also makes them more accessible to cannulation, if needed. These arteries may also be mistaken for a vein. If certain drugs are injected into these vessels, the results may be disastrous, like gangrene or loss of the hand [21]. Moreover, if the superficial brachial artery is retained, it is usually associated with a retarded development of the palmar arch [22],[23],[24].

REFERENCES

- Adachi B. Arteriensystem des japaner. Kyoto 1928; 1: 205-210. Cited by Keen JA. A study of arterial variations in limbs with special reference to symmetry of vascular patterns. *Am J Anat.* 1961; 108 : 245-261.
- Keen JA. A study of arterial variations in limbs with special reference to symmetry of vascular patterns. *Am J Anat* 1961; 108: 245-261.
- Vare A M and Bansal P C. A case of anomalous brachial artery and other associated vascular anomalies in a single upper limb. *J Anat Soc Ind* 1969; 18(2): 50-53.
- Treves FB and Rogers L. Surgical applied Anatomy. In: *The upper limb.* 11th Ed. London, Toronto, Melbourne and Sydney: Cassell & Co Ltd.; 1947: 230-231, 247, 265-266.
- Quains. The Anatomy of Arteries of Human Body. London: Taylor and Walton; 1844. Cited by McCormack L J et al. Brachial and antebrachial arterial patterns. *Surg Gynaecol Obstet* 1953; 96: 43-54.
- Gruber W. 1848. Cited by McCormack L J et al. Brachial and antebrachial arterial patterns. *Surg Gynaecol Obstet* 1953; 96: 43-54.
- Muller. Die Arm – Arteries des Menschen Anat Hefte 1903; 22: 379. Cited by Keibel F and Mall F.P. Manual of human embryology. In: *Development of blood vascular system – The Arteries.* Edited by Minot C.S; Evans H.M; Tandler J and Sabin F.R. 1st Edition. J.B Lippincot Co., Philadelphia and London; 1912: 659-667.
- DeGaris CF and Swartley WB. The axillary artery in white and negro stocks. *Am J Anat* 1928; 41: 353-397.
- Miller RA. Observations upon the arrangement of axillary artery and brachial plexus. *Am J Anat* 1939; 64: 143-163.
- McCormack LJ, Cauldwell EW and Anson BJ. Brachial and antebrachial arterial patterns. *Surg Gynaecol Obstet* 1953; 96: 43-54.
- Skopakoff C. Ober die variabilitat der ab und Verzweigung der A brachialis superficialis. *Anat Anz* 1959; 106: 356-368. Cited by Keen JA. A study of arterial variations in limbs with special reference to symmetry of vascular patterns. *Am J Anat* 1961; 108: 245-261.
- Lanz T and Wachsmuth W. Praktische Anatomie Arm Springer Berlin 1959; 1(3): 124-125. Cited by Baeza et al. An Anatomical study and ontogenic explanation of 23 cases with variations in main pattern of brachio antebrachial arteries. *J Anat* 1995; 187(2): 473-479.
- Fuss FK, Matula CHW, Tschabhscher M. Die Arteria brachialis superficialis. *Anat Anz* 1985; 160: 285-294. Cited by Baeza et al. An Anatomical study and ontogenic explanation of 23 cases with variations in main pattern of brachio antebrachial arteries. *J Anat* 1995; 187(2): 473-479.
- Lippert H and Pabst R. Arterial variations in man, Springer, New York 1985: 68-73. Cited by Baeza et al. An Anatomical study and ontogenic explanation of 23 cases with variations in main pattern of brachio antebrachial arteries. *J Anat* 1995; 187(2): 473-479.
- Baeza R.A, Nebot J, Ferreira B, Reina F, Perez J, Saundo J.R . et al. An Anatomical study and ontogenic explanation of 23 cases with variations in main pattern of brachio antebrachial arteries. *J Anat* 1995; 187(2): 473-479.
- Manners Smith T. The limb arteries of primates. *J Anat Physiol* 1910; 45: 23-64.
- Arey L.B. Developmental Anatomy. In: *Development of the arteries.* 6th Edition. W.B Saunders Co, Philadelphia; 1957: 375-377.
- Senior H.D. A note on development of radial artery. *Anat Rec* 1926; 32: 220.
- Vancov V. Une variete extremement complexe des arteres du membre superieur chez un foetus humain. *Anat Anz* 1961; 109: 400-404. Cited by Baeza et al. An Anatomical study and ontogenic explanation of 23 cases with variations in main pattern of brachio antebrachial arteries. *J Anat* 1995; 187(2): 473-479.
- Singer E. Embryological patterns persisting in arteries of the arm. *Anat Rec* 1933; 55: 406-413.
- Jurjus A, Sfeir R and Bezirdjian R. Unusual variation of arterial pattern of the human upper limb. *Anat Rec* 1986; 215: 82-83.
- Breme G. Kasuistischer Beitrag zur kenntnis der Anomalien der Armarterien. *Zschr.f.Morph.u.Anthrop.* Bd.1. S 1899; 1: 483-494. Cited by Singer E. Embryological patterns persisting in arteries of the arm. *Anat Rec* 1933; 55: 406-413.
- Dubreuil-Chambradrel L. L'Artere mediane. *Gazette Medieale du centre.* 1906. Cited by Singer E. Embryological patterns persisting in arteries of the arm. *Anat Rec* 1933; 55: 406-413.
- Schwalbe E. Beitrag zur kenntnis der arterien vrietaten des menschlichen armes. *Morph Arbeiten* V.G. Schwalbe 1898; 8: 1-47. Cited by Singer E. Embryological patterns persisting in arteries of the arm. *Anat Rec* 1933; 55: 406-413.

AUTHOR(S):

- Dr. Rajan Kumar Singla
- Dr. Monika Lalit

NAME OF DEPARTMENT(S)/INSTITUTION(S) TO WHICH THE WORK IS ATTRIBUTED:

- Department of Anatomy, Government Medical College Amritsar-143001, Punjab, India.
- Department of Anatomy, Chintpurni Medical College Pathankot, Punjab, India.

NAME, ADDRESS, TELEPHONE, E-MAIL ID OF THE CORRESPONDING AUTHOR:

Dr. Monika Lalit
24, Lane-5, Gopal Nagar, Majitha Road
Amritsar-143001, Punjab, INDIA
E-mail: monika.lalit@yahoo.com

DECLARATION ON COMPETING INTERESTS:

No competing Interests.

Date of Submission: **Jan 15, 2011**
Date of Peer Review: **Mar 30, 2011**
Date of Acceptance: **Mar 30, 2011**
Date of Publishing: **Jun 13, 2011**