

# A Rare Variation of Left Testicular Arteries in Position, Number and Course and its Clinical Significance

XIANGYANG ZANG<sup>1</sup>, JIANJUN MA<sup>2</sup>, WEIQIANG JIN<sup>3</sup>, YU QIAN<sup>4</sup>, MAN DONG<sup>5</sup>



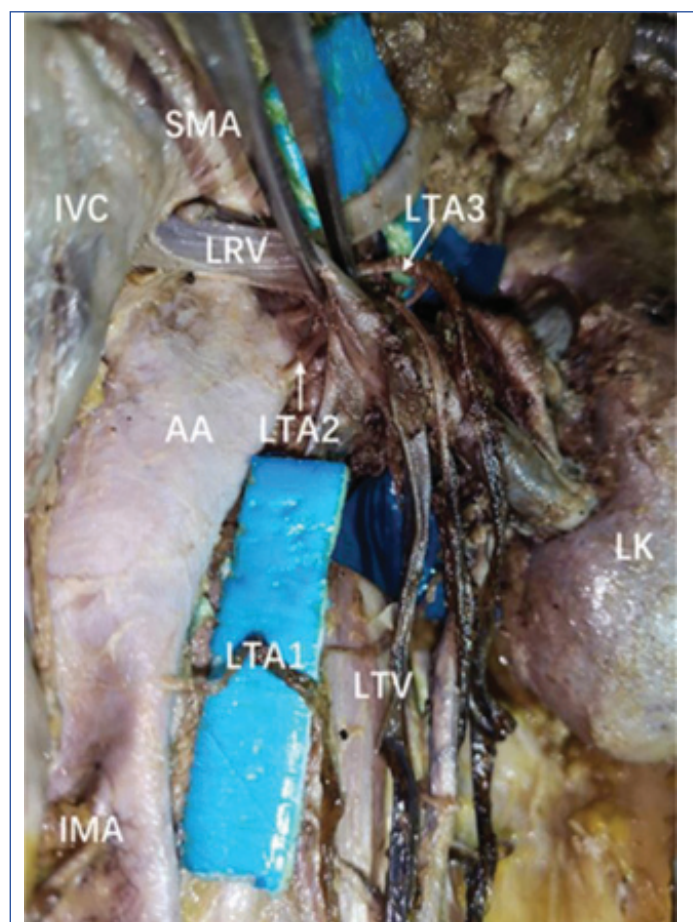
## ABSTRACT

Variations of gonadal vessels are frequently reported. A comprehensive awareness of the morphologic variations of testicular vessels can avoid accidental injuries to the vessels during surgery. In the present case, there were three left testicular arteries existing in ipsilateral side. Especially, two left testicular arteries originated from the abdominal aorta, arched over and then descended in front of the left renal vein. Besides, another left testicular artery had a low origin but was a little superior to the inferior mesenteric artery. Such a variation is significant and may be attributed to the pathogeny of varicocele and orthostatic proteinuria. The variation could show surgeons an ingenious idea and may educate surgeons to consider more potential hazards during abdominal surgery.

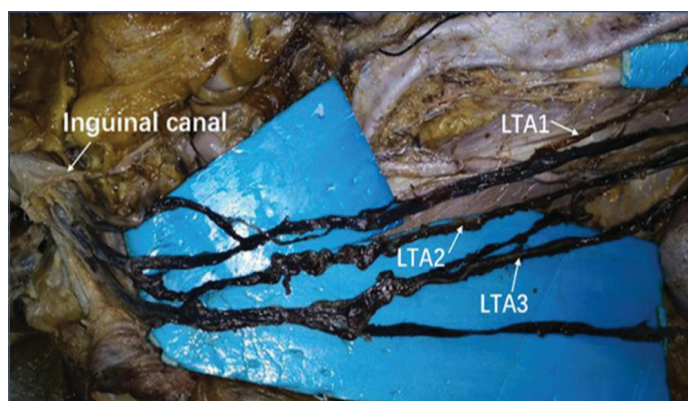
**Keywords:** Anatomical variation, Classification-diagnosis-surgery, Embryology

## CASE REPORT

During routine cadaveric dissection, a 60-year-old male cadaver was found to have an anatomical variation in testicular artery. These testicular arteries, originated from lateral border on the abdominal aorta [Table/Fig-1,2]. The lowest Left Testicular Artery (LTA1) was near the inferior mesenteric artery. The additional two (LTAs) were respectively described as lower (LTA2) and upper (LTA3) according to the relationship of mutual position.



**[Table/Fig-1]:** Dissection of the abdomen showing three left testicular arteries: one left testicular artery (LTA1) had a low origin and two left testicular arteries (LTA2, LTA3) arched around the left renal vein (LRV).  
SMA: Superior mesenteric artery; IVC: inferior vena cava; AA: Abdominal aorta; LTV: Left testicular vein; LK: left kidney; IMA: Inferior mesenteric artery



**[Table/Fig-2]:** Dissection of the abdomen showing three left testicular arteries: one left testicular artery (LTA1) had a low origin and two left testicular arteries (LTA2, LTA3).

The LTA1 left the point of origin and descended accompanying with Left Testicular Vein (LTV) into the left testis. Both LTA2 and LTA3 originated from the anterolateral aspect of the abdominal aorta and ascended behind the Left Renal Vein (LRV). Where after, the LTA2 and LTA3 arched over the LRV and then ran downward along the surface of the LRV, and finally reached the left testis. The course of LTA2 was to the right of LTA3.

It was also noticed that the superior mesenteric artery made a smaller acute angle with the abdominal artery, putting compression on the LRV. It appeared that the two arched LTAs assisted the superior mesenteric artery in compressing the LRV.

## DISCUSSION

### Embryology

Normally, the testicular artery descends over the ureter and the external iliac artery and then reaches the inguinal canal. Along the way of inguinal canal, it finally travels to the scrotum and tortuously divides into several branches there. Though the testicular artery in this article complies with the above course, some abnormal variations still exist and are related to their embryological origin.

Any abnormal embryological development will lead to the occurrence of variation of testicular artery in number and course. Initially, almost 30 mesonephric arteries on each side supply structures of the dorsal body wall in embryonic period. With some arteries regressing, finally nine lateral mesonephric arteries exist and are divided into the cranial group, middle group and caudal group. The caudal group

tends to develop into the testicular artery among three groups and others will disappear [1]. But if other mesonephric arteries fail to regress, multiple testicular arteries will appear, just like three LTAs in this case. In the present case, two LTAs arched over and then descended along the LRV.

The reason of the variation can be found from embryology: if the testicular artery was persistently in cranial position of middle group, it would cross in front of the group during testis descent; if the kidney ran up and reached a higher site than that of testicular artery, the latter would make a loop over the LRV [2]. Interestingly, the appearance of a high-originated testicular artery might come from a perpetual cranial mesonephric artery; however, in the index case, the low origin of testicular artery might be the result of a perpetual mesonephric artery from caudal arteries [3].

### Variant Types of Testicular Artery

Variations of testicular artery in origin, number or course can be numerous. The variant incidence of testicular artery on the left side (242/1167, 20.73%) is more than that on the right side (156/1229, 12.69%); the incidence of double testicular arteries on the left side (25/1167, 2.14%) is more than that on the right side (14/1229, 1.19%); similarly the incidence of arching testicular artery is respectively 141/1167 (12.08%) and 65/1229 (5.28%) [4].

Some researchers grouped these arteries based on which the testicular arteries originate from as four types: type I, directly from the abdominal aorta; type II, from the renal artery and its branches; type III, from the middle suprarenal artery; type IV, from less low origin on the abdominal aorta and arch over the renal vein [2]. The double testicular arteries of each side appear in most cases. Lippert and Pabst proposed a classification including three types based on the course and origin of testicular arteries [5]. Coincidentally, among one of the three types, all testicular arteries originate from the abdominal aorta and three testicular arteries account for <1% on each side. Under normal circumstances, the testicular artery descends directly after originating from the abdominal aorta. However, at times, it can ascend behind the renal vein, arch over and run down it, which is called the arching artery of Luschka [6].

Notkovich H [7] classified variations based on the relationship of testicular artery to renal vein into three types: type I, the testicular artery from its original site descends neatly without any disturbance with the renal vein; type II, the testicular artery from a higher original site compared to the renal vein descends and then crosses over the vein; type III, the testicular artery ascends from the abdominal aorta, lower than the renal vein and arches over it. The variation in the index case simultaneously comprised two arching LTAs among three LTAs. In most cases, the level of testicular artery origin accords with the second lumbar vertebrae, just below the LRV. The testicular arteries belong to high origin if emerging above this normal level, but belong to low origin if emerging below this normal level. Apparently, the first (LTA1) is considered as a low origin.

### Clinical Significance

The testis and kidney are important as urogenital system. We observed that the two arching LTAs compress LRV at the site to the left confluence of the LTV. The "nutcracker syndrome" is a phenomenon that cooperative compression of the superior mesenteric artery and the abdominal aorta resulted in left renal vein hypertension [8]. To the best of our knowledge, renal vein hypertension can lead to several clinical symptoms such as varicocele, haematuria and orthostatic proteinuria [2,9,10]. The symptoms also can result from the arching LTA which can be viewed as a driving force to increase LRV pressure. In the present case, the two arching LTAs seemingly put severe compression on the LRV

resulting in retreating blood flow from the LRV to the LTV. When venous blood in the LTV can't successfully drain, the left testis may be poisoned because of the metabolite silted in the vein.

Existence of some rare anatomical aberrations lead to the requirement of advanced diagnostic and surgical techniques. Comprehensive awareness regarding this variation of testicular artery could help avoid complications in surgical procedures. During colorectal surgery, the gonadal artery seems easier to get iatrogenic injuries (3.61%) compared with ureteral and bladder injuries respectively in 0.28-0.44% and <1% [11-13]. Any surgeries involving kidney, such as renal transplantation, renal resection, or renal vessels should consider the arching testicular arteries and protect these arteries from accidental damage. Also, incomplete ligation of these arteries while involving multiple testicular arteries could result in hemorrhage and other emergencies. Another variation of testicular artery which we found is low origin differing from the high origin of testicular artery which is widely reported before [4]. The low origin may cause accidental injuries during hypogastric operation.

Testicular angiogram can help radiologists ascertain problems of patients with scrotal disease, such as hydrocele, testicular torsion, haematoma, and epididymitis [14]. Radiologists and diagnosticians must have a thorough knowledge of possible variations of testicular vessels in case of misunderstanding about testicular angiogram. After reviewing some published literatures, the present case could be regarded as a rare variation of testicular vessel.

### CONCLUSION(S)

Both left and right testicular arteries in the article had the normal termination reaching to ambilateral inguinal canal. However, three left testicular arteries showed a rare variation in position, number and course. The article introduces their variation and emphasised clinical significance which might have positive affect to urological physiology and surgery.

### REFERENCES

- [1] Padur AA, Kumar N. Unique variation of the left testicular artery passing through a vascular hiatus in renal vein. *Anat Cell Biol.* 2019;52(1):105-07.
- [2] Kayalvizhi I, Narayan RK, Kumar P. Anatomical variations of testicular artery: A review. *Folia Morphol. (Warsz)*. 2017;76(4):541-50.
- [3] Badagabettu SN, Shantakumar SR, Shetty SD, Prabhu G. Bilateral low origin of testicular artery: A case report. *J Vasc Bras.* 2017;16(3):258-61.
- [4] Henry BM, Tomaszewsk KA, Ramakrishnan PK, Roy J, Vikse J, Loukas M, et al. Development of the Anatomical Quality Assessment (AQUA) Tool for the quality assessment of anatomical studies included in meta-analyses and systematic reviews. *Clin Anat.* 2017;30(1):06-13.
- [5] Lippert H, Pabst R. *Arterial Variations in Man: Classification and Frequency.* Munich: J F Bergman Verlag. 1985;121.
- [6] Gupta A, Singal R, Singh D. Variations of gonadal artery: Embryological basis and clinical significance. *Int J Biol Med Res.* 2011;2(4):1006-10.
- [7] Notkovich H. Variations of the testicular and ovarian arteries in relation to the renal pedicle. *Surg Gynecol Obstet.* 1956;103:487-495
- [8] Chau AH, Abdul-Muhsin H, Peng X, Davila VJ, Castle EP, Money SR. Robotic-assisted left renal vein transposition as a novel surgical technique for the treatment of renal nutcracker syndrome. *J Vasc Surg Cases Innov Tech.* 2018;4(1):31-34.
- [9] Kim SH. Doppler US and CT diagnosis of nutcracker syndrome. *Korean J Radiol.* 2019;20(12):1627-37.
- [10] Nathan H. Observations on aberrant renal arteries curving around and compressing the renal vein; possible relationship to orthostatic proteinuria and to orthostatic hypertension. *Circulation.* 1958;18(6):1131-34.
- [11] Andersen P, Andersen LM, Lversen LH. Iatrogenic ureteral injury in colorectal cancer surgery: A nationwide study comparing laparoscopic and open approaches. *Surg Endosc.* 2015;29(6):1406-12.
- [12] Halabi WJ, Jafari MD, Nguyen VQ, Carmichael JC, Mills S, Pigazzi A, et al. Ureteral injuries in colorectal surgery: An analysis of trends, outcomes, and risk factors over a 10-year period in the United States. *Dis. Colon Rectum.* 2014;57(2):179-86.
- [13] Hsu CW, Chang MC, Wang JH, Wu CC, Chen YH. Incidence and clinical outcomes of gonadal artery injury during colorectal surgery in male patients. *J. Gastrointest. Surg.* 2019;23(10):2075-80.
- [14] Nordmark L, Nyberg G. Angiography of the testicular artery. IV. Magnification angiography in intrascrotal abnormalities. *Acta Radiol Diagn.* 1979;20(2):353-68.

**PARTICULARS OF CONTRIBUTORS:**

1. Undergraduate, Human Anatomy Laboratory, First Clinical College, Xinxiang Medical University, China.
2. Professor, Human Anatomy Laboratory, School of Basic Medicine, Xinxiang Medical University, China.
3. Undergraduate, Human Anatomy Laboratory, First Clinical College, Xinxiang Medical University, China.
4. Postgraduate, Tianjin Neurological Institute, Neurology, Key Laboratory of Post Neurotrauma Neurorepair and Regeneration in Central Nervous System, Ministry of Education and Tianjin City, China.
5. Resident Physician, Department of Medicine, The Third Affiliated Hospital of Xinxiang Medical University, China.

**NAME, ADDRESS, E-MAIL ID OF THE CORRESPONDING AUTHOR:**

Man Dong,  
Department of Medicine, The Third Affiliated Hospital of  
Xinxiang Medical University, China.  
E-mail: 853798958@qq.com

**PLAGIARISM CHECKING METHODS:** [\[Jain H et al.\]](#)

- Plagiarism X-checker: Dec 31, 2019
- Manual Googling: Jan 22, 2020
- iThenticate Software: Jan 28, 2020 (7%)

**ETYMOLOGY:** Author Origin**AUTHOR DECLARATION:**

- Financial or Other Competing Interests: No
- Was informed consent obtained from the subjects involved in the study? Yes
- For any images presented appropriate consent has been obtained from the subjects. Yes

Date of Submission: **Dec 28, 2019**Date of Peer Review: **Jan 15, 2020**Date of Acceptance: **Jan 22, 2020**Date of Publishing: **Feb 01, 2020**