

## JOURNAL OF CLINICAL AND DIAGNOSTIC RESEARCH

How to cite this article;

BANSAL S,SINGHLA R:MISDIAGNOSIS IN EXODONTIA-OUR EXPERIENCE. Journal of Clinical and Diagnostic Research [serial online] 2010 December [cited: 2010 December 20]; 4:3664-3669.

Available from

[http://www.jcdr.in/article\\_fulltext.asp?issn=0973-](http://www.jcdr.in/article_fulltext.asp?issn=0973-709x&year=2010&volume=4&issue=6&page=3664-3669&issn=0973-709x&id=1103)

[709x&year=2010&volume=4&issue=6&page=3664-3669&issn=0973-709x&id=1103](http://www.jcdr.in/article_fulltext.asp?issn=0973-709x&year=2010&volume=4&issue=6&page=3664-3669&issn=0973-709x&id=1103)

## CASE REPORT

### Misdiagnosis In Exodontia-Our Experience

SHALLU BANSAL\* , RAJESH SINGHLA\*\*

#### ABSTRACT

Exodontia is a common dental procedure which is routinely dispensed in our practice. Although the extraction of the tooth has become, in most of the cases, the last resort of treatment, dentists often consider tooth extraction as a minor and unimportant procedure. Sometimes dental surgeons attempt extraction without doing proper diagnosis, hoping that all will go well, but it can become an expensive lesson in 'chasing without catching'.

This paper is designed for general dental practitioners who desire to improve and want to obtain a wide variety of practical clinical information. In this paper, we are presenting the cases which are misdiagnosed and are negligently handled by the local dental practitioners.

**Keywords:** *exodontia, misdiagnosis, extraction*

\*Assistant professor, Department of oral & maxillofacial surgery, Surendera dental college and research institute .

\*\* professor, Department of oral & maxillofacial surgery Surendera dental college and research institute .

Address for correspondence:

Dr. Bansal shallu. Mds,  
H. H. Garden, power house road,  
Sriganganagar-335001  
Rajasthan, india  
Ph: +91-9414343004  
Fax: +91-154-2440102  
Email: drshallu23@yahoo.com

#### INTRODUCTION

Misdiagnosis in exodontia can and does occur at a reasonable rate in our day to day practice. Definite diagnosis is the most essential part of the treatment. The most fascinating thing about the diagnosis is that it can be like solving a Sherlock Holmes detective mystery; the evidence of the disease is obvious, but the clues to the actual causes are so subtle that they may be overlooked, so that any mobile tooth should not be underestimated as they can be having some underlying pathology. It is prudent to confirm a diagnosis via methods such as taking a proper history and by seeking a second opinion. According to Geoffrey. L. Howe, "The ideal tooth extraction is the painless removal of the whole tooth or the tooth root with minimal

trauma to the investigating tissue, so that the wound heals uneventfully and no post operative prosthetic problem is created." [1]

The dental surgeon should endeavour to make every tooth extraction that he performs, an ideal one. Before undertaking the extraction of the tooth, one should thoroughly evaluate the problems which are involved. [2]

The dental practitioner must conduct a thorough clinical and radiological examination the particular areas that are affected. Here, we are presenting a few cases reports where a misdiagnosis was made in the routinely dispensed exodontia procedure. The purpose of this paper is to demonstrate that good clinical judgment prevails before recommending any excessively heretic treatment plan. It is a simple attempt to add to the contemporary knowledge of the ideal treatment of this kind of routinely done minor dental procedures.

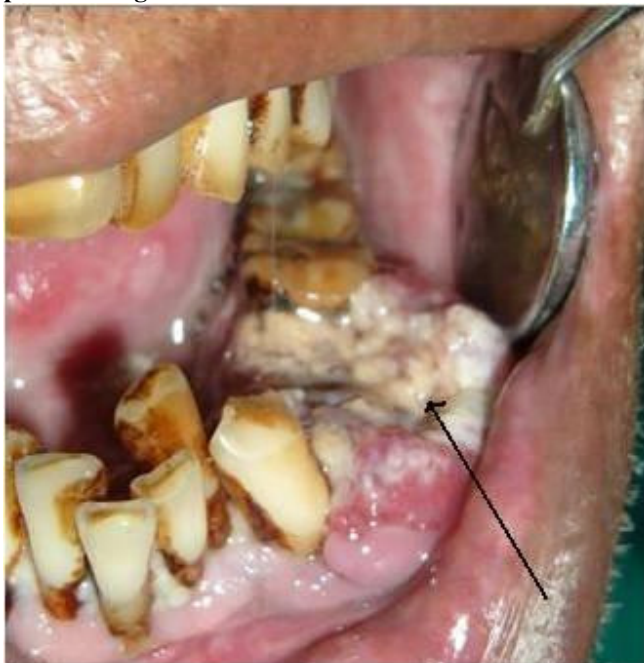#### CASE REPORTS

##### Case 1

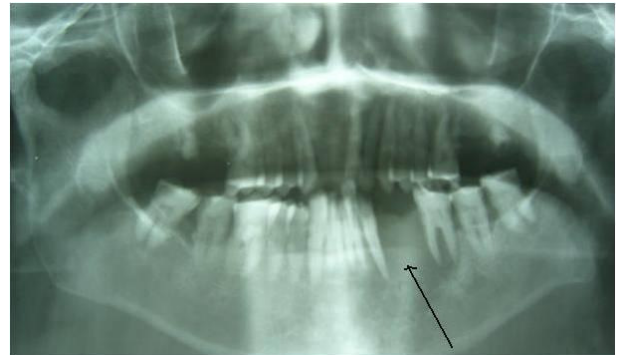
A 62 years old male reported with a complaint of ulcer in his left lower back tooth region since 15 days [Table/Fig1]. His past dental history revealed the extraction of the painful and mobile

left lower premolars; 15 days back. His detailed history revealed that he had mobility and pain in that particular area since one month. His personal history was suggestive that he was a bidi smoker and a chronic alcoholic. On clinical examination, it was found that there was an ulcerative growth (appx. 1.5 x 1cm) extending from 33 to 36. The ipsilateral submandibular lymph nodes were palpable and tender, but not fixed. The OPG [Table/Fig2] showed a diffuse radiolucency with respect to 34 and 35. The medical history was unremarkable. A provisional diagnosis of CA alveolus was made and an incisional biopsy was performed, which confirmed moderately differentiated squamous cell carcinoma. The patient was then operated for segmental resection and supraomohyoid neck dissection and is under follow up.

**[Table/Fig 1]: Intraoral view showing the ulcerative growth in relation to the left lower posterior region**



**[Table/Fig 2]: OPG showing the diffuse radiolucency with respect to 33,34,35,36.**

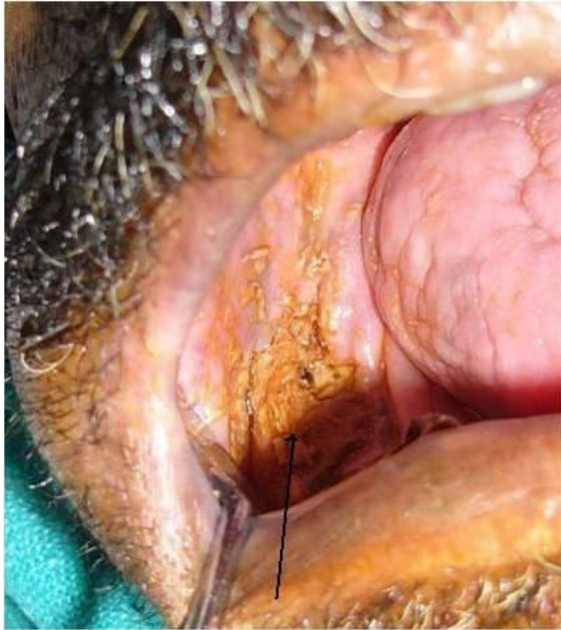

### Case 2

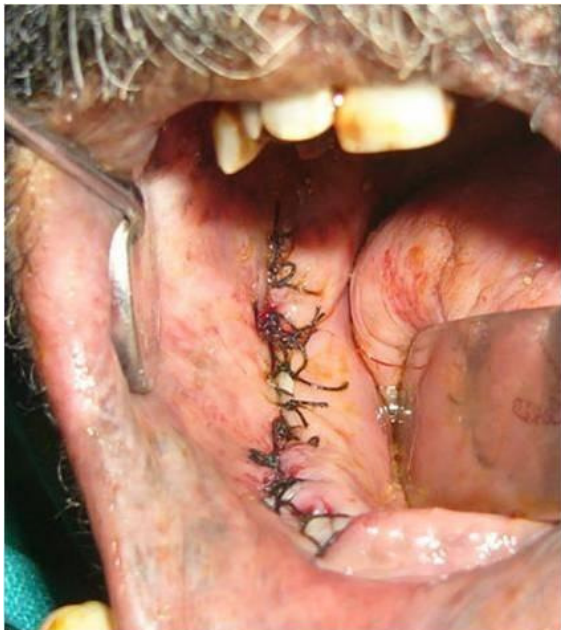A 48 years old male patient was referred by a local dental practitioner for an unhealing wound after extraction in the right lower back tooth region. [Table/Fig 3] The patient gave a history of extraction with respect to that area app. 30-40 days back, due to the mobility of the tooth and difficulty in chewing in that particular region. He was being treated for dry socket. His detailed medical history revealed that he was diagnosed to have carcinoma of the larynx one year back and was treated with radiotherapy for the same. The last dose of radiation was given 5 months back.

On clinical examination, it was found that there was a necrotic bone in relation to 46, 47 and 48. A provisional diagnosis of osteoradionecrosis was made. A radiographical examination was done and the patient was explained about the condition. After getting the general physician's consent, a gentle curettage of the necrotic mass was done under antibiotic coverage and with thorough irrigation [Table/Fig 4]. At six months of follow up, it was observed that there was no recurrence [Table/Fig 5].

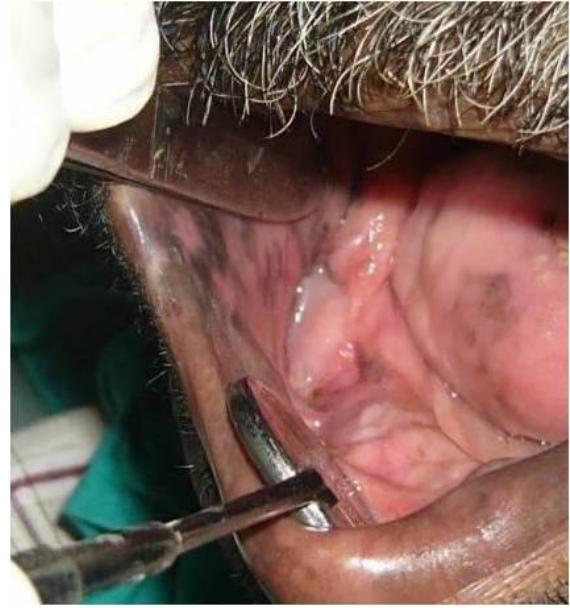**[Table/Fig 3]: Intraoral view showing necrosed bone with respect to the right lower posteriors**



[Table/Fig a4]: Postoperative view of the closed wound



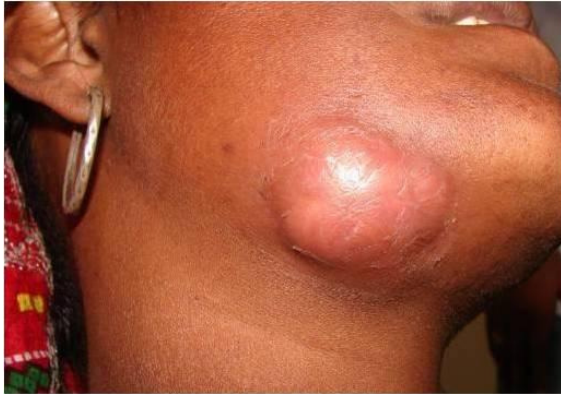[Table/Fig 5]: Intraoral view at six months of follow up



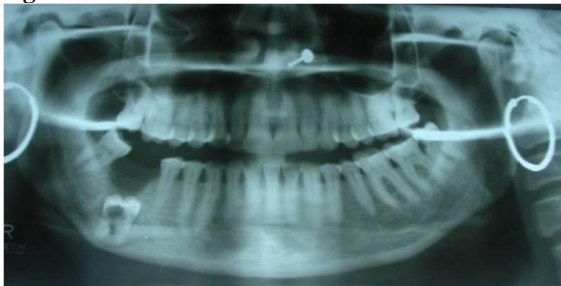
### Case 3

A 35 years old female reported to our department with the complaint of pain and swelling in relation to the right lower part of the face since 10 days. [Table/Fig 6] The patient gave a history of extraction in relation to the right lower back tooth region 15 days back. On clinical examination, it was found that there was a soft fluctuant swelling of app. 2x1.5 cm on the right lower third of the face and intraorally, there was a healing wound in relation to the 46 socket. No abnormality was detected in the surrounding tooth structures. The OPG [Table/Fig 7] showed a carious impacted right lower molar. Her medical history and blood investigations were within the normal limits. A diagnosis of periapical abscess, secondarily due to a carious impacted molar, was made. The impacted carious tooth was surgically removed and I and D was done for the extra oral abscess [Table/Fig 8]. Within 7 days, the patient was free of the signs and symptoms. [Table/Fig 9]

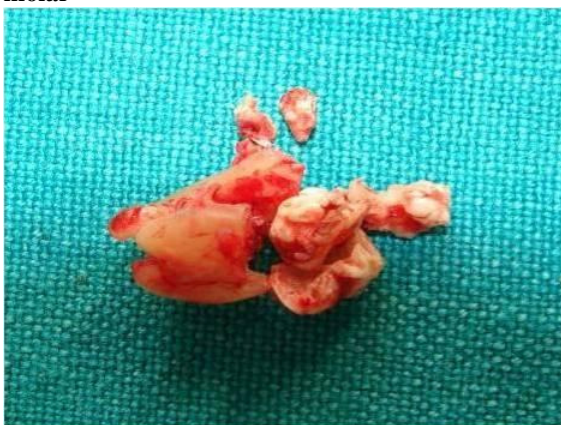[Table/Fig 6]: Extraoral view showing the swelling in relation to the right lower third of the face



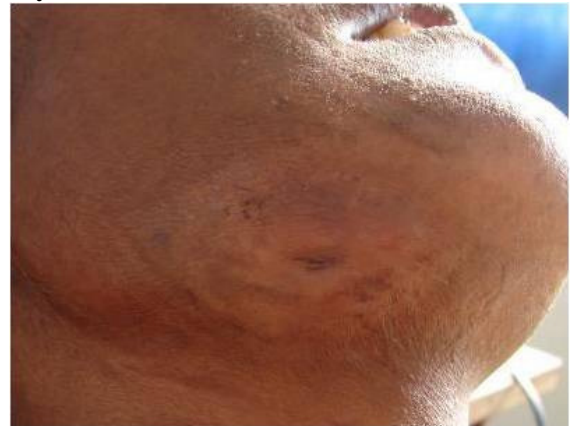[Table/Fig 7]: OPG showing the impacted carious right lower molar



[Table/Fig 8]: The extracted impacted carious molar



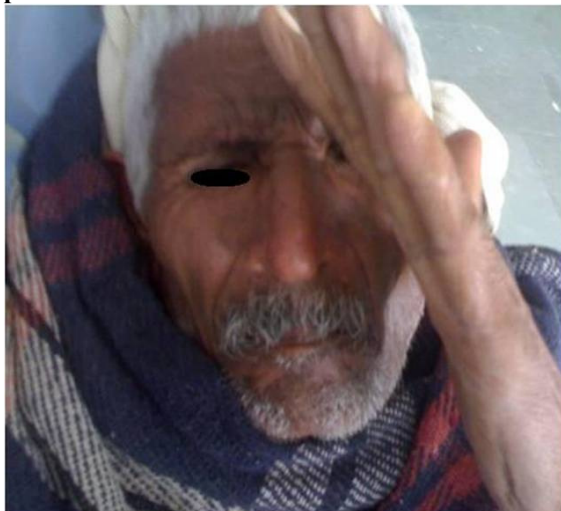[Table/Fig 9]: Postoperative extraoral view after 7 days



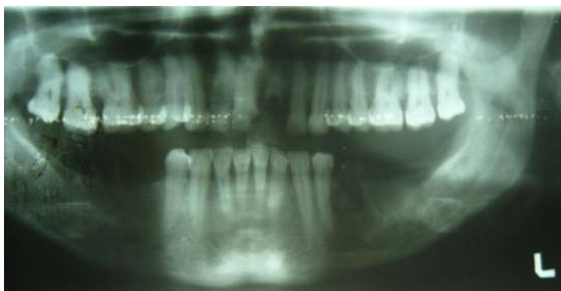
#### Case 4

One of the most commonly misdiagnosed cases in exodontia is the case of trigeminal neuralgia. A 65 years old male patient, with a history of multiple extractions of the teeth, reported to our department with a chief complaint of pain in relation to the right lower back tooth region since 8-9 months [Table/Fig 10] and [Table/Fig 11]. His detailed history revealed that the pain was sharp shooting in nature, was intermittent and was radiating towards the ipsilateral temporal region from the right lower back tooth region. The aggravating factor for the pain was the chewing of food on the same side, which was relieved after some time. A selective nerve block with local anaesthetic infiltration (2% xylocaine; 1:80,000) confirmed the diagnosis of trigeminal neuralgia. The patient was then prescribed carbamazepine therapy (200mg- tds dose) after the routine blood investigations. Presently, the patient is on follow up, with no symptoms of recurrence.

**[Table/Fig 10]: Extraoral frontal view of the patient**



**[Table/Fig 11]: OPG confirming the history of multiple extractions**



## DISCUSSION

The extraction of teeth is an important technique and a skill that many practitioners will not be able to master by practice and experience alone. [3] The extraction procedure must incorporate a thorough health history and a review of the systems before the dental treatment begins. As the general population ages, the patients who require extraction may present additional challenges which are secondary to their medical treatment. [4],[5]

Before the initiation of tooth extraction, a thorough clinical and radiographical examination of the area is essential. The clinical inspection of the area where the object tooth or teeth are located is simply not enough. Instead, an oral examination with an emphasis on the object tooth or teeth is required. The practitioner should examine the patient's ability to open the mouth completely. Any swelling, lump and subtle changes in the gingival or other

surrounding tooth structures should not be overlooked.

A radiograph of the object teeth is essential before the extraction is performed. Irrespective of whether the radiograph is of panoramic or periapical view, it must show the entire tooth and the surrounding bone for inspection. The bone in the area of the object tooth should also be examined radiologically and abnormal radiolucencies and radiopacities should be noted and investigated. The time spent with the patient, seeking a second opinion and thorough examination is important to reach a certain diagnosis. [6]

In our cases, the local practitioners have missed one or another part before performing any treatment plan. In our first case, some subtle changes might have been present, which were suggestive of the tumour which had been overlooked. The extraction of the tooth which is associated with the tumour can be problematic. Irrespective of whether the tumour is benign or malignant, it is important to have a treatment plan before the extraction. If the teeth which are associated with the tumour are improperly treated, it can result in recurrence of the tumour and can cause further damage to the nearby associated structures. In the case of known malignant tumours, no teeth should ever be removed because the surgical insult could cause the dissemination of the cells and thereby hasten the metastatic process.

In our second case, the patient went for radiotherapy about which the dental practitioner was not aware. Extraction is contraindicated in the irradiated area before 6 months, as ORN is likely to develop due to alteration in the blood flow to the tissue and it diminishes the flow of saliva from the glands. Hyperbaric oxygen therapy can assist the damaged tissues in their attempt to be healed [7],[8], and [19]. If a patient requires the removal of a tooth from an irradiated region, the tooth should be removed as atraumatically as possible, and a small mucoperiosteal flap should be developed to gain primary closure. Post radiation extractions in the maxilla have a less chance of developing ORN than those in the mandible, owing to the

cancellous nature of the bone and the collateral blood supply to the region. The decreased blood supply to the bone is permanent and does not improve with time and so, the dentist should consider HBO (hyper baric oxygen) therapy.

The focus of infection refers to a circumscribed area of the tissue which is infected with exogenous pathogenic microorganisms and is usually located near a mucous or cutaneous surface. There may be single or multiple foci of infection. [10] In our subsequent case, we were having multiple foci of infections. In our third case, a thorough radiological investigation before the extraction might have solved the inconvenience which could be caused to the patient.

Trigeminal neuralgia is one of the cases with a common misdiagnosed pathology. The patient usually suffers from a sudden onset of severe unilateral pain along the distribution of the trigeminal nerve, which is along the scalp, forehead, eyes, nose, lips and jaw. The onset of the symptoms is usually triggered by brushing teeth, chewing, a breeze, by stress or even by just touching the cheek. Due to the nerve distribution pattern, the patients wrongly assume that the pain could be related to the teeth. Our last case was going for multiple extractions to get relief from pain. Although he was giving a characteristic history of neuralgic pain with a trigger zone, he was also giving the subtle clue which was hinting towards the diagnosis which was missed.

The extraction of tooth is one of the basic components of the dental procedure. The above mentioned case reports have proved that every tooth extraction procedure is alike and that they should be guided by clinical examination and

radiological assessment, with a thorough detailed medical history which is integrated with the clinician's expertise.

## CONCLUSION

There are certain criteria which make us dentists rather than technicians and correct diagnosis is definitely one of them. Few minutes which are spent with the patients, can avoid lots of problems. We want to conclude from our experience that there is always the possibility that we can be wrong. Complications are a part of our profession. Our work creates complications and no work means, no complications. But our main aim should be to reduce the incidence of complications.

## REFERENCES

- [1] Geoffery L. Howe. The extraction of teeth ,2<sup>nd</sup> ed, Butterworth & Co.,page-1.
- [2] Daniel M. Laskin. Oral and Maxillofacial Surgery. St. Louis, Mosby ,Vol 2, page 3.
- [3] Raymond J. Fonseca; Oral And Maxillofacial Surgery,first edition, Saunders,volume 1;2000
- [4] Archer WH: Oral And Maxillofacial Surgery, ed 5. Philadelphia, WB Saunders, 1975.
- [5] Kruger GO: Textbook of Oral and Maxillofacial Surgery, ed 6. St. Louis, Mosby, 1984.
- [6] Peterson LJ, Ellis EE, Hupp JR, Tucker MR: Contemporary Oral and Maxillofacial surgery. St. Louis, Mosby, 1998.
- [7] Epstein J et al: Postradiation osteonecrosis of mandible. Oral Surg 1997; 83:657.
- [8] Marx RE, Johnson RP, Klevin SN: prevention of osteoradionecrosis: A randomized prospective clinical trail of hyperbaric oxygen versus pencillin. J Am Dent Assoc 1985; 11:49.
- [9] Maxymiw WG, Wood RE, Liu F:Post radiation dental extarctions without hyperbaric oxygen. Oral Surg 1991; 72: 270.
- [10] Shafer, Hine, Levy; Shafer`s textbook of oral pathology, ed 5, Elsevier, 2006.