

# Urinoma Secondary to Posterior Urethral Valve Presenting with Features of Intestinal Obstruction in a Neonate: A Case Report

ARIJIT BHOWMIK<sup>1</sup>, DONA BANERJEE<sup>2</sup>, RAJASREE SINHA<sup>3</sup>, SANDEEP LAHIRY<sup>4</sup>

## ABSTRACT

Urinoma (or perirenal uriniferous pseudo cyst) occurs due to extravasation of urine in the perirenal space. Common causes include traumatic renal injury or an obstruction in the outflow tract as in a posterior urethral valve. Though rare, such diagnosis should be considered in neonates presenting with expanding cystic masses in the abdomen.

Here, we present a case of a four-day-old neonate, who presented to us with abdominal distension and bilious vomiting. The initial radiographic studies showed a cystic mass surrounding the right kidney. Urine was aspirated from the mass and Micturating Cysto-Urethrogram (MCU) showed the presence of a Posterior Urethral Valve (PUV). A diagnosis of urinoma secondary to PUV was confirmed. After relieving the obstruction by vesicostomy, symptoms of intestinal obstruction resolved. On later follow up, size of urinoma also gradually decreased.

This proves that not every case of a distended abdomen and bilious vomiting in a neonate, necessarily points towards Necrotising Enterocolitis (NEC) or intestinal obstruction.

**Keywords:** Infant, Uretero-pelvic junction obstruction, Urine

## CASE REPORT

A term, four-day-old male child (weight: 2.7 kg) presented with progressive abdominal distension, bilious vomiting and decreased urine output. The antenatal history was insignificant since antenatal Ultrasonography (USG) data was unavailable. The mother revealed that she had a normal vaginal delivery. Breastfeeding was established at birth and the baby was subsequently discharged in good health. At home, the child was on exclusive breastfeeding. However, the parents had noticed a progressive distension of abdomen since birth with recurrent bilious vomiting after feeds and decreased urine output.

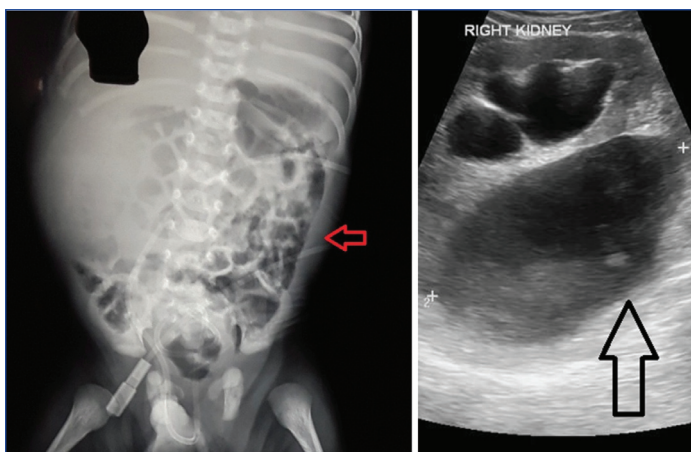
Initial examination revealed a normal cry, reflexes and tone. On admission, the baby was haemodynamically stable, and tachypnoeic (respiratory rate of 64/minutes). However, there was no chest retraction. The abdomen was distended with overlying skin tense and shiny, with distended superficial veins. Intestinal Peristaltic Sounds (IPS) were audible. There was no obvious congenital anomaly noted. Per-rectal (PR) examination did not reveal any stool or obstructive pathology. Initial investigations showed a negative sepsis screen. Serum electrolytes and renal function tests were within normal limit [Table/Fig-1]. Blood culture and antibiotic sensitivity reports reported absence of any microbial growth. The child was kept Nil Per Oral (NPO) with continuous Ryle's tube drainage. Urinary catheterisation was performed and intravenous fluids with empiric antibiotic therapy was started.

The chest skiagram was normal. Abdominal X-ray revealed a 'full right flank' with an increased radiodensity noted at right abdomen along with displaced bowel loops towards the left side, raising suspicion of an intraabdominal mass lesion in right abdomen [Table/Fig-2a]. USG whole abdomen showed a large cystic collection [Table/Fig-2b]. Measurements included: Right kidney: 4.4 cm, Left Kidney: 3.8 cm. Bilateral renal cortical echogenicity was raised with altered Cortico-Medullary Differentiation (CMD). There was no ascites and other abdominal viscera were normal. Axial Computerised Tomography (CT) scan showed a hypodense collection in right abdomen encircling right kidney [Table/Fig-3a]. The collection itself was well encysted; no free fluid in abdomen

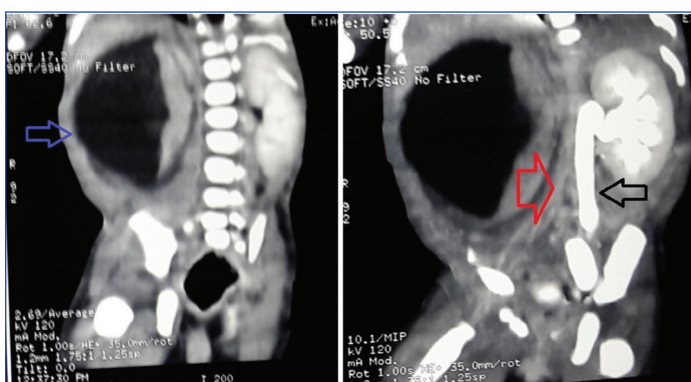
was present. On delayed scan, no contrast excretion was noted at right side. Left kidney and left sided pelvi-calyceal system with ureter showed normal contrast excretion but with dilatation of pelvis and ureter [Table/Fig-3b].

Parameters	Values	Parameters	Values
Haemogram		Urine	
Haemoglobin (g/dL)	17.0	WBC (per HPF)	<5
Haematocrit (%)	54	RBC (per HPF)	1
MCV	98	Epithelial cells (per HPF)	<5
Reticulocyte (%)	0-1	Organisms	Nil
WBC × 10 <sup>9</sup> /L	12.2		
Neutrophil × 10 <sup>9</sup> /L	5.5		
Lymphocyte × 10 <sup>9</sup> /L	5.0	Acid Base Values	
Monophils × 10 <sup>9</sup> /L	1.1	pH	7.39
Eosinophils × 10 <sup>9</sup> /L	0.5	PCO <sub>2</sub> (mmHg)	36
Platelets (10 <sup>9</sup> /mm <sup>3</sup> )	198	HCO <sub>3</sub> (mEq/L)	22
PT (second)	12	PO <sub>2</sub> (mmHg)	85
aPTT (second)	25	Anion gap	18
FBG (mg/dL)	210		
Capillary refill (second)	2 seconds		
Electrolytes		Others	
Na (mEq/L)	148	Urea (mm/L)	11.3
K (mEq/L)	5.9	Creatinine (mm/L)	0.3
Cl (mEq/L)	103	CRP (mg/dL)	5
Ca (mm/L)	1.98	Lactate (mm/L)	0.8
Mg (mm/L)	0.9	Albumin (g/L)	36
		ALP (IU/L)	42

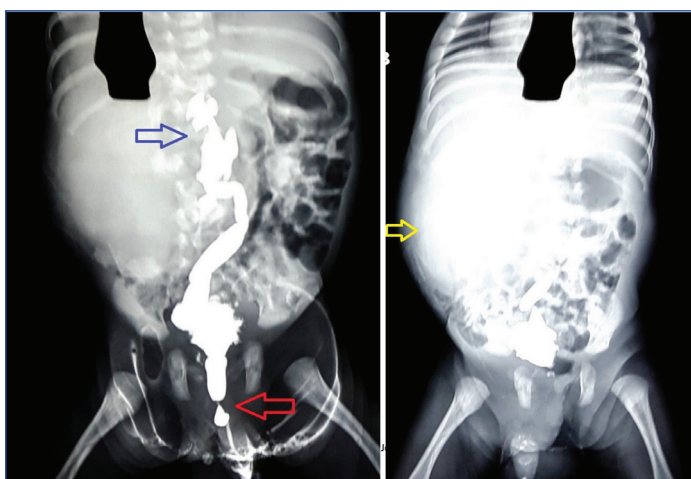**Table/Fig 1:** Summary of laboratory parameters of the four-day old neonate. Abbreviations: WBC, White blood cell; RBC, Red blood cell; HPF, High power field; PT, Prothrombin Time; aPTT, Activated Partial Thromboplastin Time; FBG, Fasting blood glucose; CRP, C-reactive protein; ALP, Alkaline phosphatase.



**[Table/Fig-2]:** a) X-ray Abdomen showed 'Full right flank' suggestive of urinoma, with increased radiodensity noted at right abdomen along with displaced bowel loops towards left side (red arrow); b) USG whole abdomen showed a large cystic collection (black arrow) around the right kidney.



**[Table/Fig-3]:** a) CT abdomen showed large cystic collection (blue arrow) encircling right kidney, the right ureter seems to be compressed by the pressure effect of the collection; b) Delayed CT scan showed no contrast excretion noted at right side (red arrow). Left kidney and left sided pelvi-calyceal system with ureter showing normal contrast excretion but with dilatation of pelvis and ureter (black arrow).



**[Table/Fig-4]:** a) Contrast imaging showed bladder wall irregular with tiny diverticula noted, Grade 4 VUR noted at right side (blue arrow), no VUR on left side in present film. Posterior urethra fusiformly dilated with abrupt narrowing suggesting PUV (red arrow); b) Postvoid MCU film showing diffuse spreading of dye on the right side (yellow arrow).

Diagnostic fluid aspiration from the mass, revealed a straw coloured fluid, which had an acidic reaction to litmus paper. Fluid biochemistry showed a creatinine value of 221.8 mg/dL, confirmed it to be urine. An Micturating Cysto-Urethrogram (MCU) was done next, as the renal function was within normal limit. It showed an irregular bladder with tiny diverticula. A grade IV: Vesico-Ureteral Reflux (VUR) with dilatation of ureter was noted on the right side [Table/Fig-4a]. No VUR was noted on the left side in the present film. Posterior urethra was fusiformly dilated with abrupt narrowing suggesting a Posterior Urethral Valve (PUV). Diffuse spreading of dye (extravasation) noted

in postvoid MCU confirmed right sided VUR [Table/Fig-4b].

Thus, the final diagnosis was right sided urinoma secondary to posterior urethral valve with unilateral grade IV reflux with normal kidney function but causing extra intestinal compression of gut with features of intestinal obstruction. On day four post admission, the neonate had undergone a percutaneous nephrostomy, resulting in drainage of approximately 400 mL of urine. Resection of PUV was done subsequently. Repeat USG confirmed reduction in the perirenal and subcapsular collection, with improved symptomatology. The neonate made a gradual recovery and was discharged from the hospital. Antibiotic prophylaxis was started. On one month follow up, baby was in good health with marked regression of urinoma size on USG (2.3×1.5 cm).

## DISCUSSION

The foetal urinoma or a perirenal uriniferous pseudo cyst occurs due to extravasation of urine in the perirenal space. The common causes for such extravasation can be trauma to kidney or an obstruction in the outflow tract as in a posterior urethral valve, ureteric obstruction or a pelvi-ureteric junction obstruction [1]. The incidence of posterior urethral valves is between 1 in 5000:8000 [2]. Upto 10-15% of neonates with a PUV may have a secondary urinoma [3]. In such cases, progressive renal deterioration is common and 25-40% patients develop renal failure [4-6]. Fluid and electrolyte imbalance or respiratory compromise (secondary to lung hypoplasia) can also occur [7].

Such obstruction causes severe renal parenchymal injury and in order to preserve the foetal and neonatal renal function, various "pop-off" valve mechanism like unilateral reflux and dysplasia, urinary extravasation (urinoma, urinary ascites) and congenital bladder diverticula has been advocated which are present in about 30% of patients with PUV [8] with disputed effect on renal function with some retrospective studies showing a protective impact [9].

The 'mass effect' of urinoma may result in a myriad of symptoms [10]. It may present with features of respiratory distress, abdominal distension etc., [11]. Urinoma presenting with symptoms mimicking intestinal obstruction is very rare. Only a few case reports mentioned presentation of urinoma with recurrent bilious vomiting and abdominal distension [12,13]. In this case, the neonate presented with abdominal distension with bilious vomiting. The differential diagnosis made in such case is usually surgical with causes being duodenal atresia, malrotation with volvulus, jejunoileal atresia, meconium ileus or NEC [14]. Delay in treatment initiation may cause bowel ischemia [15].

Initially, we had similar suspicion but the USG and CT scan proved beyond doubt that the cause of obstruction is an extra intestinal cyst, later proved to be due to an urinoma secondary to a PUV. Interestingly, majority cases of urinoma reported have right side affected [16].

## CONCLUSION

Neonates presenting with abdominal distension and bilious vomiting is generally secondary to intestinal atretic lesion, malrotation, NEC etc. This presentation secondary to extra intestinal compressive mass is a rare entity. In our case, it was a localised form of urinary extravasation, presenting with features of intestinal obstruction. Though rare, a diagnosis of urinoma should be considered in neonates presenting with rapidly expanding cystic masses in the abdomen.

## REFERENCES

- [1] Silveri M, Adorasio O, Pane A, Zaccara A, Bilancioni E, Giorlandino C, et al. Fetal monolateral urinoma and neonatal renal function outcome in posterior urethral valves obstruction: the pop-off mechanism. *Pediatr Med Chir.* 2002;24(5):394-96.
- [2] Atobatele MO, Oyinloye OI, Nasir AA, Bamidele JO. Posterior urethral valve with unilateral vesicoureteral reflux and patent urachus: A rare combination of urinary tract anomalies. *Urol Ann.* 2015;7(2):240-43.

- [3] Cho A, Khan A, Chandran H, Carroll D. Biliious vomiting in two neonates due to an urinoma secondary to posterior urethral valves. *J Ped Surg Case Rep*. 2015;3(12):541-44.
- [4] Parkhouse HF, Barratt TM, Dillon MJ, Duffy PG, Fay J, Ransley PG, et al. Long-term outcome of boys with posterior urethral valves. *Br J Urol*. 1988;62(1):59-62.
- [5] Reinberg Y, de Castano I, Gonzalez R. Prognosis for patients with prenatally diagnosed posterior urethral valves. *J Urol*. 1992;148(1):125-26.
- [6] Bhadoo D, Bajpai M, Panda SS. Posterior urethral valve: Prognostic factors and renal outcome. *J Indian Assoc Pediatr Surg*. 2014;19(3):133-37.
- [7] Macpherson RI, Leithiser RE, Gordon L, Turner WR. Posterior urethral valves: an update and review. *Radiographics*. 1986;6(5):753-91.
- [8] Rittenberg MH, Hulbert WC, Snyder HM 3rd, Duckett JW. Protective factors in posterior urethral valves. *J Urol*. 1988;140(5):993-96.
- [9] Oktar T, Salabaş E, Kalelioğlu İ, Atar A, Ander H, Ziylan O, et al. Fetal urinoma and prenatal hydronephrosis: how is renal function affected? *Turk J Urol*. 2013;39(2):96-100.
- [10] Lee E, Thonell S. Posterior urethral valves causing urinomas: Two case reports. *J Med Imaging Radiat Oncol*. 2002;46(1):101-05.
- [11] Hoffer FA, Winters WD, Retik AB, Ringer SA. Urinoma drainage for neonatal respiratory insufficiency. *Pediatr radiol*. 1990;20(4):270-71.
- [12] Moore DP, Goodson M, Plucinski T. Urinoma: an unusual case of emesis in a brain-injured child. *Pediatr Rehabil*. 1997;1(3):185-89.
- [13] Kimura K, Loening-Baucke V. Biliious vomiting in the newborn: rapid diagnosis of intestinal obstruction. *Am Fam Physician*. 2000;61(9):2791-98.
- [14] Prasad GR, Aziz A. Abdominal plain radiograph in neonatal intestinal obstruction. *J Neonatal Surg*. 2017;6(1):6.
- [15] Jiwane A, Holland AJA, Soundappan SSV, Arnold J. An unusual cause of biliious vomiting in a neonate. *J paediatr child health*. 2008;44(12):747-49.
- [16] Yitta S, Saadai P, Filly RA. The fetal urinoma revisited. *J Ultrasound Med*. 2014;33(1):161-66.

**PARTICULARS OF CONTRIBUTORS:**

1. Assistant Professor, Department of Paediatric Medicine, Medical College and Hospital, Kolkata, West Bengal, India.
2. Residential Medical Officer, Department of Paediatric Medicine, Medical College and Hospital, Kolkata, West Bengal, India.
3. Postgraduate Trainee, Department of Paediatric Medicine, Medical College and Hospital, Kolkata, West Bengal, India.
4. Postgraduate Trainee, Department of Pharmacology, Institute of Postgraduate Medical Education and Research, Kolkata, West Bengal, India.

**NAME, ADDRESS, E-MAIL ID OF THE CORRESPONDING AUTHOR:**

Dr. Sandeep Lahiry,  
244 A.J.C Bose Road, Department of Pharmacology, Institute of Post Graduate Medical Education and Research,  
S.S.K.M Hospital, Kolkata-700020, West Bengal, India.  
E-mail: sndplry@gmail.com

Date of Submission: **Apr 25, 2017**  
Date of Peer Review: **May 25, 2017**  
Date of Acceptance: **Oct 07, 2017**  
Date of Publishing: **Nov 01, 2017**

**FINANCIAL OR OTHER COMPETING INTERESTS:** None.