

# Advancing Cholesteatoma Secondary to Acquired Atresia of the External Auditory Canal: Clinical Perspectives

ARIJIT JOTDAR<sup>1</sup>, MAINAK DUTTA<sup>2</sup>, SOHAG KUNDU<sup>3</sup>, SUBRATA MUKHOPADHYAY<sup>4</sup>

## ABSTRACT

Acquired atresia of External Auditory Canal (EAC) is seldom encountered in routine otolaryngology practice. Apart from resulting in moderate-to-severe conductive hearing impairment, it is a potentially dreaded condition which might lead to canal cholesteatoma. Suspected to develop as a consequence of a pre-existing chronic otitis externa/media, the EAC atresia leads to proximal (medial) accumulation of desquamated epithelium and denatured keratin (the canal cholesteatoma) that further leads to aggravation of the chronic otitis, thereby initiating a vicious cycle. The canal cholesteatoma might progress unhindered into the middle ear and mastoid cavity, with its characteristic bone-eroding property, producing complications. A high index of clinical suspicion along with proper imaging are therefore essential to apprehend the disease progression in a patient presenting with an apparently innocuous EAC stenosis/atresia. In this report, we illustrate the clinical details of a young girl with unilateral acquired EAC atresia where canal cholesteatoma had turned extensive, invaded the middle ear cleft, and produced a post-aural fistula, thereby establishing one of the extreme outcomes of chronic otitis.

**Keywords:** Canal atresia, Canal cholesteatoma, Chronic otitis, Complications, Post-aural fistula

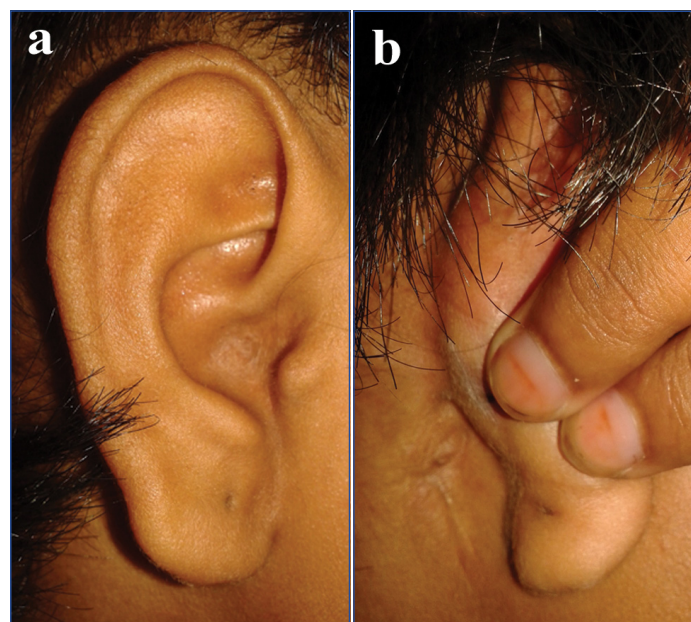
## CASE REPORT

An 11-year-old girl from rural habitat presented with occlusion of the right ear canal since her early childhood, associated with ipsilateral impairment of hearing for the same duration. According to the parents the right ear canal occlusion was noted when she was about one year of age, and was not present at birth. Further inquiry revealed that the child suffered from recurrent self-limiting episodes of reddish, scanty, fetid discharge from the right ear in her neonatal period and infancy. There was no history of trauma, surgical or otherwise, to the right ear. Five years back, she developed a fistula behind the right ear that drained foul-smelling purulent discharge on-and-off. She was asymptomatic regarding her left ear. The parents consulted local physicians and primary level hospital, but were irregular in their follow-up, and were reluctant to consider surgery at a higher centre as suggested by the doctors. It was only when the symptoms of their child aggravated that they sought help at the otolaryngology department of a tertiary care institute.

On examination, the right EAC was found to be completely occluded throughout its diameter in the parasagittal plane, and the occlusion was covered with skin and felt firm on probing [Table/Fig-1a]. The pinna, however, was normal in size, shape and position. A fistula could be seen in the retro-auricular region of the right ear close to the mastoid tip with puckering of the adjacent skin [Table/Fig-1b]. It was quiescent during examination, but had the history of draining of foul-smelling, purulent material spontaneously and on compressing the surrounding area. The pinna and EAC on the left side and the adjacent post-aural region were unremarkable, although there was an incidental small, dry central perforation. Pure tone audiometry showed a pure tone average of ~77 dB and average air-bone gap of ~49.5 dB on right side, indicating severe degree of conductive hearing loss, with a mixed component after 1kHz [Table/Fig-2]. High Resolution Computed Tomography (HRCT) of the temporal bones [Table/Fig-3] showed complete occlusion of the right EAC by accumulation of soft tissue with entrapped air pockets, that also resulted in widening of the EAC. The soft tissue lesion encroached

the middle ear and filled it up completely, and further involved the mastoid cavity with a breach in the outer cortex. The middle ear ossicles were also eroded.

The clinical and imaging details of the patient suggested an acquired EAC atresia with resultant cholesteatoma extending into the middle ear cleft and producing a chronically draining mastoid fistula from a cortical breach. The child was prepared for surgery under general anaesthesia, and her routine pre-anaesthetic work-up was unremarkable. Exploration of the right mastoid and removal of the EAC and middle ear cleft cholesteatoma, along with reconstruction of EAC was planned. Accordingly, the tympanomastoid cavity



**[Table/Fig-1]:** The right external auditory canal shows complete atresia, that is covered with normal-appearing skin (a). The skin in the post-aural region shows puckering with a fistulous opening that was quiescent during examination (b).

was entered through a standard post-aural (Wilde's) incision, taking the puckered fistulous skin within it. The findings at surgery corroborated with those of the imaging. Extensive cholesteatoma was found occupying whole of the EAC, tympanic cavity, aditus, mastoid antrum, and extending upto the tip cells, already destroying part of the posterior bony canal wall. It was also noted following removal of cholesteatoma that the EAC was well-formed, with the area of membranous/fibrous atresia on its lateral aspect only. No remnant of ossicles except the malleus head and stapes footplate was found. Cholesteatoma and diseased mucosa were meticulously removed from the middle ear cleft, and a radical mastoidectomy

was done. This necessitated reconstruction of the atretic portion of EAC by removing the fibrous plate and covering the bare area of the canal with redundant skin obtained from the fibrous partition. This was further supplemented with a wide conchomeatoplasty. Antibiotic-soaked Gelfoam™ and gauze-pack were inserted in the canal, especially in its lateral aspect, to keep it patent and prevent re-stenosis.

During the follow-up, for subsequent two months, the ear-wicks were periodically replaced and kept moist by antibiotic-steroid ear-drops. At the end of one year, the girl was doing well with a patent EAC and dry tympanomastoid cavity, without any sign of cholesteatoma recrudescence, and with an improved hearing. She is being presently planned for a second-look surgery aimed at restoring the hearing mechanism in the middle ear, hoping for a better hearing outcome.

Prior to writing of this report, the authors obtained informed consent in written from the parents of the child regarding documentation and publication of the clinical details, including pre-operative, imaging and surgical photographs, and that they would try their best to keep their child de-identified.

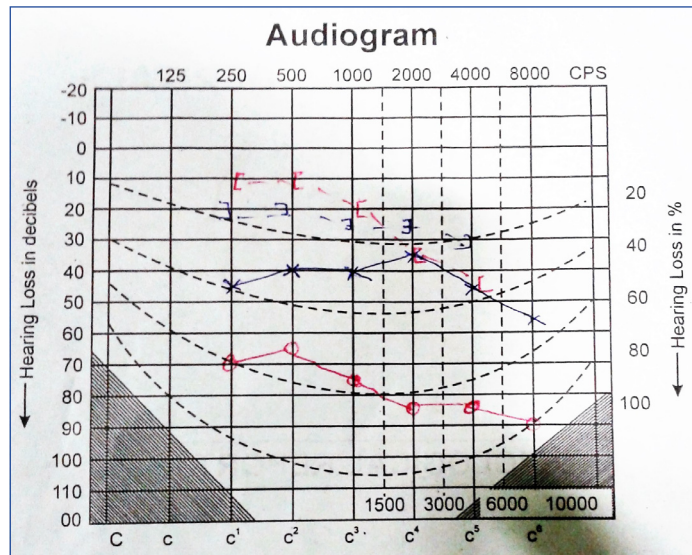
## DISCUSSION

Acquired atresia of EAC is a relatively uncommon disease, with an incidence of 0.6 cases/1,00,000 people [1,2]. More appropriately, it is an unusual complication resulting from recurrent otitis externa, chronic otitis media, trauma to the EAC (previous surgery, or accidental), and neoplasm [1,3]. Apart from these, some rare causes like primary systemic amyloidosis [4], radiation therapy in the head-neck region [5], and vesico-bullous disorders [6] might also be responsible. Patients mostly present with partial or total occlusion of the EAC which are often covered by normal-appearing skin. However, the sinister implication of this acquired blockage of the EAC is the accumulation of desquamated epithelium and denatured keratin material, which, with time, build up under pressure along the canal space as canal cholesteatoma. This is essentially a part of the vicious cycle where the chronic otitis externa and/or media is propagated by the advancing canal cholesteatoma that was formed as a result of the EAC atresia, which was itself a sequel to the pre-existing chronic otitis. The canal cholesteatoma has the notorious feature of bone erosion, and can potentially invade the middle ear cleft and result in serious, life-threatening complications.

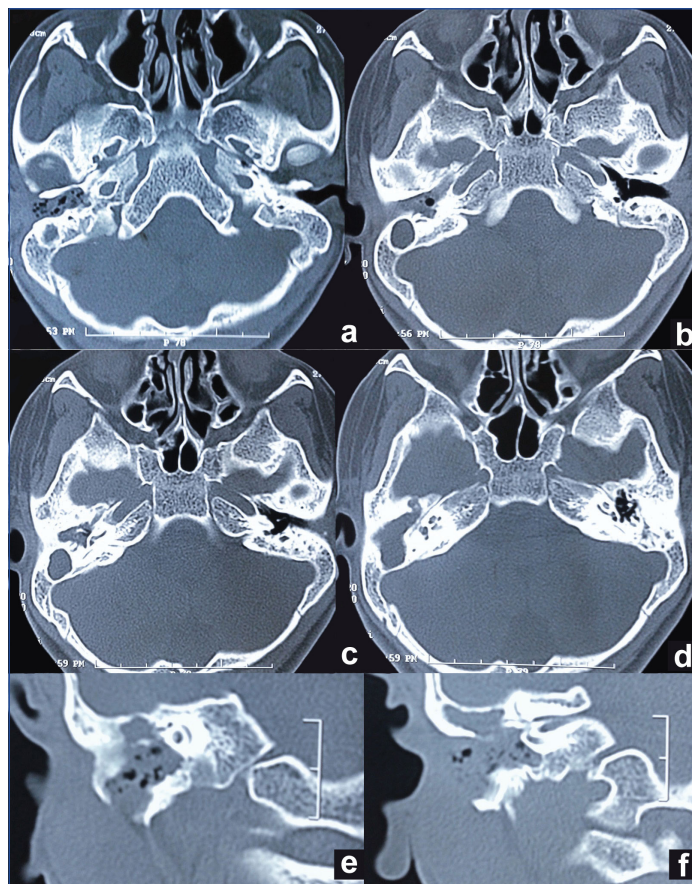
Owing to the rarity of acquired atresia of EAC, the true incidence of secondary cholesteatoma is limited to only a handful of reports. Only three out of 41 patients with acquired atresia of EAC developed canal cholesteatoma in the study by Magliulo G [7], whereas the retrospective review over 27 years by Becker BC and Tos M [2] found the incidence to be 9%. In contrast, incidences of cholesteatoma secondary to congenital ear anomalies are well documented. Casale G et al., in a large study with congenital aural atresia found 18 ears with secondary cholesteatoma among the 94 ears with congenital canal stenosis [8]. Of the 41 patients of canal anomalies reported by Mazita A et al, 17 had associated cholesteatoma [9].

The clinical details encountered in our patient can be considered as an example of the natural history of such acquired cholesteatoma following complete post-inflammatory EAC stenosis/occlusion. Here, the EAC atresia was probably a consequence of repeated attacks of otitis externa in her infancy, that led to luminal obliteration by gradual accumulation of canal cholesteatoma. Owing to late presentation, the disease progressed unhindered, and the cholesteatoma advanced into the mastoid cavity and eroded part of the posterior canal wall and the outer mastoid cortex to produce an abscess-draining fistula.

The management of this condition involves proper imaging, followed by eradication of the disease, reconstruction of the atretic portion of the EAC, and providing an improved hearing status. HRCT of the temporal bone is the gold standard imaging modality that provides



**[Table/Fig-2]:** Pure tone audiometry shows severe degree of conductive hearing impairment on the right ear, with a mixed component after 1kHz. The dip in the air conduction on the left could be explained by the incidentally discovered central perforation in the tympanic membrane. As per convention, the red lines indicate values for the right ear, and the blue lines for left ear.



**[Table/Fig-3]:** HRCT of the temporal bones shows complete occlusion of the right EAC by accumulated soft tissue with entrapped air pockets (a, b). There is also widening of the canal (a). The soft tissue lesion has encroached the middle ear and filled it up completely (c), extending further into the mastoid cavity (d) producing a breach in the outer cortex (e, f). The middle ear ossicles were also eroded (c, d, e).

explicit anatomic details of the bony architecture, extent of the cholesteatoma, and the possible complications resulting from its erosive property. However, because HRCT has poor soft tissue delineation, it often becomes difficult to distinguish, within the length of the EAC, the differential extents of true fibrous atresia and the resultant canal cholesteatoma. In the authors' opinion, a Magnetic Resonance Imaging (MRI) of the temporal bone might be helpful as an adjunct imaging modality to distinguish between these two pathologies. This is important from the perspective of planning the surgery, especially to obtain an idea for the extent of EAC reconstruction and to choose among its various technical possibilities.

Though mention has been made in the literature of different treatment modalities like use of mitomycin C [10] or stretching steel tubes [11], the mainstay of treatment remains surgery [12]. The surgical steps as mentioned before can be completed in a single or several sittings depending upon the extent of the disease and the magnitude of reconstruction work contemplated, both in the EAC and in the middle ear hearing mechanism. Reconstruction of the EAC can often be a challenging procedure. Following removal of the occluding fibrous tissue from the EAC, split or full thickness skin grafting [12,13,14], or pedicled skin flap [12,15] is generally used to cover the bare canal bone so as to prevent granulations and consequent re-stenosis. Occasionally, free skin harvested from the primary surgical site, like from the medial aspect of pinna, or from the redundant skin from the EAC after excising the fibrous tissue column/plate as performed in this patient, becomes sufficient for the purpose. Apart from the unavoidable situations where a re-look surgery might be required, the most important cause for a revision surgery in these patients is re-stenosis of the surgically refashioned EAC [7,12]. This is a major complication of surgery and the patient should be informed through a written consent about this practical possibility and a corresponding realistic expectation. Re-stenosis can be avoided or minimized by periodic re-packing with antibiotic-soaked Gelfoam™ strips or gauze-pieces, and instilling antibiotic-steroid ear-drops. Meticulous follow-up care and compliance are therefore of utmost importance in order to obtain the optimum outcome from the surgery.

## CONCLUSION

Acquired EAC atresia is a less common complication of chronic

otitis, and is an unusual cause of extensive cholesteatoma having the potential to produce one or more of the known complications resulting from bone erosion. Proper knowledge of this disease entity and a high index of suspicion are therefore essential to prevent its progression into avoidable complications. As a learning example, the present clinical report narrates the consequences of a long-standing atresia of the EAC, and illustrates the clinico-radiological evidence of one of the extreme ends of advancing cholesteatoma.

## REFERENCES

- [1] Namysłowski G, Scierski W, Mrówka-Kata K, Bilińska-Pietraszek E, Turecka L. Surgical treatment of acquired external auditory canal atresia. *Otolaryngol Pol* 2002;56(1):63-7.
- [2] Becker BC, Tos M. Postinflammatory acquired atresia of the external auditory canal: Treatment and results of surgery over 27 years. *Laryngoscope* 1998;108:903-7.
- [3] Jacobsen N, Mills R. Management of stenosis and acquired atresia of the external auditory meatus. *J Laryngol Otol* 2006; 120(4):266-71.
- [4] Alvarez-Ruiz SB, Pérez-Gala S, Aragüés M, Fraga J, García-Díez A. Unusual clinical presentation of amyloidosis: bilateral stenosis of the external auditory canal, hoarseness and a rapid course of cutaneous lesions. *Int J Dermatol* 2007;46(5):503-4.
- [5] Carls JL, Mendenhall WM, Morris CG, Antonelli PJ. External auditory canal stenosis after radiation therapy. *Laryngoscope* 2002;112(11):1975-8.
- [6] Thawley SE, Black MJ, Dudek SE, Spector GJ. External auditory canal stricture secondary to epidermolysis bullosa. *Arch Otolaryngol* 1977; 103(1):55-7.
- [7] Magliulo G. Acquired atresia of the external auditory canal: recurrence and long-term results. *Ann Otol Rhinol Laryngol* 2009; 118(5):345-9.
- [8] Casale G, Nicholas BD, Kesser BW. Acquired ear canal cholesteatoma in congenital aural atresia/stenosis. *Otol Neurotol* 2014; 35(8): 1474-9.
- [9] Mazita A, Zabri M, Aneeza WH, Asma A, Saim L. Cholesteatoma in patients with congenital external auditory canal anomalies: retrospective review. *J Laryngol Otol* 2011; 125(11): 1116-20.
- [10] Battelino S, Hocevar-Boltezar I, Zargi M. Intraoperative use of mitomycin C in fibrous atresia of the external auditory canal. *Ear Nose Throat J* 2005; 84(12):776-9.
- [11] Tirelli G, Nicastrò L, Gatto A, Boscolo Nata F. Stretching stenoses of the external auditory canal: a report of four cases and brief review of the literature. *Acta Otorhinolaryngol Ital* 2015; 35(1):34-8.
- [12] Bajin MD, Yılmaz T, Günaydin RÖ, Kuşçu O, Sözen T, Jafarov S. Management of Acquired Atresia of the External Auditory Canal. *J Int Adv Otol* 2015; 11(2): 147-50.
- [13] Cremers WR, Smeets JH. Acquired atresia of the external auditory canal. Surgical treatment and results. *Arch Otolaryngol Head Neck Surg* 1993; 119(2):162-4.
- [14] el-Sayed Y. Acquired medial canal fibrosis. *J Laryngol Otol* 1998; 112(2):145-9.
- [15] Dhooge IJ, Vermeersch HF. The use of two pedicled skin flaps in the surgical treatment of acquired atresia of the outer ear canal. *Clin Otolaryngol Allied Sci* 1999; 24(1):58-60.

### PARTICULARS OF CONTRIBUTORS:

1. Senior Resident, Department of Otorhinolaryngology and Head-Neck Surgery, Nil Ratan Sircar Medical College and Hospital, Sealdah, Raja Bazar, Kolkata, West Bengal, India.
2. Resident Medical Officer-cum-Clinical Tutor, Department of Otorhinolaryngology and Head-Neck Surgery, Medical College and Hospital, College Street Kolkata, Kolkata, West Bengal, India.
3. Resident Medical Officer-cum-Clinical Tutor, Department of Otorhinolaryngology and Head-Neck Surgery, Medical College and Hospital, College Street Kolkata, Kolkata, West Bengal, India.
4. Professor, Department of Otorhinolaryngology and Head-Neck Surgery, Medical College and Hospital, College Street Kolkata, Kolkata, West Bengal, India.

### NAME, ADDRESS, E-MAIL ID OF THE CORRESPONDING AUTHOR:

Dr. Mainak Dutta,  
Resident Medical Officer-cum-Clinical Tutor, Department of Otorhinolaryngology and Head-Neck Surgery Medical College and Hospital,  
88, College Street, West Bengal-700073, Kolkata, India.  
E-mail: duttainak@yahoo.com

FINANCIAL OR OTHER COMPETING INTERESTS: None.

Date of Submission: **Apr 21, 2017**  
Date of Peer Review: **May 18, 2017**  
Date of Acceptance: **May 29, 2017**  
Date of Publishing: **Aug 01, 2017**