

# Diagnosis and Treatment of Duodenal Lipoma: A Systematic Review and a Case Report

MAO WEI PEI<sup>1</sup>, MING RONG HU<sup>2</sup>, WEN BIN CHEN<sup>3</sup>, CHAO QIN<sup>4</sup>

## ABSTRACT

**Introduction:** Duodenal lipoma is very rare with limited case reports present in literature. Owing to recent advances in endoscopy and modern imaging techniques, more cases are being diagnosed and treated. However, no systematic study of duodenal lipomas has been reported.

**Aim:** To study the diagnosis and treatment of duodenal lipoma in a female patient and review the relative literatures to enhance the knowledge of it.

**Materials and Methods:** A literature search for 'duodenal lipoma' was performed on PubMed. Papers published from 1948 to 2016 in the English language were identified. Each article was then read in detail and analysed for clinical data, imaging features, diagnosis and therapy. Also, we hereby present a case of upper gastrointestinal obstruction secondary to multiple duodenal lipomas in a 67-year-old woman. The

patient underwent a limited bowel resection with an uneventful recovery.

**Results:** Literature review demonstrated 59 cases of duodenal lipoma, which indicate that duodenal lipomas are rare to occur but commonly found in the second part. The peak of incidence seems to be around the fifth and seventh decade of life. Duodenal lipomas may present as gastrointestinal bleeding, abdominal pain, obstruction or upper abdominal fullness. CT, MRI, Endoscopic Ultrasound (EUS), endoscopy are highly accurate diagnostic tools. The disease could be managed by endoscopy or surgery.

**Conclusion:** Our review of literature indicated duodenal lipoma is extremely rare. The symptoms are nonspecific and CT is the first choice for diagnosis. The treatment depends on the patient's condition as well as the size and position of the tumour.

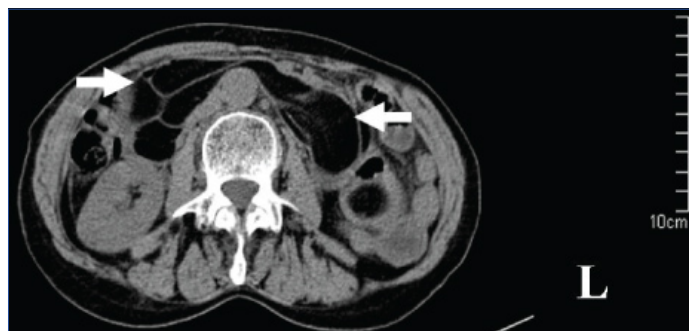**Keywords:** Bleed, Duodenectomy, Duodenal neoplasm, Obstruction

## INTRODUCTION

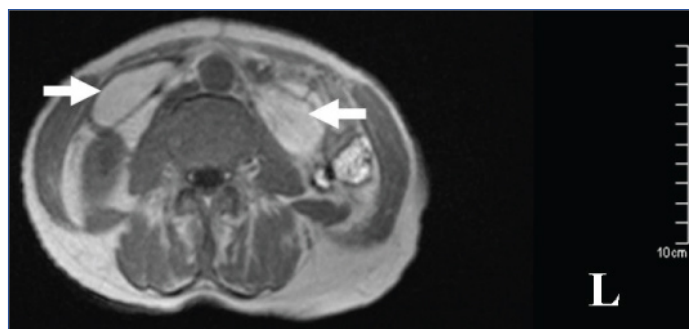
Gastrointestinal lipomas are uncommon benign tumours that occur anywhere along the gut. The most common location for these lesions is the colon, followed by the ileum and the jejunum. Lipomas found in the duodenum {Duodenal Lipomas (DLs)} are very rare with limited case reports present in literature. When small, DLs are often discovered incidentally at laparotomy [1-4]; when larger, they can manifest through acute lesions of the overlying mucosa or the gastrointestinal wall, for example, ulceration [5] or gastrointestinal bleeding [6,7], abdominal pains, intussusceptions [8] or intestinal obstruction [2,9]. Owing to recent advances in endoscopy and modern imaging techniques such as CT scan and MRI, more cases are being diagnosed and treated. However, no systematic study of DLs has been reported. This review focuses on a retrospective analysis of a series of 59 patients with DL, summarize the clinical presentation, diagnosis and treatment of DL.

## CASE REPORT

A 67-year-old woman was transferred to our hospital with one-day history of abdominal pain, vomit and constipation. She had a five years history of epigastric fullness and intermittent, upper abdominal pain in the past. CT revealed intestinal obstruction and hypodense lesions with CT value of -64 Hounsfield Units (HU) to -138 HU located from the descending part of the duodenum to the proximal jejunum, which was suggestive of lipomas [Table/Fig-1]. MR showed fat-containing mass lesions and the masses were high-intensity on T1-weighted and intermediately intensity on T2-weighted images [Table/Fig-2], with a drop in signal on T1 and T2-weighted fat-suppressed images [Table/Fig-3], consistent with a diagnosis of duodenal lipomas.



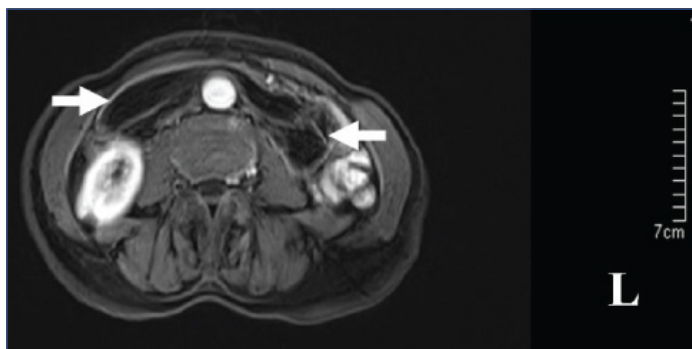
[Table/Fig-1]: CT scan appearance of duodenal lipoma.



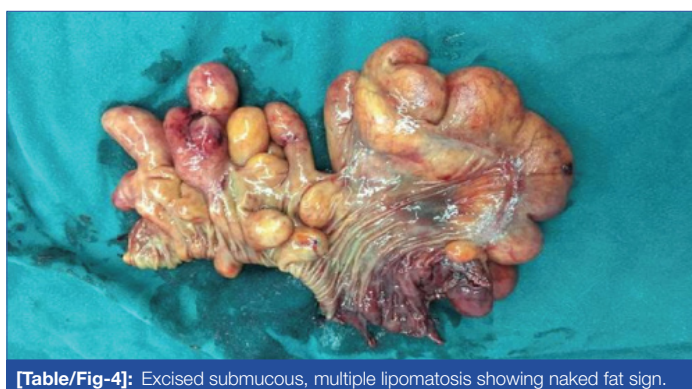[Table/Fig-2]: Axial T1-weighted MRI shows a well-demarcated, hyperintense mass (arrow).

The patient then underwent exploratory laparotomy and multiple, giant lipomas could be palpated in second, third, fourth part of duodenum and proximal jejunum. Duodenum 4 cm distal to ampulla was excised along with 14 cm of proximal jejunum [Table/Fig-4]. Intestinal continuity was maintained by end-to-end duodenojejunal hand-sewn anastomosis. The postoperative period

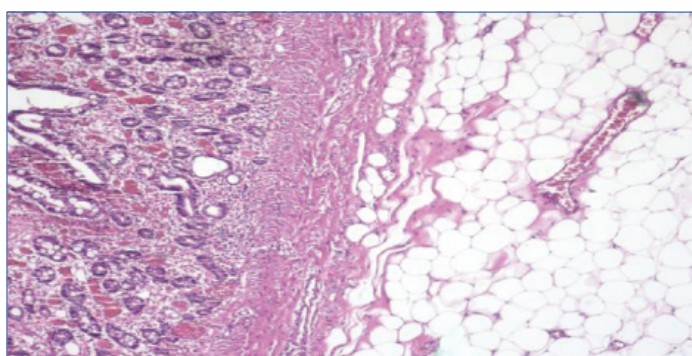
was uncomplicated and she was discharged from the hospital successfully. Final histopathological diagnosis of the specimen were multiple, submucosal lipomas vary from 1.3 × 1.3 × 1.0 cm to 11.0 × 5.0 × 4.0 cm [Table/Fig-5].



[Table/Fig-3]: MRI showing the lesions drop in signal on T1 -weighted fat-suppressed image.



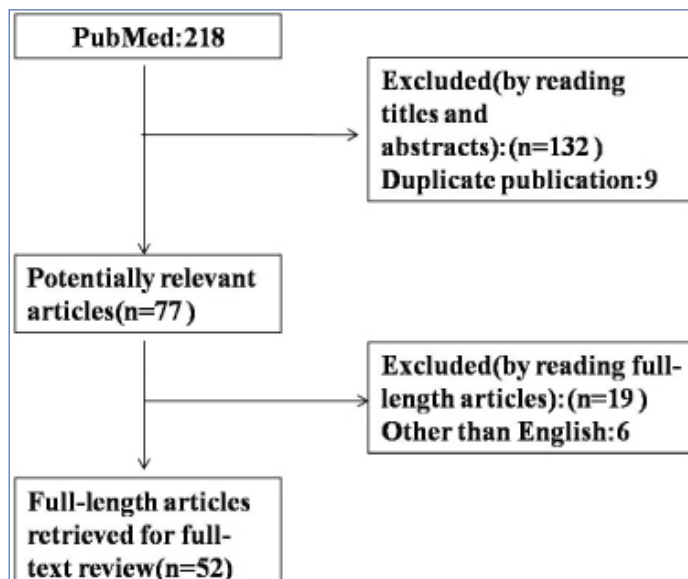
[Table/Fig-4]: Excised submucosal, multiple lipomatosis showing naked fat sign.



[Table/Fig-5]: Pathological report indicating duodenal lipoma originating in submucosal layer (H&E 4x).

## MATERIALS AND METHODS

A systematic literature search was performed using the PubMed database (from 1948 to December 2016) by using the keyword “duodenal lipoma”. The search terms were found in the abstract, title or medical subject heading. Excluded from this review were review articles, expert opinions and studies that were published in languages other than English. The articles that were generated in each step of the search were then aggregated to produce an article list for consideration. Two reviewers independently screened the article titles, abstracts and full texts for further analysis [Table/Fig-6]. Data extracted from each paper included age, sex, number of the lipoma, maximum dimension of the mass, presentation, location, pattern of growth, imaging features, diagnosis and therapy.



[Table/Fig-6]: Flow diagram of article selection for inclusion in this study. (on initial assessment all abstracts were in English but in six articles the full text was found to be in non-English).

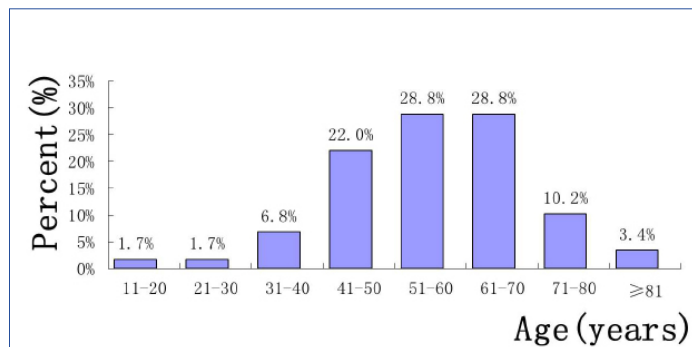
## RESULTS

Using the search strategy listed above, 218 articles were identified. [Table/Fig-6] shows the flowchart of the inclusion and exclusion of the potential studies. During the review of the title, abstract and full text, an additional 166 articles were excluded, resulting in 52 articles that were finally included in this systematic review. Of these 52 articles [3,4,6,7,9-56], there were 59 cases of DL so far reported in English. Of which 49 cases were solitary, 10 cases were multiple. Details of multiple DLs were shown in [Table/Fig-7]. Median age of presentation was 57-year-old (range 12 to 83) with female to

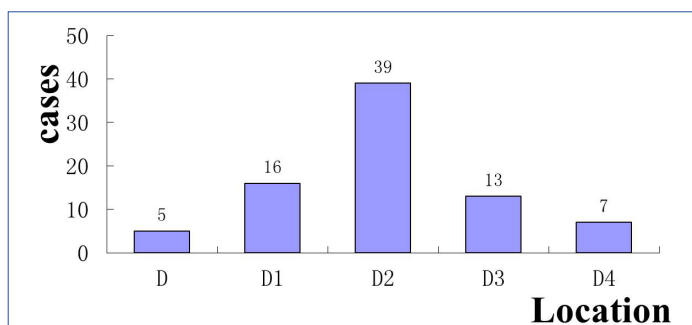
Reference	Age, sex	Presentation	Location	Maximum dimension in cm	Number	Treatment
1. Fawcett NW et al., [10]	36, M	Melena, fatigue, abdominal discomfort, nausea	D2	7	2	Partial duodenectomy
2. Kirkland WG and Boyer RA [11]	60, F	Abdominal pain, vomit	D2	7	3	Transduodenal resection cholecystectomy T-tube was inserted into the common duct
3. Deeths TM et al., [12]	50, F	Epigastric discomfort, vomit	G, D	-	Multiple	Duodenotomy and mass excision
4. Devlies F et al., [13]	67, F	Asymptomatic	G, D1, D2	-	Multiple	Endoscopic biopsy
5. Lundell L et al., [14]	44, M	Obstructive jaundice, gastric outlet obstruction	D2, D3, D4	-	Multiple	Pancreas-sparing duodenectomy
6. Liu X et al., [15]	36, M	Asymptomatic	D	-	Multiple	-
7. Kovač JD et al., [16]	65, M	Postprandial fullness, vomit, epigastric pain	D1, D2	2.5	3	Surgery
8. Weinstock LB et al., [17]	56, M	Asymptomatic	D1, D2, D3	2	Multiple	Biospy
9. Jayasundara J et al., [18]	43, F	Constipation, vomit	D2, D3, D4, J	-	Multiple	Bypass
10. Zirpe D et al., [19]	45, M	Melena	D2, D3, D4, J	4	4	Duodenectomy (D3,D4)
11. Present case	67, F	Abdominal pain, vomit, constipation	D2, D3, D4, J	11	21	Duodenectomy

[Table/Fig-7]: Summary of case reports of multiple duodenal lipomas from 1948 to 2016 [10-19]. F= Female, M= Male, D= Duodenum, G= Gastric, J= Jejunum

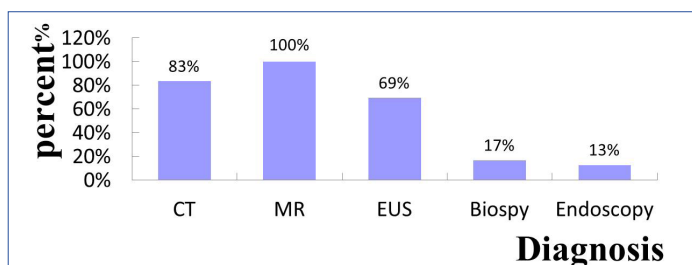
male ratio of 30:29. The age onset is shown in [Table/Fig-8]. The maximum diameter of the tumours ranged from 0.6 cm to 11 cm (mean diameter 4.1 cm). The location distribution of the tumour was shown in [Table/Fig-9]. The pattern of growth was mucosal in four cases, submucosal in forty-five and subserosal in one case. DL may present with obstruction, bleeding, dyspepsia, epigastric pain and discomfort. The diagnostic accuracy of CT, MRI, EUS, endoscopy and biopsy was shown in [Table/Fig-10]. The treatments include observation, endoscopic excision or surgery which was shown in [Table/Fig-11].



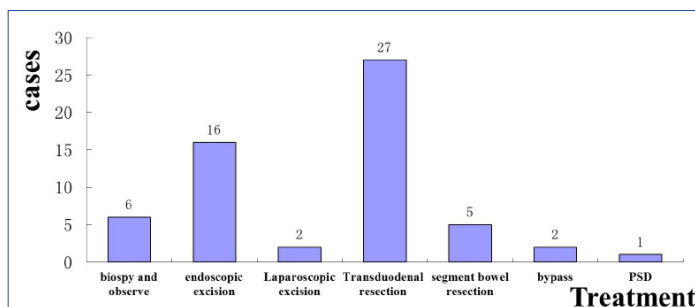
[Table/Fig-8]: Age distribution of patients with duodenal lipoma.



[Table/Fig-9]: Location distribution of the tumour.



[Table/Fig-10]: The diagnostic accuracy of each method.



[Table/Fig-11]: Summary of the treatment.

## DISCUSSION

DLs are extremely rare. Indeed, the incidence of DL is only limited to case report. The DLs are benign and slow growing tumours. Malignant change is unheard of with these lesions [9]. The peak of incidence seems to be around the fifth and seventh decade of life which can be seen in [Table/Fig-8]. The exact aetiology of DL remains unknown. It might be associated with embryonic displacement of adipose tissue, degenerative disease with disturbance of fat metabolism [57] or dyslipidemia [24].

According to our study, as shown in [Table/Fig-9], lipomas tend to be noted mostly in the second part of the duodenum. The majority of the DLs arise from the submucosa [3,4] but may extend through the bowel wall and into the serosal or mesenteric fat. DL presents as a round or ovoid, soft mass with regular or lobulated contours. They can be either sessile or pedunculate. The overlying mucosa of the duodenal lipoma is usually normal, but there may be areas of ulceration or erosion. Multiple DL is very rare, there is only 11 cases reported so far including our case.

The clinical symptoms of DL are always non-special for an early diagnosis, with vague abdominal complaints common in the general population that is often dismissed initially by the consulted physician. Their rarity and failure to consider the disease often lead to a late evaluation of an advanced state of disease at diagnosis. Some patients usually have had symptoms for several months prior to diagnosis. Most of the DLs remain asymptomatic and are discovered incidentally during endoscopy, surgery [3,4,6,41] or autopsy. Symptoms are related to the characteristic of the lipoma, such as size and location. According to our survey, 80% of symptomatic DLs are larger than 2 cm in diameter. If symptomatic, the most common clinical presentation is that of epigastric fullness gradually becoming worse and leading to obstruction [9,58], bleeding [6,7] due to the stretching of the mucosa, with necrosis of the overlying epithelial layers [19], intussusceptions [8] that is rare due to the relatively fixed anatomical position of the duodenum, painless obstructive jaundice and finally pancreatitis. The case with pancreatitis reported by McGrath FP et al., is particularly unusual [26]. The symptoms of DL are nonspecific and hence, they are not useful for differential diagnosis.

Because early symptoms are often nonspecific and vague, it is important to keep the diagnosis of DL in the differential diagnosis of obscure abdominal pain or gastrointestinal tract bleeding. Despite consideration of this diagnosis, it can still be difficult to confirm. Diagnosis can be established by radiological, endoscopic or operative means. Current imaging modalities, such as CT and MRI can provide an accurate diagnosis [16]. DLs appear on CT as a well-circumscribed hypodense lesion with a density ranging from -60 to -120 HU [59]. As fat suppression techniques effectively reduce the macroscopic fat signal, they are preferred in order to diagnose lipomas with MR [16]. Lipomas have high-intensity on T1-weighted images and usually present intermediate intensity on T2-weighted images. The loss of signal on fat-suppressed images enables the final diagnosis by MRI [16]. Though CT and MRI are helpful in diagnosis but these are unable to precisely locate the origin of the lesion. Direct visualization at endoscopy provides the clues about the nature of the tumour. In most cases, endoscopy has become the choice for diagnosis, either by the appearance of a pedunculate mass of fat or of a lesion stretching the sub-mucosa and when the mucosa is uncovered the shiny yellow colour of the lipoma becomes apparent "the naked fat sign" [44]. But it is generally insufficient in making a definitive diagnosis by endoscopy if the lipoma is submucosal or subserosal. EUS is effective to provide information about the original layer, echogenicity, the depth and invasion [34]. The typical EUS findings for DLs are intense homogeneous hyperechoic mass originating from the submucosa, with echo attenuation behind and/or inside the rear area [58]. If the lipoma is within reach of the endoscope, a biopsy forcep can be used to prove the diagnosis. Before biopsy of the putative lipoma, however, the diagnosis might be suspected. The "naked fat sign", "pillow sign" and "tenting sign" [17] have been said to be pathognomonic.

The asymptomatic DL can be observed, but symptomatic DL needs treatment. It can be excised endoscopically or operatively. The pedunculated, small, solitary lipoma can be easily and safely removed by either "snare" polypectomy or "endoloop" [3,4,7]. For large and sessile lesions, endoscopic excision may prove technically difficult and increase the risk of bleeding and perforation [60]. These types

of lipomas are difficult to manage using endoscopic techniques, thus surgical excision would be the preferred approach. If the nature of the lesion cannot be ascertained or clinical presentation such as intussusception, surgery is required. Operative management is mainly divided into four procedures, excision of the lipoma via a duodenotomy [11,12,16,23,26], segment bowel resection [20], PSD [14] or bypass [18,32]. The type of procedure chosen to perform depends on the patient's condition as well as the size and position of the tumour. The localization of the tumour is the key step and can be done by intraoperative endoscopy, where endoscopic transillumination aids in locating the exact site of the lesion or in identifying the "naked fat sign" [23] when the lipoma is subserosal. Most of the cases are managed by opening the duodenum and resected the mass according to our review. For periampullary neoplasms, local resection of the tumour with plastic repair of Oddi sphincter or pancreatoduodenectomy is recommended. Pancreas-sparing duodenectomy was performed in one case because the lipomas invaginated into the duodenojejunal flexure and the patient had a history of obstructive jaundice [20]. However, the standard pancreatoduodenectomy is not suitable for DL unless the ampullary carcinoma coexists. Gastrostomy, jejunostomy with a T-tube stented the common duct is recommended to prevent the anastomotic leakage. In case the excision of the entire duodenum is not safe, a bypass to the lesion is recommended [18]. Laparoscopy has been recently described for the management of DL, which is a minimally invasive mode of surgical management with minimal postoperative pain and short hospitalization [28,44]. Robotic technology has been shown the technical advantages to facilitate complex resection and reconstruction during periampullary procedures [61].

## CONCLUSION

DL is a rare kind of gastrointestinal tumour. Patients may be asymptomatic or present with gastrointestinal bleeding, intussusceptions or bowel obstruction. The successful diagnostic means are CT, MRI, endoscopy and EUS. Many of these lesions require surgical resection as a result of their size and location. Since, DL is a kind of benign tumour, it might be more desirable to employ the less invasive endoscopic excision or laparoscopy excision whenever this is possible.

## REFERENCES

- O'Riordan BG, Vilor M, Herrera L. Small bowel tumours: an overview. *Dig Dis*. 1996;14(4):245-57.
- Lee KJ, Kim GH, Park DY, Shin NR, Lee BE, Ryu DY, et al. Endoscopic resection of gastrointestinal lipomas: a single-center experience. *Surg Endosc*. 2014;28(1):185-92.
- In Ho J, Young Hee M. Safe techniques for endoscopic resection of gastrointestinal lipomas. *Gastric Cancer*. 2010;10(4):254-58.
- Tsou YK, Liu NJ, Jan YY. Biliary obstruction caused by hemobilia after endoscopic sphincterotomy in a patient with an anomalous location of papilla of Vater. *Gastrointest Endosc*. 2008;68(6):1232-34.
- Zirpe D, Wani M, Tiwari P, Ramaswamy PK, Kumar RP. Duodenal lipomatosis as a curious cause of upper gastrointestinal bleed: a report with review of literature. *J Clin Diagn Res*. 2016;10(5):PE01-PE4.
- Kadaba R, Bowers KA, Wijesuriya N, Preston SL, Bray GB, Kocher HM. An unusual cause of gastrointestinal bleeding: duodenal lipoma. *Case Rep Gastroenterol*. 2011;5(1):183-88.
- Tung CF, Chow WK, Peng YC, Chen GH, Yang DY, Kwan PC. Bleeding duodenal lipoma successfully treated with endoscopic polypectomy. *Gastrointest Endosc*. 2001;54(1):116-17.
- Knight CD, Black BM. Duodenojejunal intussusception due to lipoma: report of a case. *Proc Staff Meet Mayo Clin*. 1951;26:320-23.
- Blanchet MC, Arnal E, Paparel P, Grima F, Voiglio EJ, Caillot JL. Obstructive duodenal lipoma successfully treated by endoscopic polypectomy. *Gastrointest Endosc*. 2003;58(6):938-39.
- Fawcett NW, Bolton VL, Geever EF. Multiple lipomas of the stomach and duodenum. *Ann Surg*. 1949;129(4):524-27.
- Kirkland WG, Boyer RA. Multiple lipomas of the duodenum: a case report. *Gastroenterology Res*. 1951;19(1):142-47.
- Deeths TM, Madden PN, Dodds WJ. Multiple lipomas of the stomach and duodenum. *Am J Dig Dis*. 1975;20(8):771-74.
- Devlies F, Van HL, Leemans AM, Ponette E, Paeppe ID. Gastroduodenal lipomatosis. *Eur Radiol*. 1997;7(3):338-40.
- Lundell L, Hyltander A, Liedman B. Pancreas-sparing duodenectomy: technique and indications. *Eur J Surg*. 2002;168(2):74-77.
- Liu X, Wilcox CM, Nodit L, Audrey J, Lazenby. Multiple gastrointestinal stromal tumours and lipomatosis. *Arch Pathol Lab Med*. 2008;132(11):1125-29.
- Kovac JD, Dunjic MK, Bjelovic M, Banko B, Liic G, Milenkovic R, et al. Magnetic resonance imaging features of multiple duodenal lipomas: a rare cause of intestinal obstruction. *Jpn J Radiol*. 2012;30(8):676-79.
- Weinstock LB, Axelbaum J, Norman E. Duodenal lipomatosis. *Gastrointest Endosc*. 2013;77(6):954.
- Jayasundara J, Sellahewa CS, Hall AD, Patel RT. A case of gastroduodenal lipomatosis. *Ann R Coll Surg Engl*. 2016;98(8):e203-e5.
- Zirpe D, Wani M, Tiwari P, Ramaswamy PK, Kumar RP. Duodenal lipomatosis as a curious cause of upper gastrointestinal bleed: a report with review of literature. *J Clin Diagn Res*. 2016;10(5):PE01-PE4.
- Spalding DR, Isla AM, Thompson JN, Williamson RC. Pancreas-sparing distal duodenectomy for infrapapillary neoplasms. *Ann R Coll Surg Engl*. 2007;89(2):130-35.
- Lee TH, Kim WJ. A duodenal lipoma with a long stalk. *Korean J Intern Med*. 2013;28(3):383.
- Megibow AJ, Redmond PE, Bosniak MA, Horowitz L. Diagnosis of gastrointestinal lipomas by CT. *AJR Am J Roentgenol*. 1979;133(4):743-45.
- Wichendu PN, Dodi-Manuel A. Gastric outlet obstruction from duodenal lipoma in an adult. *Niger J Surg*. 2013;19(2):79-81.
- Bilgic Y, Altinsoy HB, Yildirim N, Alatas O, Kanat BH, Sahin A. Familial abdominal and intestinal lipomatosis presenting with upper GI bleeding. *Case Rep Gastrointest Med*. 2015;2015:123723.
- Knoop RF, Richter-Schrag HJ, Walker C, Thimme R, Fischer A. Double-scope resection of a large duodenal polyp. *Endoscopy*. 2015;47 (Suppl 1):E627-28.
- McGrath FP, Moote DJ, Langer JC, Orr W, Somers S. Duodenojejunal intussusception secondary to a duodenal lipoma presenting in a young boy. *Pediatr Radiol*. 1991;21:590-91.
- Michel LA, Ballet T, Collard JM, Bradpiece HA, Haot J. Severe bleeding from submucosal lipoma of the duodenum. *J Clin Gastroenterol*. 1988;10(5):541-45.
- Parmar AK, Bibyan M, Khandelwal R. Laparoscopic management of a large duodenal lipoma presented as gastric outlet obstruction. *Journal of the Society of Laparoendoscopic Surgeon*. 2013;17:459-62.
- Krachman MS, Dave PB, Gumaste VV. Bleeding duodenal lipoma. *J Clin Gastroenterol*. 1992;154(2):180-81.
- Sou S, Nomura H, Takaki Y, Nagahama T, Matsubara F, Matsui T, et al. Hemorrhagic duodenal lipoma managed by endoscopic resection. *J Gastroenterol Hepatol*. 2006;21(2):479-81.
- Allison TD, Babcock JR. Lipoma of the duodenum causing melena. *Ann Surg*. 1948;127(4):754-56.
- Duthie HL, Forrest AP. Submucosal lipoma of the duodenum. *Br J Surg*. 1957;45(190):201-02.
- Mifuji-Moroka R, Iwasa M, Sugimoto R, Katsurahara M, Fujita N, Kobayashi Y, et al. Education and imaging. Hepatobiliary and pancreatic: Liver abscess associated with lipoma of duodenum. *J Gastroenterol Hepatol*. 2012;27(6):1129.
- Malouf AJ, Patel RB. Sonographic appearance of a duodenal bulb lipoma with CT and MRI correlation. *J Ultrasound Med*. 1991;10(8):461-64.
- Efe C, Purnak T, Ozaslan E, Kucukciloglu Y. Which is the best approach for the hemorrhagic duodenal lipoma: endoscopic resection or surgery? *Am J Surg*. 2012;203(4):558.
- Cao D, Sun X, Du J, Sun Y. Duodenal lipoma associated with ectopic duodenal glands. *Clin Pract*. 2011;1(4):e128.
- Murata A, Osoegawa T, Ijyu M, Kanayama K, Tanaka M, Nakamura K. Pedunculated duodenal lipoma treated with endoscopic polypectomy with a detachable snare. *Fukuoka Igaku Zasshi*. 2008;99(6):131-35.
- Jennings BS, Doerr RJ, Buffalo. Duodenal lipoma causing intussusception. *Surgery*. 1989;105(4):560-63.
- Lemer J. Haemorrhage from a polypoid lipoma of duodenum. *Proc R Soc Med*. 1971;64(4):395.
- Yaman I, Derici H, Paksoy S. Symptomatic duodenal lipoma with endoscopic snare polypectomy. *Ulus Cerrahi Derg*. 2014;30(2):103-05.
- Chang CW, Chu CH, Shih SC, Chen MJ, Yang TL, Chang WH. Duodenal polypoid lipoma with bleeding. *Am J Surg*. 2010;200(4):e49-50.
- Weiss A, Mollura JL, Profy A, Cohen R. Two cases of complicated intestinal lipoma. Review of small intestinal lipomas. *Am J Gastroenterol*. 1979;72(1):83-88.
- Whetstone MR, Zuckerman MJ, Saltzstein EC, Boman D. CT diagnosis of duodenal lipoma. *The American Journal of Gastroenterology*. 1985;80(4):251-52.
- Abu Daff SN, Abu Daff NS. Laparoscopic enucleation of a duodenal lipoma, with review of the literature. *Saudi Med J*. 2008;29(3):455-57.
- Agha FP, Dent TL, Fiddian-Green RG, Braunstein AH, Nostrant TT. Bleeding lipomas of the upper gastrointestinal tract. A diagnostic challenge. *Am Surg*. 1985;51(5):279-85.
- Munson FA. Duodenal lipoma. A report of two cases with a review of the literature. *Am J Gastroenterol*. 1972;58(6):613-18.
- Hizawa K, Kawasaki M, Kouzuki T, Aoyagi K, Fujishima M. Unroofing technique for the endoscopic resection of a large duodenal lipoma. *Gastrointest Endosc*. 1999;49(3 Pt 1):391-92.
- Sarma DP, Weillbaeher TG, Basavaraj A, Reina RR. Symptomatic lipoma of the duodenum. *J Surg Oncol*. 1984;25(2):133-35.
- Imamura K, Fuchigami T, Iida M, Ohgushi H, Omae T, Kimura Y, et al. Duodenal lipoma--a report of three cases. *The American Society for Gastrointestinal Endoscopy*. 1983;29(3):223-24.

- [50] Barr WBJ, Yamashita T. Lipoma of the duodenum causing massive melena. *Am J Gastroenterol.* 1964;41:418-22.
- [51] Yong P, Bing-Yin Z, Tao W, Li-Jun T, Fu-Zhou T. Unroofing and grasp-and-snare techniques in the management of a large, duodenal lipoma by duodenoscope combined with a double-channel endoscope. *Gastrointest Endosc.* 2014;79(1):27.
- [52] Lukash WM, Osborne DP, Brown LT, Russo JF. Lipoma of duodenum. Report of a case. *Am J Gastroenterol.* 1968;49(6):494-98.
- [53] Thorlacius H, Weiber H, Ljungberg O, Nielsen J, Toth E. Endoscopic diagnosis and treatment of a giant duodenal lipoma presenting with gastrointestinal bleeding. *Endoscopy.* 2013;45 Suppl 2 UCTN:E385-86.
- [54] Ouwerkerk HM, Raber, Freling G, Klaase JM. Duodenal lipoma as a rare cause of upper gastrointestinal bleeding. *Gastroenterology Res.* 2010;3(6):290-92.
- [55] Smith FR, Mayo CW. Submucosal lipomas of the small intestine. *Am J Surg.* 1950;80(7):922-28.
- [56] Carney JA, Stratakis CA. Stromal, fibrous, and fatty gastrointestinal tumours in a patient with a *PDGFRA* gene mutation. *Am J Surg Pathol.* 2008;32(9):1412-20.
- [57] Jeong IH, Maeng YH. Gastric lipomatosis. *J Gastric Cancer.* 2010;10(4):254-58.
- [58] Chen HT, Xu GQ, Wang LJ, Chen YP, Li YM. Sonographic features of duodenal lipomas in eight clinicopathologically diagnosed patients. *World J Gastroenterol.* 2011;17(23):2855-59.
- [59] Genchellac H, Demir MK, Ozdemir H. Computed tomographic and magnetic resonance imaging findings of asymptomatic intra-abdominal gastrointestinal system lipomas. *J Comput Assist Tomogr.* 2008;32(6):841-47.
- [60] Yu HG, Ding YM, Tan S, Luo HS, Yu JP. A safe and efficient strategy for endoscopic resection of large, gastrointestinal lipoma. *Surg Endosc.* 2007;21:265-69.
- [61] Downs-canner S, Van der vliet WJ, Thoolen SJ. Robotic surgery for benign duodenal tumours. *J Gastrointest Surg.* 2015;19:306-12.

**PARTICULARS OF CONTRIBUTORS:**

1. Assistant Professor, Department of General Surgery, The Affiliated Hospital of Hangzhou Normal University, HangZhou, Zhejiang, China.
2. Professor, Department of General Surgery, The Affiliated Hospital of Hangzhou Normal University, HangZhou, Zhejiang, China.
3. Assistant Professor, Department of General Surgery, The Affiliated Hospital of Hangzhou Normal University, HangZhou, Zhejiang, China.
4. Assistant Professor, Department of General Surgery, The Affiliated Hospital of Hangzhou Normal University, HangZhou, Zhejiang, China.

**NAME, ADDRESS, E-MAIL ID OF THE CORRESPONDING AUTHOR:**

Dr. Ming Rong Hu,  
NO.126, Wenzhou Road, Gongshu District, HangZhou-310015, Zhejiang, China.  
E-mail: hmr2012 @163.com

Date of Submission: **Feb 21, 2017**Date of Peer Review: **Apr 12, 2017**Date of Acceptance: **May 05, 2017**Date of Publishing: **Jul 01, 2017****FINANCIAL OR OTHER COMPETING INTERESTS:** None.