

JOURNAL OF CLINICAL AND DIAGNOSTIC RESEARCH

How to cite this article:

SHARMA AK, BHANOT R, BANSAL P, KAPOOR D. AESTHETIC MANAGEMENT OF PROCLINED MAXILLARY CENTRAL INCISORS WITH ALL CERAMIC CROWNS. *Journal of Clinical and Diagnostic Research* [serial online] 2010 December;4;3643-3647

Available from

http://www.jcdr.in/article_fulltext.asp?issn=0973-709x&year=2010&volume=4&issue=6&page=3643-3647&issn=0973-709x&id=1030

CASE REPORT - DENTISTRY

Aesthetic Management Of Proclined Maxillary Central Incisors With All-Ceramic Crowns : A Case Report

SHARMA A K*, BHANOT R**, BANSAL P***, KAPOOR D****

ABSTRACT

Maxillary anterior crowns provide an exciting challenge to our artistic and technical abilities and call upon our knowledge of the smile design principles of proportion, symmetry, harmony and tooth morphology. Smile rejuvenation can positively impact a patient's self-esteem and emotional health through an improved appearance. Metal-free crowns can allow for highly aesthetic solutions such as colour correction/ matching and allow us to reshape malformed teeth, or reshape teeth which are in incorrect arch positions, to more closely approximate their correct shapes. The development of reinforced ceramics and non-metallic post systems has made possible the generation of metal-free ceramic restorations in severely compromised anterior and posterior teeth. This article will describe a case where all-ceramic crowns were utilized to restore proclined discoloured central incisors.

Keywords: aesthetics , metal- free crowns , Procera ceramics, anterior crowns,

*Professor and H.O.D, **Professor, ***Reader, **** Senior lecturer. Department of prosthodontics Dasmesh institute of research and dental sciences Faridkot, Punjab, (India)
Corresponding Author:
Dr. Akshey kumar Sharma, (Professor and H.O.D)
Department of prosthodontics, Dasmesh institute of research and dental sciences, Faridkot-151203 Punjab, (India).
Email: - draksheys@gmail.com
Mobilen: - +919814504334

Introduction

Metal ceramic systems represent a high-strength treatment which is associated with long term success, but they have several disadvantages, mainly in term of aesthetics and biocompatibility. Over the past decade, a number of novel all-ceramic systems have been developed, with the capability of restoring anterior, posterior and multiple units. The search for a new method have driven, in part, by patients who have increasingly high expectations of aesthetic dentistry and who also have concerns about the intraoral biocompatibility of metals [1]. Metal-free crowns can allow for highly aesthetic solutions such as colour correction/ matching and allow us to reshape malformed teeth or reshape teeth which are in incorrect arch positions, to more closely approximate their correct shapes.

Recent developments in dental materials have led to the introduction of a large number of all-ceramic systems for full-coverage restorations. Some systems use a single layer glass-ceramic material (e.g., Dicor, Dentsply/Chalk; IPS Empress, Ivoclar/Vivadent), whereas others have a dual layer design (In-Ceram, Vident; Porcera, Nobel Biocare) [2]. Further improvements in high strength all-ceramic technology have been achieved with the advent of computer aided design and milling (CAD/CAM) systems. The Procera system which was first introduced in 1993, is one such system [3]. This type of all ceramic crowns resists fracture during function or parafunction, both in the anterior and posterior regions, even under high stress [4].

The design and manufacture of this restoration involves optical scanning and digitalizing of the dies which are created from a master impression of the prepared teeth and cores, to precisely duplicate the margins of the tooth preparation. The scanned 3-dimensional images of the die are then used to design the substructure, which is prompted by the computer software (CAD). The CAD unit is linked to a robotic CAM centre, which creates a coping to the design specifications [1].

The clinical evaluation of all-ceramic crowns

have been promising and a success rate of 98.4% over a period of 2- 3.5 years has been reported.³ Recently, a 100% satisfaction rate among patients who were treated with all-ceramic crowns has been reported [4]. The following case report describes the aesthetic repositioning and restoration of maxillary central incisors with the Procera all-ceramic crowns.

Case Report

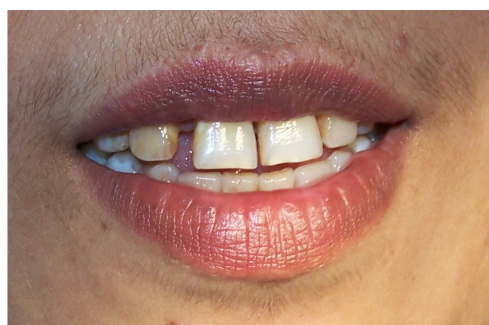A 38 years old woman who was in good health was referred because her maxillary central incisors were protruded labially and were discoloured. She wanted an immediate aesthetic treatment to improve her looks and smile. [Table/Fig 1] and [Table/Fig 2] During the treatment planning session, the patient was given the option of orthodontic treatment, since she also had spacing between her maxillary anterior teeth or endodontic treatment followed by metal-free restorations. Since she did not have any objection about the spacing between her anteriors and wanted to maintain the natural spaces, she opted for metal-free restorations as she wanted the central incisors to be corrected only and chose to have the two central incisors restored by Procera Alumina system.

The occlusion was analyzed preoperatively, both clinically and with the aid of mounted models on a semi-adjustable articulator. A diagnostic wax-up was completed and modified at the chairside with the patient's input and the final form of the new restorations was deemed to be aesthetically satisfactory.

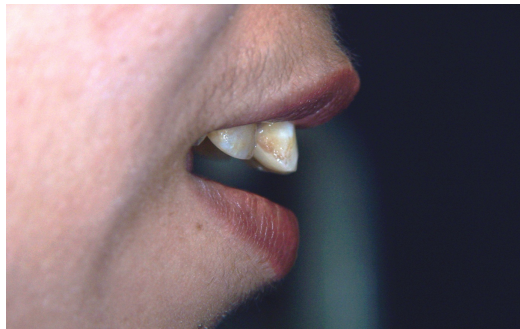After the endodontic treatment was completed with 11 and 21 glass fibre post (H Nordin SA, Swiss) with composite core (Multicore HB, Ivoclar/Vivadent AG, Liechtenstein) builtup was done palatally to reinforce the crown, since the heavy labial reduction had to be done to bring the teeth into the aesthetic zone. The abutment teeth were prepared by using modified shoulder diamond burs (coarse and superfine) [Table/Fig 3].Retraction was done by placing a small unimpregnated retraction cord (Ultrapack#000,Ultradent,South Jordan,Utah), followed by a second cord(Ultrapack#00,Ultradent) which was impregnated with a haemostatic solution(Hemodent,Ultradent).The final maxillary arch impression was made with a combination of heavy and light viscosity polyvinyl

siloxane(Take 1,Kerr). An impression of the opposing arch was also made with irreversible hydrocolloid (Jeltrate, Dentsply/Caulk). An interocclusal record at the maximum intercuspitation and a face bow transfer were obtained. The Shade was determined with a shade guide (Vitapan 3D Master Vita Bad Sackingen, Germany). The patient was given provisional restorations which were made from a bis-acryl material (Intergrity,Dentsply/Caulk,Konstanz, Germany) and was cemented with non-eugenol temporary cement (Tempcem, Equinox Medical Tec. B.V., Holand).

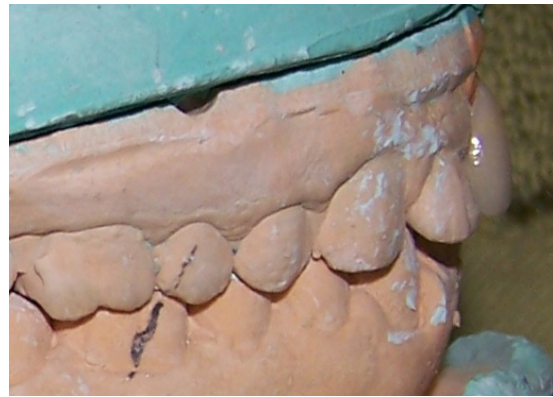The Procera crowns were returned from the dental laboratory [Table/Fig 4] and [Table/Fig 5] The crowns were examined on an uncut solid model for fit and contacts [Table/Fig 6] In the next appointment, the temporary crowns were removed, both the abutments were cleaned of the temporary cement and the crowns were tried in both individually and together to assess the marginal fit and contacts. The patient previewed and approved the shape and the shade of the crowns. Both the Procera crowns were cemented with a reinforced glass ionomer luting cement (GC Fuji Plus,GC, Alsip,III.) [Table/Fig 7], [Table/Fig 8], [Table/Fig 9] and [Table/Fig 10]. Postoperative care instructions were given to the patient and recall appointments were scheduled.



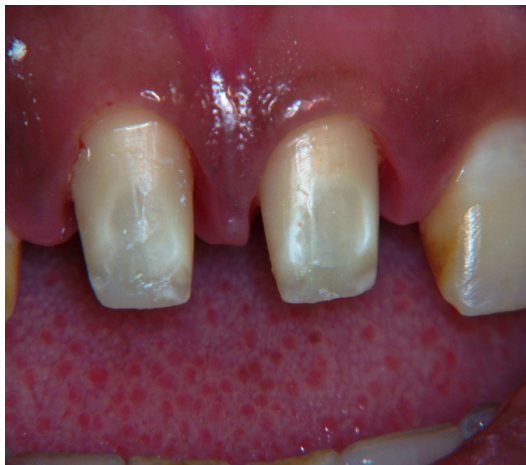(Table/Fig 1)Proclined central incisors labial view.



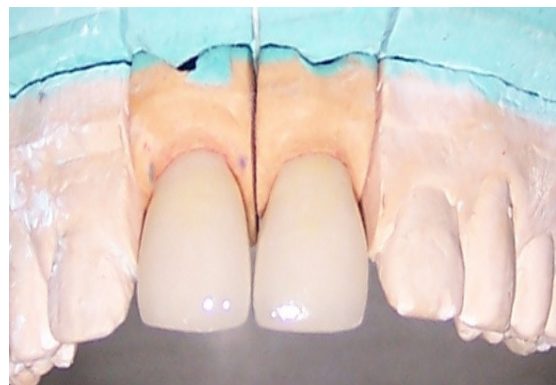(Table/Fig 2) Profile view showing discoloured 11.



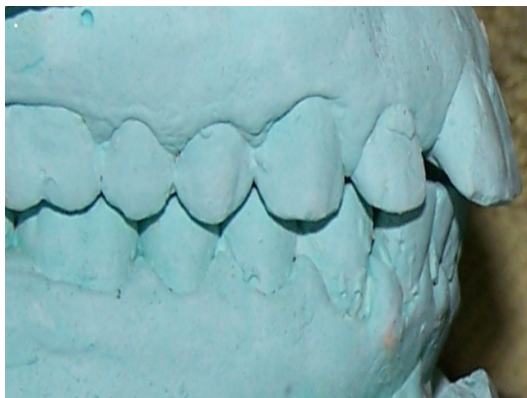(Table/Fig 5) Post treatment cast with crowns showing degree of repositioning.



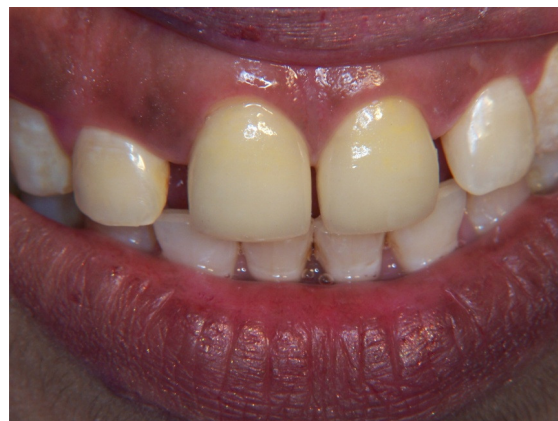(Table/Fig 3) Prepared abutments 11&21



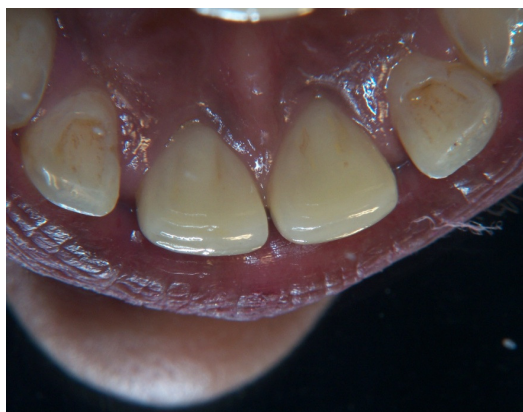(Table/Fig 6) Crowns on cast to check for fit and contacts



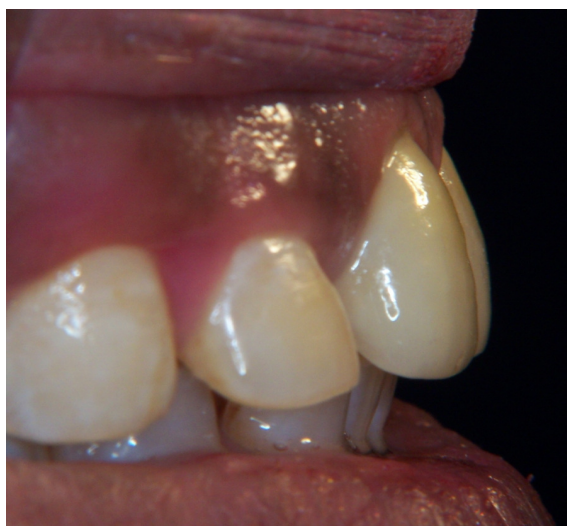(Table/Fig 4) Pre treatment model, showing proclined 11&21



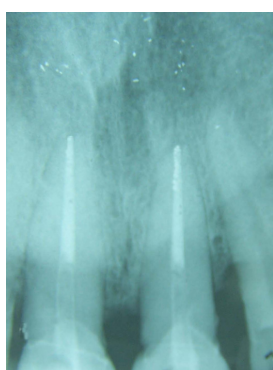
(Table/Fig 7) Labial view of restored crowns



(Table/Fig 8) Intraoral view of the crowns



(Table/Fig 9) Profile view of crowns



(Table/Fig 10) Radiograph after final cementation.

Discussion

All-ceramic systems offer a promising alternative for the restorations of the anterior teeth, and short term clinical evaluations have demonstrated high success rates [5],[6].The Procera system is a CAD/CAM system which

is used for the creation of anterior and posterior crowns and fixed partial dentures . The fabrication of the alumina coping requires the scanning of the die, designing of the substructure with the computer aid, milling of the 99.5% pure aluminium oxide(Al_2O_3) block and sintering. According to the manufacturer, the substructure has a fracture resistance of about 680MPa. It is veneered with compatible feldspathic porcelain to achieve the desired contour and aesthetics [2]. The marginal gaps of Procera crowns are within the range of clinical acceptance, from 36 μm to 83 μm [7].Because the fitted surface of the aluminous oxide coping is microscopically rough, there is little to be gained by acid etching; the surface treatment of the fitted surface is therefore usually restricted to sandblasting and the application of the silane-coupling agent. A translucent composite cement such as Panavia 21TC (J. Morita) has been suggested as the cement of choice, yielding impressive aesthetic results. This product is supplied with a priming agent, and coupling with a total etch procedure is recommended [8]. Although the sintered aluminum oxide coping is dense, it still permits some light transmission/ translucency for increased aesthetics (unlike traditional Porcelain Fused to Metal crowns). These optical properties give the clinician the ability to mask dark dentinal stains, amalgam buildups and metallic post and cores, without the need for subopaquers. Cementation can be accomplished with a variety of luting agents such as Zinc Phosphate cement, resin cements, or glass ionomer cements [9]. Glass ionomer cement has been advocated for use in cases of suboptimal moisture control. This material has been shown to transmit light somewhat more readily [6].

Reports from in vitro studies and some clinical trials indicate that the Procera system holds great promise. It yields high-strength copings with veneering ceramics of excellent aesthetic value. Given the metal-free nature of the prosthesis, the incidence of allergic reactions among the patients is likely to be lower than in cases where metal prostheses are used [1],[6].

Conclusion

Metal-free crowns can allow for highly aesthetic solutions such as colour correction/ matching and allow us to reshape malformed teeth or reshape teeth which are in incorrect

arch positions, to more closely approximate their correct shapes. These types of cases can be very satisfying to our artistic natures and can psychologically and functionally benefit our patients. The results achieved in this case indicate the potential value of the Procera system in creating restorations with excellent marginal fit and aesthetics. However, further long term clinical trials will be required to support this preliminary conclusion.

References

- [1] Barnfather KD, Brunton PA. Restoration of upper dental arch using Lava all-ceramic crown and bridgework. *Br. Dent J* 2007;202(12):731-35.
- [2] Polack MA. Restoration of maxillary incisor with zirconia all-ceramic system: a case report. *Quintessence Int.* 2006;37(5):375-80.
- [3] Zitzman NU, Galindo ML, Hangman E, Marinello CP. Clinical evaluation of Procera AllCeram crowns in anterior and posterior regions. *Int J Prosthodont* 2007;20(3):239-41.
- [4] Haselton DR, Diaz-Arnold AM, Hilis SL. Clinical assessment of high-strength all-ceramic crowns. *J Prosthet Dent* 2000;83(4):396-401.
- [5] Lopes GC, Baratieri LN, Calderia de Andrada MA, Maia HP. All-ceramic post core, and crown: technique and case report. *J Esthet Restor Dent* 2001;13(5):285-95.
- [6] Oden A, Andersson M, Krystek-Ondracek I, Magnusson D. Five-year clinical evaluation of Procera AllCeram crowns. *J Prosthet Dent* 1998;80(4):450-56.
- [7] Kokubo Y, Ohkubo C, Tsumita M, Miyashita A, Vult von Steyern P, Fukushima S. Clinical marginal and internal gaps of Procera AllCeram crowns. *J Oral Rehabil* 2005;32(7):526-30.
- [8] Sieber C. A key to enhancing natural esthetics in anterior restorations: the light-optical behavior of Spinell luminates. *J Esthet Dent* 1996;8(3):101-6.
- [9] Oden A., Razzoog ME. Masking Ability of Procera All Ceram copings of various thickness Maxillary anterior crowns provide an exciting Connection Part 1 : Biologic Variables *J Esthet Dent* 6(1): 3-9 1994 16.