

Photogrammetric Correlation of Face with Frontal Radiographs and Direct Measurements

GUNJAN NEGI¹, SWAROOPA PONNADA², N.K.S. ARAVIND³, PRASAD CHITRA⁴

ABSTRACT

Introduction: Photogrammetry is a science of making measurements from photographs. As cephalometric analysis till date has focused mainly on skeletal relationships, photogrammetry may provide a means to reliably assess and compare soft tissue and hard tissue measurements.

Aim: To compare and correlate linear measurements taken directly from subject's faces and from standardized frontal cephalometric radiographs and to correlate them with standardized frontal facial photographs of Indian population and to obtain mean values.

Materials and Methods: A cross-sectional study was conducted on 30 subjects of Indian origin. Frontal cephalograms and standardized frontal photographs were obtained from subjects in the age group of 18- 25 years. Vernier calipers were used to obtain facial measurements directly. Photographs and radiographs were uploaded and measured using Nemoceph

software. Analogous cephalometric, photographic and direct measurements were compared by one-way ANOVA to assess Pearson correlation coefficients for 12 linear measurements (6 vertical, 6 horizontal). Bonferroni post-hoc test was done for pair wise comparison.

Results: Among all measurements used, O_R-O_L (orbitale right-orbitale left) showed a high correlation $r = 0.76, 0.70, 0.71$. There was moderate correlation with En_R-En_L (endocanthion rt – endocanthion lt) $r = 0.62, 0.68, 0.68$. Highly significant correlation was evident with $N-Sn, En_R-En_L$ and Ag_R-Ag_L with $p < 0.001$.

Conclusion: A statistically significant correlation was found between photographic, radiographic and direct measurements. Therefore, photogrammetry has proven to be an alternative diagnostic tool that can be used in epidemiologic studies when there is a need for a simple, basic, non-invasive and cost-effective method.

Keywords: Frontal cephalograms, Modified protractor, Nemoceph, Photogrammetry

INTRODUCTION

Harmonious facial aesthetics is considered as one of the goals of orthodontic treatment. Angle was the first who gave importance to the soft tissue profile [1]. He believed malocclusion could annihilate the profile of an individual. Anthropologists have measured the human skull and face for more than 100 years [2]. In 1931, Broadbent from USA and Hofrath from Germany introduced roentgenographic cephalometrics, which provided a method of obtaining the measurements of cranio-facial anatomy [3]. Today in clinical practice, cephalometrics constitutes a gold standard method [4] in obtaining information about the relationship between skeletal and dental structures but it might not be practical for large-scale epidemiologic studies. One of the major drawbacks of cephalometric radiography is the radiation dose absorption and secondly, landmark identification and evaluation of soft tissue measurements from frontal cephalograms. Where cephalometrics provided only hard tissue measurements and lateral soft tissue analysis, advent of a method for evaluation of frontal soft tissue characteristics was required. Other than cephalometric analysis, various other methods were used like anthropometry, two dimensional or three dimensional photogrammetry (scanning digital 3D photogrammetry) and three dimensional methods such as laser surface and three dimensional imaging techniques. Out of the methods mentioned two-dimensional photogrammetry has proved to be a quick, basic, non-invasive and cost-effective method which provides a permanent record of the face that can be accessed later. Photogrammetry is a science of making measurements from photographs. The method was developed by Sheldon WA and introduced in the field of orthodontics by Stoner MM who compared pre- and post- treatment profiles photographs of 34 patients exhibiting Class II div 1 and 2 and Class III malocclusion

with ideal profiles [5,6]. Numerous studies have been conducted on comparing reference distances of soft tissue with that of lateral cephalograms [7-10]. The reliability of landmarks by superimposing the photograph and lateral cephalogram was evaluated by Philips C et al., [11]. They found drawbacks with the superimposition method because of lack of standardization in recording the photographs and magnification factor in cephalograms.

Studies comparing frontal photographs with frontal radiographs and comparing them with direct measurements have not been undertaken till date as a recent literature search in databases like PubMed and the Cochrane Review did not show results.

The aim of this study was to compare linear photogrammetric measurements taken from standardized frontal facial photographs of Indian population with measurements taken directly from the subject's faces and frontal cephalograms.

MATERIALS AND METHODS

A cross-sectional study was carried out in the Department of Orthodontics and Dentofacial Orthopaedics, Army College of Dental Sciences, Secunderabad from 21st August 2016 to 28th November 2016 among 30 individuals between 18-25 years. The study protocol was approved by the Institutional Ethics Committee of Army College of Dental Sciences, Secunderabad, Telangana, India. The procedure was explained to the patients and a written consent was obtained from them. Standardized frontal cephalograms and photographs were obtained from all subjects. Subjects with Class I occlusion and well-balanced faces of Indian origin with BMI under normal range (18.5–22.9 kg/m²) were included. All teeth were present till first molars. Subjects with facial and/or dental asymmetry on visual examination, history of orthodontic or orthognathic

treatment and history of craniofacial trauma or congenital anomalies were excluded from the study. A brief questionnaire to determine the state of residence and origin of the patient was obtained.

Photographic Procedure

Frontal photographs were taken with the help of a digital camera (Canon EOS 1300D) mounted with a macro portrait lens (Canon EF 100 mm f/2.8 Macro USM). The distance between subjects and the camera was 5 feet [Table/Fig-1]. The subjects were photographed in Natural Head Position (NHP) with lips at rest. To obtain NHP, the subjects were asked to look straight in front of the camera. A modified protractor with a plumb line was used to ensure parallelism of interpupil line with the floor [Table/Fig-2a]. It was placed on the nose tip and soft tissue pogonion to record NHP angle [Table/Fig-2b].

A metallic scale was placed parallel to the mid-sagittal plane of the subject with a help of an adjustable rod. Stainless steel spokes were attached to the scale at a distance of 20 cm, which helped in indicating the true vertical [Table/Fig-3a]. Spokes were used for image calibration.

The facial landmarks were identified on the subjects face by palpating manually [Table/Fig-3b] followed by placement of adhesive steel balls of 1/8" for easy identification on photographs. The steel balls were placed at trichion (Tri), glabella (G), nasion (N), orbitale (O), zygoma (Zyg), gnathion (Gn), pogonion (Pog) and menton (Me) [Table/Fig-4].

Radiographic Procedure

Digital frontal radiographs were taken with an X Mind PanoD+ cephalostat with exposure parameters of 73 kv, 10 mA and 20 sec. The radiographs of the subjects were taken in NHP in standing position with lips at rest. The position of the subjects head was evaluated with the help of the same modified protractor to ensure NHP that was achieved at the time of recording the photograph.

The protractor was placed parallel to the inter-pupillary line and the head was adjusted such that the plumb line was at 90°. The protractor was then placed at the nose tip and soft tissue pogonion and the head adjusted to achieve the same NHP angle which was measured when photographs were recorded. As discussed above the scale was placed parallel to the mid-sagittal plane of the patient with a plumb line for image calibration.

Direct Facial Measurements

The facial landmarks were palpated manually by the observer. Linear measurements were recorded on the subjects face with the help of a digital Vernier caliper in centric relation with relaxed lips and natural head orientation [Table/Fig-5]. Six horizontal and six vertical measurements were recorded [Table/Fig-6].

Computer Assessment

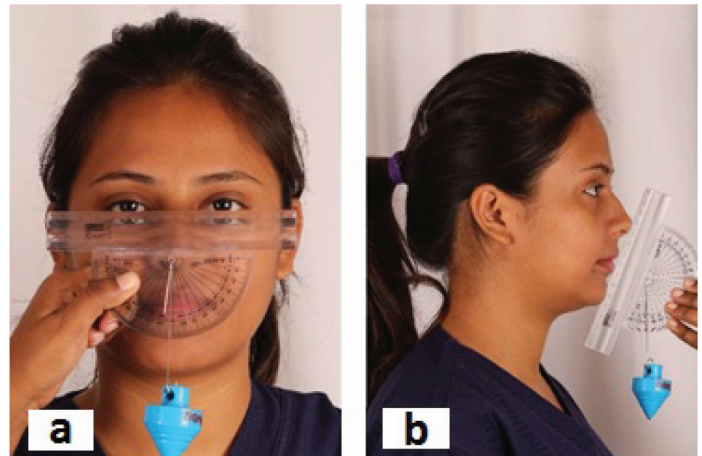
The photographic and radiographic records were analysed using Nemoceph software (Nemotech, Madrid, Spain) for Windows operating system. Photographic standardization was obtained keeping a distance of 5 feet between lens focal plane and subject similar to the distance in lateral cephalometric radiographs. Image calibration was performed in Nemoceph software prior to analysis with the inbuilt distance calibration mechanism. The program analysed the landmarks on photographs as well as cephalograms. The images were calibrated and measurements obtained with minimum error [Table/Fig-7].

STATISTICAL ANALYSIS

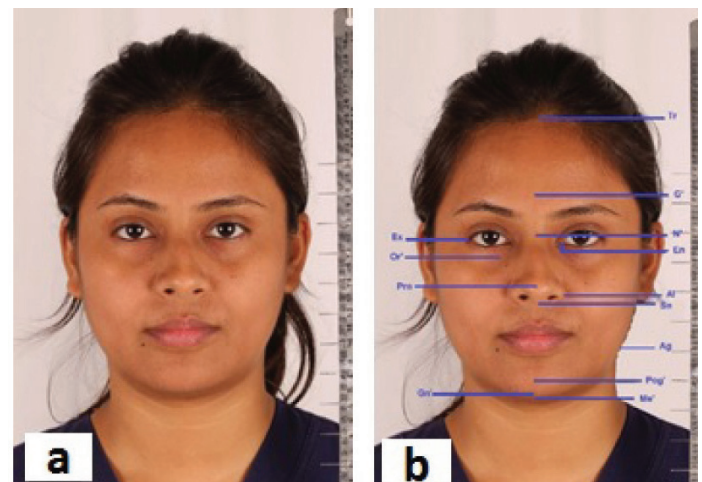
Descriptive statistical analysis (mean, standard deviation) of the linear horizontal and vertical measurements were carried out. The photographic, cephalometric and direct measurements were compared by one-way ANOVA. The three measurements were



[Table/Fig-1]: Photographic room: Distance of 5 feet maintained between the subject and camera.

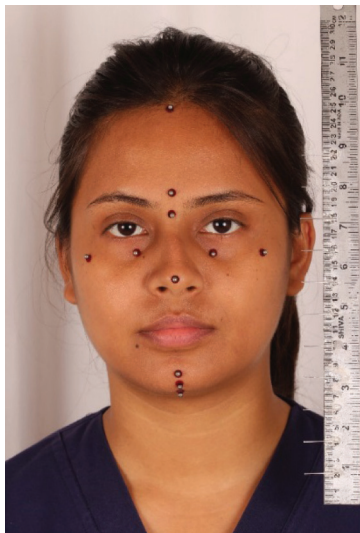


[Table/Fig-2]: a) Modified protractor adapted to a plumb line to evaluate head posture. The protractor was placed parallel to the inter-pupil ear distance and the head was adjusted as such that the plumb line lies at 90 degrees. b) Recording NHP angle with the help of modified protractor.

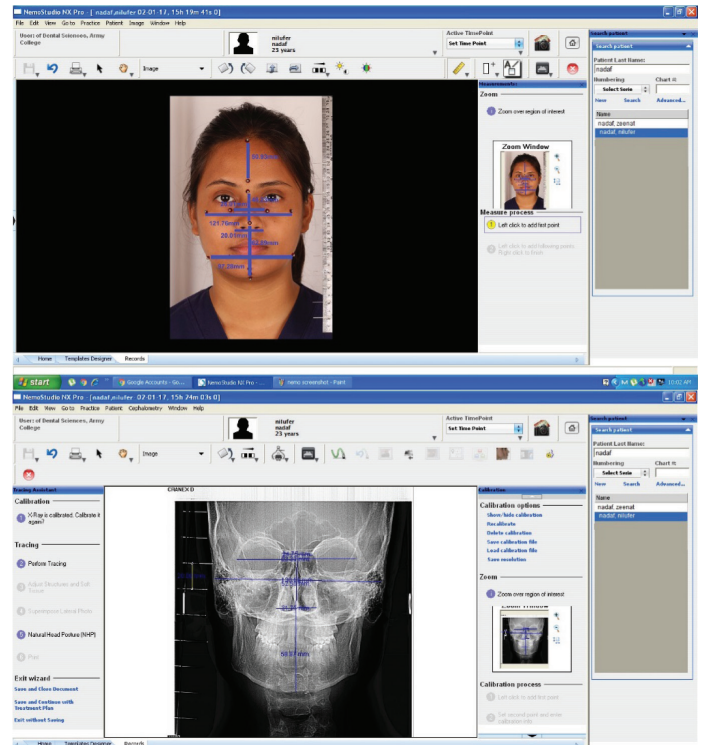


[Table/Fig-3]: a) Metallic scale with stainless steel spokes attached to the scale at a distance of 20cm. b) Landmarks identified on face.

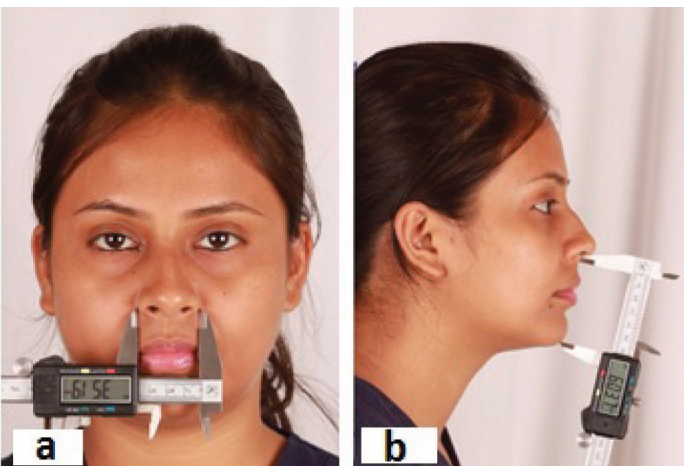
compared to assess the Pearson correlation coefficients. Correlation coefficient greater than $r = 0.7$ depicted strong correlation and a p -value < 0.05 showed highly significant correlation. Bonferroni post-hoc test was done for pair wise comparisons.



[Table/Fig-4]: Facial landmarks marked with steel balls.



[Table/Fig-7]: Nemoceph software measuring facial parameters on photograph and radiograph.



[Table/Fig-5]: Horizontal a) and vertical b) measurements recorded with digital Vernier caliper.

showed highest significance when comparison was done between photographs and radiographs ($p < 0.001$) and radiographs with direct method ($p = 0.004$). Also high significance was seen with $Zyg_R - Zyg_L$ when photographs were compared with direct measurements and radiographs were compared with direct measurements ($p = 0.017$).

Highest significance was shown by $Ag_R - Ag_L$ with all the three methods (photograph versus radiograph $p < 0.001$, photograph versus direct $p = 0.001$ and radiograph versus direct $p = 0.007$).

In vertical parameters, strong significance was shown by $Sn - Pog$ when photograph and direct method was compared ($p = 0.0050$) and high significance was shown by $N - Sn$ with all the three methods (photograph versus radiograph $p < 0.001$, photograph versus direct $p < 0.001$ and radiograph versus direct $p < 0.001$).

Hence, it was concluded that $Ag_R - Ag_L$ in horizontal parameters and $N - Sn$ in vertical parameters are highly significant when compared with all the three methods.

Correlation assessment of horizontal and vertical parameters was done by Karl Pearson coefficient [Table/Fig-10]. In horizontal parameters, strong correlation was shown by $Ex_R - Ex_L$ when radiographs with direct measurements were compared ($r = 0.9020$) and $Zyg_R - Zyg_L$ when photographs were compared with direct measurements ($r = 0.8380$). $Ala_R - Ala_L$ showed moderate correlation when photographs and radiographs and photographs and direct measurements were compared ($r = 0.6630, 0.6570$).

$En_R - En_L$ showed moderate correlation with all the three methods (photograph versus radiograph $r = 0.6270$, photograph versus direct $r = 0.6860$ and radiograph versus direct $r = 0.6810$) whereas $Or_R - Or_L$ showed strong correlation with all the three methods (photograph versus radiograph $r = 0.7610$, photograph versus direct $r = 0.7010$ and radiograph versus direct $r = 0.7180$).

While assessing vertical parameters, $N - Sn$, $Sn - Pog$ and $Pog - Me$ showed strong correlation when photographs were measured with direct measurements ($r = 0.76, 0.7970$ and 0.7150). Also strong correlation was found with $N - Me$ and $Pog - Me$ when radiographic measurements were compared with direct measurement ($r = 0.9020, 0.8270$).

High correlation was found for $Or_R - Or_L$ $r = 0.76$ (radiographic versus photographic), 0.70 (photographic versus direct) and 0.71

S. No.	Horizontal Measurements	Symbols
1.	Endocanthion right – endocanthion left	$En_R - En_L$
2.	Exocanthion right – exocanthion left	$Ex_R - Ex_L$
3.	Orbitale right – orbitale left	$Or_R - Or_L$
4.	Bizygomatic width	$Zyg_R - Zyg_L$
5.	Alar base width	$Ala_R - Ala_L$
6.	Antegononial notch right – antegononial notch left	$Ag_R - Ag_L$

S. No.	Vertical Measurements	Symbols
1.	Nasion-Subnasale	$N - Sn$
2.	Subnasale-Menton	$Sn - Me$
3.	Nasion-Menton	$N - Me$
4.	Nasion-Pogonion	$N - Pog$
5.	Subnasale-Pogonion	$Sn - Pog$
6.	Pogonion-Menton	$Pog - Me$

[Table/Fig-6]: Linear horizontal and vertical measurements.

RESULTS

Means, standard deviations and standard errors of all measurements are summarized in [Table/Fig-8]. On assessment of horizontal parameters, highly significant correlation was evident with $En_R - En_L$ and $Ag_R - Ag_L$ and with $N - Sn$ in vertical parameters ($p < 0.001$). Significant correlation was found with $Ala_R - Ala_L$ ($p = 0.004$), $Or_R - Or_L$ ($p = 0.0460$), $Zyg_R - Zyg_L$ ($p = 0.01$), $Sn - Me$ ($p = 0.0420$) and $Sn - Pog$ ($p = 0.0080$).

Pair wise comparison of three methods was done by Bonferroni post-hoc test [Table/Fig-9]. On evaluating horizontal parameters, $En_R - En_L$

S.No.	Horizontal Parameters	Photographic method			Radiographic method			Direct method			p-value
		Mean	SD	Std. Error	Mean	SD	Std. Error	Mean	SD	Std. Error	
1.	En _R -En _L	31.68	3.91	1.24	24.88	3.04	0.96	28.30	2.95	0.93	<0.001*
2.	Ex _R -Ex _L	95.40	4.46	1.41	100.52	12.18	3.85	99.70	8.16	2.58	0.247
3.	O _R -O _L	48.87	3.59	1.14	50.96	3.79	1.20	48.40	4.05	1.28	0.046*
4.	Zyg _R -Zyg _L	121.67	6.45	2.04	117.32	7.50	2.37	126.15	5.27	1.67	0.010*
5.	Ala _R -Ala _L	35.23	3.77	1.19	29.72	1.68	0.53	34.40	1.17	0.37	0.004*
6.	Ag _R -Ag _L	97.20	5.90	1.87	77.55	5.38	1.70	86.80	3.42	1.08	<0.001*

S.No.	Vertical Parameters	Photographic method			Radiographic method			Direct method			p-value
		Mean	SD	Std. Error	Mean	SD	Std. Error	Mean	SD	Std. Error	
1.	N-sn	57.57	3.1	0.98	54.34	3.0	1.02	51.35	2.94	0.93	<0.001*
2.	Sn-Me	61.5	6.53	2.07	56.20	3.33	1.05	4.65	1.47	0.0420*	
3.	N-Me	95.4	4.46	1.41	100.52	12.18	3.85	99.70	8.16	2.58	0.2470
4.	N-Pog	92.8	3.1	1.01	91.2	3.01	1.02	89.7	4.6	2.58	0.1280
5.	Sn-Pog	59.74	6.13	1.94	54.45	3.48	1.10	54.45	4.14	1.31	0.0080*
6.	Pog-Me	9.52	1.93	0.61	9.67	2.27	0.72	10.75	1.65	0.52	0.0840

[Table/Fig-8]: Comparison of horizontal and vertical parameters by one way ANOVA. * Denotes- significant values; ** denotes- highly significant values.

S. No.	Horizontal Parameters	p value		
		Photographic vs. Radiographic	Photographic vs. Direct	Radiographic vs. Direct
1.	En _R -En _L	0.0001**	0.0140	0.0040*
2.	Ex _R -Ex _L	0.7740	0.0486	1.0000
3.	O _R -O _L	0.2660	1.0000	0.0690
4.	Zyg _R -Zyg _L	0.3790	0.0090*	0.0170*
5.	Ala _R -Ala _L	0.0220	1.0000	0.0010
6.	Ag _R -Ag _L	0.001**	0.0010**	0.0070**

S. No.	Vertical Parameters	p value		
		Photographic vs. Radiographic	Photographic vs. Direct	Radiographic vs. Direct
1.	N-sn	<0.001**	<0.001**	0.001**
2.	Sn-Me	0.1030	0.2610	1.0000
3.	N-Me	0.7740	0.0486	1.0000
4.	N-Pog	0.6740	0.0462	1.0000
5.	Sn-Pog	0.0640	0.0050*	1.0000
6.	Pog-Me	1.0000	0.0590	0.0820

[Table/Fig-9]: Pair wise comparison by Bonferroni posthoc test for horizontal parameters and vertical parameters. * denotes- significant values; ** denotes- highly significant values.

S. No.	Horizontal Parameters	r Value		
		Photographic vs. Radiographic	Photographic vs. Direct	Radiographic vs. Direct
1.	En _R -En _L	0.6270*	0.6860*	0.6810*
2.	Ex _R -Ex _L	0.1070	0.0920	0.9020**
3.	O _R -O _L	0.7610**	0.7010**	0.7180**
4.	Zyg _R -Zyg _L	0.3220	0.8380**	0.3080
5.	Ala _R -Ala _L	0.6630*	0.6570*	0.4890
6.	Ag _R -Ag _L	0.4350	0.3340	0.2500

S. No.	Vertical Parameters	r Value		
		Photographic vs. Radiographic	Photographic vs. Direct	Radiographic vs. Direct
1.	N-sn	0.329	0.76**	0.3570
2.	Sn-Me	0.1940	0.3750	0.0910
3.	N-Me	0.1070	0.0920	0.9020**
4.	N-Pog	0.2540	0.4820	0.4820
5.	Sn-Pog	0.3200	0.7970**	0.4270
6.	Pog-Me	0.4930	0.7150**	0.8270**

[Table/Fig-10]: Correlation among three methods of assessment of horizontal and vertical parameters by Karl Pearson's coefficient method. * denotes- significant values; ** denotes- highly significant values.

(radiographic versus direct) and a moderate correlation was found in En_R-En_L r =0.62 (radiographic versus photographic), 0.68 (photographic versus direct) and 0.68 (radiographic versus direct).

DISCUSSION

Photogrammetry is very useful in determining facial asymmetry. A study by Taylor HO et al., using 3-dimensional photogrammetry for asymmetry determination in 100 subjects determined that asymmetry detection was relatively easy using the 3-dimensional method [12]. However, the video stereophotogrammetric method requires extensive equipment and is impractical to use in situations assessing a relatively large number of subjects. In clinical practice, cephalometric analysis constitutes the gold standard for diagnoses and treatment planning. However, use of photogrammetry in the field of orthodontics can aid in epidemiologic studies where a quick, easy and cost effective diagnostic tool is required. With increasing concerns about radiation safety and need to minimize radiation exposure to the extent possible, this technique is useful. Images can also be used multiple times for additional studies as and when required.

Our findings suggested that photographic analysis could be used as an alternative when cephalograms cannot be obtained due to lack of availability of equipment, concerns with radiation exposure and in analysis of large number of samples in epidemiological studies. Facial symmetry determination and analysis of facial proportion was assessed by Yeung CYC et al., in a study on 12-year-old Southern Chinese to determine norms [13]. The norms for the group were determined and sexual dimorphism between males and females was also evident. The study proves the reliability of the photogrammetric method.

Conversely, this method has some drawbacks, such as errors in head posture. A slight deviation from NHP may cause an error to occur. It is essential for the perioral muscles to relax while taking photographs as muscle constriction or lip straining may cause inadvertent error.

The age group in our study (18-25 years) was selected because majority of orthodontic patients fall under this category and age related changes have not yet started. The subjects selected had normal BMI as soft tissue thickness in obese patients could mask accuracy of identification of landmarks. Highly significant correlations

($p < 0.001$) were found between photographic and radiographic method and Karl Pearson correlation coefficient ranged from 0.09 to 0.84 i.e., correlation was strong for few measurements i.e., O_R-O_L (orbitale rt- orbitale lt) $r = 0.76, 0.70, 0.71$.

De Carvalho et al., compared lateral cephalograms with profile photographs of 123 subjects and found A'N'B' angle was most effective amongst the other measurements in explaining variability [8].

Moshkelgosha V et al., compared linear and angular measurements in frontal and profile photographs of Persian population and found sexual dimorphism in the nose, lips and chin [9]. Our study compared photographs, radiographs and direct measurements to find correlations.

Photographs with direct measurements were compared by Farkas LG et al., where they concluded the reliability of 26 landmarks out of 62 [14].

Enlow DH et al., conducted a study where photographs and radiographs of Black and White subjects were compared with each other. The study concluded correlation between the samples due to consistency of the soft tissue thickness [15].

Staudt CD et al., found good reliability ($r=0.08$) for ANB on comparing radiographs with photographs of 29 skeletal Class III and 13 Class I patients [16].

In 2005 Peng J et al., studied craniofacial anatomy correlation in female twins and concluded that there was a strong genetic component with vertical facial height measurement [17].

Future application of photogrammetric analysis can focus on genetic epidemiologic studies, as resemblance in facial appearance has been noticed within families.

LIMITATION

The sample size in the study was limited. Male and female comparisons were not made. Moreover, soft tissue thickness could not be considered in the study as it could show variations from patient to patient. Future studies should consider possible differences between sexes while formulating norms with a larger sample size.

CONCLUSION

Significant correlations were evident in horizontal measurements in the study. Interorbital distance, endocanthion distance and antegonial notch distances were similar. Vertically, nasal height showed strong

correlation. The findings will be relevant while planning treatment in Indian population groups since normal values for Indian population are now available. Photogrammetry was found to be a quick, easy and cost effective, alternative diagnostic tool. Evaluation of facial measurements in large samples can be carried out accurately using this method. With increasing evidence on effects of radiation exposure, this non invasive method could effectively be used for facial assessment during treatment planning.

REFERENCES

- [1] Angle EH. Classification of malocclusion. Dental Cosmos. 1899;41(18):248-64, 350-57.
- [2] Broca P. Horizontal survey of the skull. Bull Soc Anthropol Paris, 1878.
- [3] Broadbent BH. A new x-ray technique and its application to orthodontia. Angle Orthod. 1981;51:86-88, 93-114.
- [4] Heil A, Lazo Gonzalez E, Hilgenfeld T, Kickingereeder P, Bendszus M, Heiland S, et al. Lateral cephalometric analysis for treatment planning in orthodontics based on MRI compared with radiographs: A feasibility study in children and adolescents. PLoS One. 2017; 2(3):e0174524.
- [5] Sheldon WA. The varieties of human physique. New York:Harpers, 1940.
- [6] Stoner MM. A photometric analysis of the facial profile. Am J Orthod. 1955;41:453-69.
- [7] Aksu M, Kaya D, Kocadereli I. Reliability of reference distances used in photogrammetry. Angle Orthod. 2010;80(4):482-89.
- [8] De Carvalho Rosas Gomes L, Horta KO, Gandini LG Jr, Gonçalves M, Gonçalves JR. Photographic assessment of cephalometric measurements. Angle Orthod. 2013;83(6):1049-58.
- [9] MoshkelgoshaV, FathinejadS, PakizehZ, ShamsaM, GolkariA. Photographic Facial Soft Tissue Analysis by Means of Linear and Angular Measurements in an Adolescent Persian Population. Open Dent J. 2015;9:346-56.
- [10] Fernández-Riveiro P, Suárez-Quintanilla D, Smyth-Chamosa E, Suárez-Cunqueiro M. Linear photogrammetric analysis of the soft tissue facial profile. Am J Orthod Dentofacial Orthop. 2002;122(1):59-66.
- [11] Philips C, Greer J, Vig P, Matteson S. Photocephalometry: errors of projection and landmark location. Am J Orthod Dentofacial Orthop. 1984;86:233-43.
- [12] Taylor HO, Morrison CS, Linden O, Phillips B, Chang J, Byrne ME, et al. Quantitative facial asymmetry: using three-dimensional photogrammetry to measure baseline facial surface symmetry. J Craniofac Surg. 2014;25(1):124-28.
- [13] Yeung CYC, McGrath C, Wong R, Yang Y, Hagg U, Lo J. Frontal facial proportions of 12-year-old southern Chinese: a photogrammetric study. Head Face Med. 2015;11:26.
- [14] Farkas LG, Bryson W, Klotz J. Is photogrammetry of the face reliable? J Plast Reconstr Surg. 1980;3:346-55.
- [15] Enlow DH, Hans MG. Essentials of facial growth. 1st ed. Philadelphia: WB Saunders; 1996.
- [16] Staudt CB, Kiliaridis S. A nonradiographic approach to detect Class III skeletal discrepancies. Am J Orthod Dentofacial Orthop. 2009;136(1):52-58.
- [17] Peng J, Deng H, Cao C, Ishikawa M. Craniofacial morphology in Chinese female twins: A semi-longitudinal cephalometric study. Eur J Orthod. 2005;27:556-61.

PARTICULARS OF CONTRIBUTORS:

1. Postgraduate Student, Department of Orthodontics, Army College of Dental Sciences, Secunderabad, Telangana, India.
2. Senior Lecturer, Department of Orthodontics, Army College of Dental Sciences, Secunderabad, Telangana, India.
3. Reader, Department of Orthodontics, Army College of Dental Sciences, Secunderabad, Telangana, India.
4. Professor and Head, Department of Orthodontics, Army College of Dental Sciences, Secunderabad, Telangana, India.

NAME, ADDRESS, E-MAIL ID OF THE CORRESPONDING AUTHOR:

Dr. Prasad Chitra,
Professor and Head, Department of Orthodontics, Army College of Dental Sciences, Secunderabad-87, Telangana, India.
E-mail: prasadchitra@yahoo.co.uk

FINANCIAL OR OTHER COMPETING INTERESTS: None.

Date of Submission: **Mar 09, 2017**
Date of Peer Review: **Mar 31, 2017**
Date of Acceptance: **Apr 18, 2017**
Date of Publishing: **May 01, 2017**