

Intracorneal Amphotericin B Injection in a Case of Indolent Candidal Keratitis

JYOTI DESWAL¹, SUDESH KUMAR ARYA²

ABSTRACT

Ocular candidiasis is one of the opportunistic infection occurring in human body. Pathogenesis wise, *Candida* is very virulent and slow growing organism. We report a case of 76-year-old female with left eye candidal stromal abscess, not responding to topical and oral antifungal drugs. Patient was administered intrastromal amphotericin B injection in the affected eye. Four midstromal injections were given in the areas surrounding the corneal abscess. A total of approximately 0.05 mL of amphotericin B, 5 µg per 0.1 mL, was administered. Within next four weeks, the eye became completely quiet with healed epithelial defect and corneal scarring. Intracorneal injection of amphotericin B is a safe and effective treatment option for recurrent and recalcitrant fungal infections.

Keywords: Abscess, *Candida*, Intrastromal, Photophobia

CASE REPORT

A 76-year-old female presented with complaint of painful decrease in vision in left eye for the last one month. The decrease in vision was associated with photophobia and redness. There was no history of any trauma or entry of any foreign body in the eye. The patient was non-diabetic and did not have any systemic illness.

On examination, patient was thin built and well-nourished. Best corrected visual acuity in right eye was 6/12 and Finger Counting (FC) 1m with accurate Projection of Rays (PR) in left eye. Right eye was essentially normal except presence of immature senile cataract. In left eye, slit lamp examination revealed circumciliary congestion with thick creamish-white stromal corneal infiltrates upto 90% of corneal depth with overlying epithelial defect measuring 4 x 3.5 mm in the central part of cornea. There was surrounding stromal oedema with superficial vascularization all around the cornea. Anterior chamber reaction was 2+ with no hypopyon [Table/Fig-1].

Patient was already on treatment before coming to us. She had been putting topical moxifloxacin 0.5% and natamycin 5% at two hourly intervals along with cycloplegic and artificial tears for the past two weeks. The clinical picture was suggestive of infection caused by an indolent organism. Corneal scrapings were sent for gram stain, KOH mount and culture. KOH mount revealed presence of yeast.

The treatment was revised and topical amphotericin B (0.25%) drops were added at two hour intervals. Patient did not respond to topical antifungal treatment as the size of stromal abscess remained

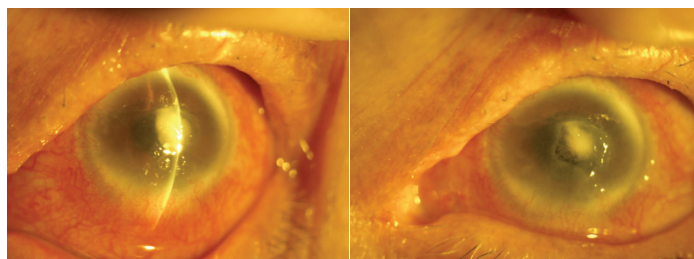
the same for next few days. The patient was then administered intrastromal amphotericin B injection in the affected eye with the patient in supine position, using a 1 mL syringe with a 30-gauge needle with bevel down. Four mid-stromal injections were given in the areas surrounding the corneal abscess in all the four quadrants, 0.5 mm away from abscess margin and upto mid-stromal depth. A total of approximately 0.05 mL of amphotericin B, 5 µg per 0.1 mL, was administered, resulting in hydration of the cornea. Within next few days, the size of stromal infiltrates reduced to 2 x 2 mm, the depth of infiltrates decreased as they were now present only in anterior stroma, size of epithelial defect decreased to 3 x 3 mm and corneal oedema and circumciliary congestion reduced markedly [Table/Fig-2].

Repeat injections were not given and patient was advised to follow same treatment regime as earlier. Within next four weeks, the eye became completely quiet with healed epithelial defect and corneal scarring. On three months follow-up, patient was asymptomatic with central macular corneal opacity of size 3 x 3 mm.

DISCUSSION

Corneal tissue is most susceptible to fungal infections amongst all the ocular tissues. In India, prevalence of fungal keratitis ranges from 7.3 to 44.8% [1]. Filamentous fungi are more prevalent in tropical regions and yeasts, specifically *Candida*, in temperate. Excessive use of antibiotics and corticosteroids, contact lens wear, trauma with vegetative matter and immunodeficiency are the risk factors for *Candida* infection [2]. *Candida* species show morphological transition between yeast and hyphal forms due to mechanism of phenotypic switching. Expression of adhesions and invasions on the cell surface, formation of biofilms and secretion of hydrolytic enzymes make *Candida* highly virulent [3].

Mainstay therapy for *Candida* infection is topical amphotericin B and oral azoles. Flucytosine and fluconazole have also been recommended for the treatment of candida infection in the eye. Topical voriconazole also has good bioavailability and activity [4]. In 1/3rd of cases, penetrating keratoplasty may be required [5]. Efficacy of amphotericin B is closely dependent on the ability to achieve its optimal levels in the cornea. So, selecting a proper formulation and mode of application is the key to improve the efficacy of amphotericin



[Table/Fig-1]: Showing thick anterior stromal corneal infiltrates with overlying epithelial defect measuring 4 x 3.5 mm in the central part of cornea.

[Table/Fig-2]: Showing reduction in size of stromal abscess three days after intrastromal injection of amphotericin B.

B. Ophthalmologists have tried site-directed drug delivery in the form of intracameral injections, intrastromal injections, and posterior sub-tenon injections [6-10]. Intracorneal drug delivery has been performed previously on animals in an experimental setting [11]. A literature search produced one report of a bioassay in rabbits in which several antifungal agents were evaluated in an effort to achieve therapeutic corneal levels [12]. In a study by Qu L et al., on rabbit model, the concentrations of amphotericin B in the cornea and aqueous humor using three different routes of administration were measured, and comparisons of concentrations with each other were made. They reported that a single intrastromal injection of amphotericin B could raise the local drug concentration in the deep cornea, high concentrations being maintained for seven days or longer. Intrastromal injection is simple, less invasive, and can directly deliver drug into the deep cornea. Intrastromal injection can be repeated after seven days or later, avoiding high injection frequency, which might cause anthropogenic trauma to the cornea. Intracameral injection may be a sort of efficacy therapy for intraocular fungal extension and corneal infection that penetrated the endothelium into the anterior chamber. But the aqueous concentrations decreased abruptly within one day after a single injection [13]. In some studies on rabbits, it is reported that intrastromal injection of amphotericin B at a concentration of less than 10 µg per 0.1 mL is safe in rabbit corneas [14], and at a concentration of 5 µg per 0.1 mL it does not appear to be deleterious to keratocytes or endothelial cells in the clinic [6]. Up to 50 µg of intracamerally injected amphotericin B is also well tolerated by rabbit eyes, and it causes only reversible iritis and clouding of the lens [15]. Consistent with our experience reported herein, intrastromal injections of amphotericin B at a concentration of 5 µg per 0.1 mL do not appear to be deleterious to corneal keratocytes or endothelial cells.

CONCLUSION

We suggest intracorneal injection of amphotericin B is a safe and effective treatment option for recurrent and recalcitrant fungal

infections. Intrastromal corneal injections of amphotericin B offer less invasive, in-office alternative to penetrating keratoplasty.

REFERENCES

- [1] Rautaraya B, Sharma S, Kar S, Das S, Sahu SK. Diagnosis and treatment outcome of mycotic keratitis at a tertiary eye care center in eastern India. *BMC Ophthalmol.* 2011;11:39-47.
- [2] Hemady RK. Microbial keratitis in patients infected with the human immunodeficiency virus. *Ophthalmology.* 1995;102:1026-30.
- [3] Mayer FL, Wilson D, Hube B. *Candida albicans* pathogenicity mechanisms. *Virulence.* 2013;4:119-28.
- [4] Sengupta J, Khetan A, Saha S, Banerjee D, Gangopadhyay N, Pal D. Candida keratitis emerging problem in India. *Cornea.* 2012;31:371-75.
- [5] Xie L, Dong X, Shi W. Treatment of fungal keratitis by penetrating keratoplasty. *Br J Ophthalmol.* 2001;85:1070-74.
- [6] Garcia-Valenzuela E, Song CD. Intracorneal injection of amphotericin B for recurrent fungal keratitis and endophthalmitis. *Archives of Ophthalmology.* 2005;123(12):1721-23.
- [7] Yilmaz S, Ture M, Maden A. Efficacy of intracameral amphotericin B injection in the management of refractory keratomycosis and endophthalmitis. *Cornea.* 2007;26(4):398-402.
- [8] Kuriakose T, Kothari M, Paul P, Jacob P, Thomas R. Intracameral amphotericin B injection in the management of deep keratomycosis. *Cornea.* 2002;21(7):653-56.
- [9] Sharma N, Agarwal P, Sinha R, Titiyal JS, Velpandian T, Vajpayee RB. Evaluation of intrastromal voriconazole injection in recalcitrant deep fungal keratitis: case series. *British Journal of Ophthalmology.* 2011;95(12):1735-37.
- [10] Sharma N, Chacko J, Velpandian T, Titiyal JS, Sinha R, Satpathy G, et al. Comparative evaluation of topical versus intrastromal voriconazole as an adjunct to natamycin in recalcitrant fungal keratitis. *Ophthalmology.* 2013;120(4):677-81.
- [11] Claudio C, Gino G. Homologous antilymphocyte antibodies synthesized by limboconal lymphoid foci during the delayed hypersensitivity phase: analysis of the limbal immunologic reaction after intracorneal injection of homosppecific spleen homogenate. *Riv Anat Patol Oncol.* 1968;33:336-50.
- [12] O'Day DM, Head WS, Robinson RD, Williams TE. An evaluation of intrastromal injection of antifungal agents. *J Ocul Pharmacol.* 1991;7:325-28.
- [13] Qu L, Li L, Xie H. Corneal and aqueous humor concentrations of amphotericin B using three different routes of administration in a rabbit model. *Ophthalmic Research.* 2010;43(3):153-58.
- [14] Qu L, Li L, Xie H. Toxicity and pharmacokinetics of intrastromal injection of amphotericin B in a rabbit model. *Current Eye Research.* 2014;39(4):340-47.
- [15] Foster JB, Almeda E, Littman ML, Wilson ME. Some intraocular and conjunctival effects of amphotericin B in man and in the rabbit. *Archives of Ophthalmology.* 1958;60(4):555-64.

PARTICULARS OF CONTRIBUTORS:

1. Senior Resident, Department of Ophthalmology, GMCH, Chandigarh, India.
2. Professor, Department of Ophthalmology, GMCH, Chandigarh, India.

NAME, ADDRESS, E-MAIL ID OF THE CORRESPONDING AUTHOR:

Dr. Jyoti Deswal,
Senior Resident, Department of Ophthalmology, H.NO. 25/10-A, Jasbir Colony (Near Sheela By-Pass), Rohtak-124001,
Haryana, India.
E-mail: jyoti_deswal@yahoo.co.in

FINANCIAL OR OTHER COMPETING INTERESTS: None.

Date of Submission: **Aug 03, 2016**
Date of Peer Review: **Nov 29, 2016**
Date of Acceptance: **Feb 05, 2017**
Date of Publishing: **May 01, 2017**