

Mechanical Ptosis in Neurofibromatosis Type 1 Heraldng the Diagnosis of Right Sided Cervical Vagus Nerve Neurofibroma: A Rare Case Report

JYOTIRANJAN MALLICK¹, SUCHETA PARIJA², BIJNYA PANDA³,
SUSANTA PUJAHARI⁴, SATYASWARUP JENA⁵

ABSTRACT

Neurofibromatosis type 1 (NF1) is an autosomal dominant, multisystem disorder. In NF1, involvement of vagus nerve can occur in the form of neurofibroma. A few cases of neurofibroma of thoracic vagus nerve have been reported while neurofibroma of cervical vagus nerve with NF1 is quite rare. A 19-year-old male came with complaints of decreased vision of both eyes and right sided drooping of eyelid since childhood. He was diagnosed as having NF1 with neurofibroma of right cervical vagus nerve.

Keywords: Café au lait spot, Lisch nodule, Phakomatosis, Plexiform neurofibroma

CASE REPORT

A 19-year-old male presented with complaints of decreased vision in eyes, right sided periorbital swelling and drooping of right upper eyelid since childhood. The loss of vision was painless and gradually progressive in nature. Right periorbital swelling and drooping of right upper eye lid was non-progressive and present since childhood. No history of trauma was present. No other family members were symptomatic.

His visual acuity was counting finger 3 meters OD and 6/60 OS. The best corrected visual acuity was found to be 6/36 OD and 6/24 OS. Intraocular pressure was recorded to be 20 mm Hg OD and 13 mm Hg OS.

On examination right sided ptosis was found which was characteristically 'S' shaped. Examination revealed right sided periorbital swelling and along with bony dysplasia in sphenoid region. Extraocular movements were full and normal in all directions. Anterior segment examination revealed clear cornea, deep anterior chamber, normal pupillary reaction and clear lens. Multiple lisch nodules (>2) were found on iris on slit lamp examination in both eyes. Dilated fundus evaluation was within normal limits.

Examination revealed he had multiple dark brown pigmentations (café au lait spots) on skin (>6 in number). The greatest measured spot was about 5cm in diameter. It was associated with progressively enlarging multiple small nodular growths which initially were less in number but as age advanced the number and size of nodules increased. Subcutaneous nodules were of size 1-5 cm, mostly on the face, trunk and lower back region. A nodular swelling (5x4cm) on right upper eyelid was also found which on palpation felt like 'bag of worms' [Table/Fig-1].

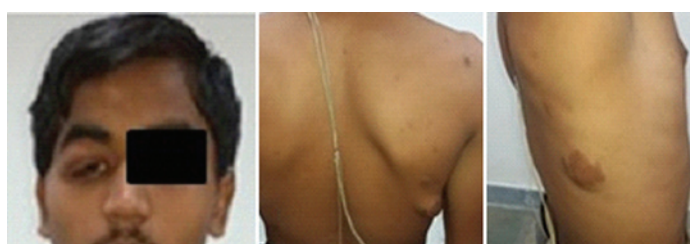
On examination he had a short stature with bilaterally asymmetrical face, right ear placed more inferiorly as compared to left side. Other systemic examination was within normal limits.

As the patient's history and clinical findings correlated with clinical diagnostic criteria of NF-1; a provisional diagnosis of neurofibromatosis- type 1 was made. Other differential diagnosis was ptosis due to 3rd CN palsy, horner syndrome, myasthenia gravis and aponeurotic ptosis.

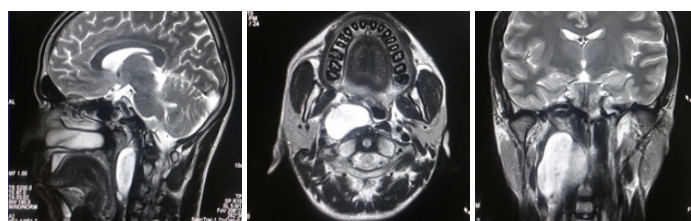Routine blood investigations, X-ray of chest and long bones, CT scan and MRI of brain and orbit was advised. MRI findings suggested a right sided vagus nerve neurofibroma in the cervical region [Table/Fig-2-4]. MRI picture showed a T1 hypointense and T2 hyperintense with areas of heterogeneity with an oblong or dumb bell shaped lesion. The lesion was pushing muscular space anteriorly, pharyngeal mucosal space medially, perivertebral space posteriorly and internal jugular vein and internal carotid artery laterally. It was in contact with carotid sheath hence likely arising from retrohyaloid parapharyngeal space or carotid space. Features suggestive of neurofibroma of right cervical vagus nerve were observed.

Optic nerve was within normal limits in both eyes. There was absence of greater wing of sphenoid bone on right side.

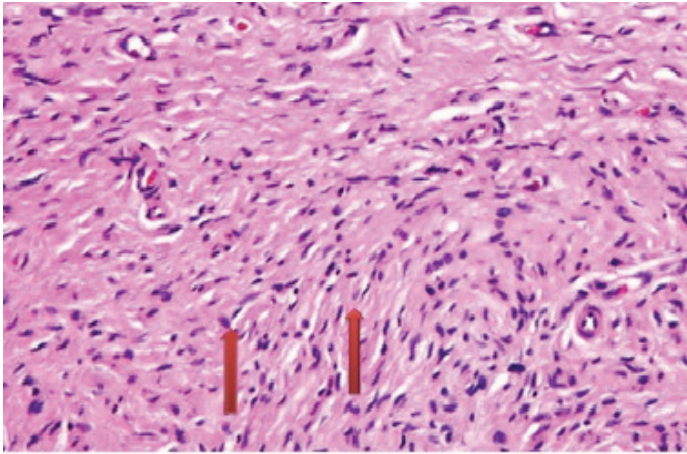
Neurofibroma of right cervical vagus nerve was resected and the histopathology confirmed the diagnosis [Table/Fig-5]. The patient was monitored for surgical debulking of neurofibroma in upper eyelid region at a later date if the ptosis increases covering the visual axis. Refractive correction and amblyopia therapy was given for decreased vision in both eyes.



[Table/Fig-1]: Right sided ptosis due to plexiform neurofibroma in eyelid, plexiform neurofibroma and café au lait spot in right infrascapular area and multiple café au lait spots in the trunk.



[Table/Fig-2]: MRI picture of vagus nerve neurofibroma (sagittal). **[Table/Fig-3]:** MRI picture of vagus nerve neurofibroma (axial). **[Table/Fig-4]:** MRI picture of vagus nerve neurofibroma (coronal).



Wavy schwann cells

[Table/Fig-5]: Histology of vagus nerve neurofibroma (red arrow).

DISCUSSION

Neurofibromatosis type 1 (NF1) is a phakomatosis which is an autosomal dominant, multisystem disorder affecting approximately 1 in 2600-3000 people.

Inheritance is autosomal dominant with irregular penetrance and variable expressivity with the gene locus on 17q11, though about 50% have new mutations. Each child of a parent with NF1 runs a 50% risk of having the disorder [1].

Pathogenesis

The NF1 gene protein product, neurofibromin is a tumour suppressor expressed mainly in neurons, glial cells, schwann cells and melanocytes. This serves as a regulator of signals for cell proliferation and differentiation by activating GTPase activity that inhibits Ras function and tyrosine kinase activity [1].

Diagnostic criteria

Presence of ≥ 2 of the following criteria are needed for diagnosis of NF1 developed by National Institute of Health [2].

- Six or more Café Au Lait Macules (CALM) >5 mm in greatest diameter at prepubertal age and >15 mm in greatest diameter in adults.
- Axillary or inguinal freckling.
- Two or more neurofibroma of any type or one plexiform neurofibroma.
- Optic glioma.
- Two or more Lisch nodules.
- A distinctive osseous lesion, e.g., sphenoid dysplasia/ thinning of cortex of long bones with or without pseudoarthrosis.
- First-degree relative (parent, sibling, offspring) with NF1 by the above criteria.

The present case had multiple (>6) café au lait spots of size >15 mm, more than 1 plexiform neurofibromas, multiple (>2) lisch nodules in both eyes and sphenoid bone dysplasia and thus fulfilling the diagnostic criteria of NF1. However none other family members were affected symptomatically.

Lisch nodules are melanocytic hamartoma and are the most common type of ocular involvement in NF-1 and usually does not cause any complication [3].

Orbit, temporal region and eye lids can be infiltrated by plexiform neurofibromas which can result in proptosis, ptosis, strabismus or change in globe length. Amblyopia secondary to these lesions is primarily from ptosis and anisometropia. Characteristics of plexiform neurofibromas of the eyelid are thickening of upper

lid, S-shaped deformity and "Bag of worms" like sensation on palpation [4].

The decreased vision in the present case was due to amblyopia which was caused by uncorrected refractive error. The visual axis in the right eye was not obstructed by the ptosis induced by plexiform neurofibroma in the upper eyelid region. The present case had a right sided periorbital swelling which on palpation gave a bag of worms like sensation. Examination revealed the neurofibroma was of plexiform type.

Optic nerve gliomas are locally invasive and slow growing tumours with low malignant potential. They involve an estimated 15-40% of children with NF-1. Bilateral optic nerve gliomas are almost pathognomonic for NF-1. Presentation is mostly in first decade with decrease in visual acuity, painless proptosis, loss of colour vision, an afferent pupillary defect and optic atrophy. CT or MRI generally shows a fusiform dilatation of the optic nerve.

Based on the clinical examination and MRI findings it was evidenced that the present case had no optic nerve involvement in the form of optic nerve glioma.

Other ophthalmological manifestations include choroid hamartomas, retinal tumours (astrocytic hamartoma), congenital glaucoma and prominent corneal nerves. The present case had no glaucomatous involvement as evidenced by normal cup to disc ratio, normal visual field and intraocular pressure. Absence of the greater wing of the sphenoid bone may lead to pulsatile proptosis.

Other features of NF1 include short stature, failure to gain weight, large head size, precocious puberty, childhood hypertension, cognitive problems, stroke, headache, brain tumours and neural problems due to the spinal cord involvement. Rarely tumours such as pheochromocytoma and juvenile chronic myeloid leukaemia may also occur.

Various investigations like X-ray of chest and long bones, CT scan of brain and orbit and MRI of brain and orbit are advised in NF1. Gliomas have a typical fusiform appearance with kinking in MRI [5]. Genetic testing can be helpful when prenatal or preimplantation diagnosis is desired.

In our case MRI findings revealed features suggestive of a neurofibroma of right vagus nerve in the cervical region. The present case had sphenoid wing dysplasia as evidenced by radiological findings [Table/Fig-2-4]. Previous literature has shown that vagus nerve neurofibromas and schwannomas have a predilection to occur in the left side. Dabir et al., suggested that this could be due to the propensity of these tumours to occur in the thickest portion of the nerve-hence the tendency to arise on the left proximal cervical vagal trunk, which is larger than that on the right side [6].

The management of NF1 requires a multidisciplinary approach. Visual prognosis depends primarily on the presence or absence of an optic nerve glioma or congenital glaucoma [7]. Medical therapy and surgical intervention (goniotomy, trabeculotomy, trabeculectomy and aqueous shunting devices) may be necessary to treat glaucoma [8].

For children with isolated optic nerve glioma and progressive symptoms, complete surgical resection may result in prolonged progression-free survival [9]. But surgical resection of gliomas is ultimately a virtual guarantee of loss of vision.

Radiotherapy may be combined with chemotherapy for tumours with intracranial extension that precludes surgical resection. However, there is no benefit of radiation therapy for optic gliomas based on analysis of visual fields.

Neurofibromas are amenable only to surgical removal. The indications of surgery for multiple neurogenic tumours in NF1 are limited to the cases which are symptomatic, enlarging or undergo malignant degeneration. Surgical debulking may be performed

for plexiform neurofibromas that produce mechanical ptosis or cosmetic deformity. However, due to the infiltrative nature of these lesions, complete excision is usually impossible and recurrence is common. The major problem at surgery for these masses is preservation of the nerve. It is often impossible to completely resect the neurofibroma while preserving the original nerve, because neurofibromas are nonencapsulated tumours containing all nerve elements, i.e. axons, sheath cells, and connective tissues.

In our case the plexiform neurofibroma in the right upper eye lid region was asymptomatic, nonprogressive and did not obstruct the visual axis due to ptosis. So careful monitoring was done. Because neurogenic tumours in NF1 carry a risk of approximately 10% for malignant transformation, surgical resection is often indicated [10].

Lateral cervical approach is the preferred surgical approach for vagus nerve neurofibroma in cervical region. This allows a wide exposure of the tumour and its complete removal. In our case the part of the vagus nerve involved by the tumour was resected and the histology confirmed it to be a neurofibroma of right sided vagus nerve [Table/Fig-5].

CONCLUSION

Correction of refractive error and amblyopia therapy was given to this patient. Periodic monitoring was done to look for the progressive nature of ptosis or any other symptoms like pain, bleeding, increase in size, or malignant transformation of neurofibromatous lesion.

Consent

The patient gave his written consent for publication of this report and accompanying images.

REFERENCES

- [1] Upadhyaya M, Cooper DN, eds. Neurofibromatosis Type 1. Berlin: Springer-Verlag; 2012.
- [2] NIH. National Institutes of Health Consensus Development Conference Statement: neurofibromatosis. Bethesda, Md, USA, July 13-15, 1987. *Neurofibromatosis*. 1988;1:172-78.
- [3] Kreusel KM. Ophthalmological manifestations in VHL and NF 1: pathological and diagnostic implications. *Fam Cancer*. 2005;4:43-47.
- [4] Lin J, Martel W. Pictorial essay: Cross-sectional imaging of peripheral nerve sheath tumours. *AJR Am J Roentgenol*. 2001;176:75-82.
- [5] Tailor TD, Gupta D, Dalley RW, et al. Orbital neoplasms in adults: clinical, radiologic, and pathologic review. *Radiographics*. 2013;33:1739-58.
- [6] Dabir RR, Piccione W, Kittle CF. Intrathoracic tumours of the vagus nerve. *Ann Thorac Surg*. 1990;50:494-97.
- [7] Dalla Via P, Opocher E, Pinello ML, et al. Visual outcome of a cohort of children with neurofibromatosis type 1 and optic pathway glioma followed by a pediatric neuro-oncology program. *Neuro Oncol*. 2007;9:430-37.
- [8] Colás-Tomás T, Gutiérrez-Díaz E, Tejada-Palacios P, et al. Management of congenital glaucoma in neurofibromatosis type 1: a report of two cases. *Int Ophthalmol*. 2010;30:211-14.
- [9] Erb MH, Uzcategui N, See RF, et al. Orbitotemporal neurofibromatosis: classification and treatment. *Orbit*. 2007;26:223-28.
- [10] Rasmussen SA, Yang Q, Friedman JM. Mortality in neurofibromatosis 1: an analysis using U.S. death certificates. *Am J Hum Genet*. 2001;68:1110-18.

PARTICULARS OF CONTRIBUTORS:

1. Senior Resident, Department of Ophthalmology, AIIMS, Bhubaneswar, Odisha, India.
2. Assistant Professor, Department of Ophthalmology, AIIMS, Bhubaneswar, Odisha, India.
3. Senior Resident, Department of Ophthalmology, AIIMS, Bhubaneswar, Odisha, India.
4. Senior Resident, Department of Ophthalmology, AIIMS, Bhubaneswar, Odisha, India.
5. Senior Resident, Department of Radiodiagnosis, IMS and Sum hospital, Bhubaneswar, Odisha, India.

NAME, ADDRESS, E-MAIL ID OF THE CORRESPONDING AUTHOR:

Dr. Jyotiranjana Mallick,
Flat 301, Plot 1173, Sai Arati Homes, Lane 2, Aerodrome Area, Bhubaneswar-751020, Odisha, India.
E-mail: jyotiran8519@gmail.com

Date of Submission: **Aug 18, 2015**

Date of Peer Review: **Oct 19, 2015**

Date of Acceptance: **Jan 31, 2016**

Date of Publishing: **Jun 01, 2016**

FINANCIAL OR OTHER COMPETING INTERESTS: None.