

# Evaluation of Patient Perceptions After Vestibuloplasty Procedure: A Comparison of Diode Laser and Scalpel Techniques

BUTCHIBABU KALAKONDA<sup>1</sup>, SANA FARISTA<sup>2</sup>, PRADEEP KOPPOLU<sup>3</sup>, KUSAI BAROUDI<sup>4</sup>, UDAYKIRAN UPPADA<sup>5</sup>, ASHANK MISHRA<sup>6</sup>, ABHISHEK SAVARIMATH<sup>7</sup>, AMARA SWAPNA LINGAM<sup>8</sup>

## ABSTRACT

**Introduction:** Inadequate vestibular depth results in poor plaque control owing to an insufficient width of keratinized gingiva. Vestibuloplasty provides the necessary vestibular depth and can be performed either with a scalpel, electrocautery or lasers.

**Aim:** To evaluate the patient perceptions related to pain and discomfort on the 1<sup>st</sup>, 3<sup>rd</sup> and the 7<sup>th</sup> day post vestibuloplasty and also assess the healing outcomes related to the treatment of inadequate vestibular depth either with the diode laser or the scalpel.

**Materials and Methods:** Twenty patients who had inadequate vestibular depth and required vestibuloplasty were assigned randomly to undergo the procedure either with the scalpel or the laser. The data obtained was analysed for intergroup

comparison with an independent paired t-test and intragroup comparison was determined by a paired t-test.

**Results:** Intragroup comparison within the laser group for VAS scores of pain and discomfort within all the reported days exhibited a significant difference ( $p < 0.05$ ). Inter group comparison revealed that the patients in the laser group had lower VAS scores for pain and discomfort compared to the scalpel group ( $p < 0.05$ ). Analysis of the three pointer scale for healing revealed that the patients in the laser group exhibited better healing outcomes on the 1<sup>st</sup>, 3<sup>rd</sup> and the 7<sup>th</sup> day compared to the scalpel group.

**Conclusion:** Observations from the study highlight the opinion that laser can be a safe and effective alternative to traditional vestibuloplasty performed with the scalpel.

**Keywords:** Clark's vestibuloplasty, Low level laser therapy (LLLT), Vestibular depth, Visual analog scale

## INTRODUCTION

A normal vestibule aids in proper plaque control and contributes to a good oral hygiene. In certain instances, an anatomical variation such as higher insertion of the muscle attachments of vestibular mentalis and other associated muscles leads to a decrease in the vestibular depth and to make matters worse, an insufficient keratinized gingiva which is a critical component for the maintenance of periodontal health [1].

The width of the keratinized gingiva and the attached gingiva required for maintaining gingival health is still a matter of discussion among periodontists worldwide. Researchers have currently agreed upon 2 mm of keratinized gingiva and 1 mm of attached gingiva as the "gold standard" for sustainment of a healthy periodontium [2].

Absence of a good vestibular depth and an insufficient amount of attached gingiva compromises adequate plaque control and paves way to pathologic consequences such as gingival inflammation, recession and pocket formation. An inadequate vestibular depth poses a series of problems for other disciplines of dentistry too. It contributes to an exaggeration of gingival inflammation associated with inability to brush around the orthodontic brackets, a matter of concern for an orthodontist. It's indeed a nightmare for a prosthodontist as patients complain of an inadequate retention of the denture. Hence an inadequate vestibular depth is a cynosure to eyes for all the specialties in dentistry.

Considering the mucogingival problem posed by an inadequate vestibular depth, an array of treatment procedures such as gingival augmentation with the use of grafts and vestibuloplasty

through a secondary epithelization have been planned to enhance the vestibular depth.

Vestibuloplasty is a mucogingival procedure that aims at the surgical modification of the gingiva-mucous membrane relationships including deepening of the vestibular trough, altering the position of the frenulum or muscle attachments, and widening of the zone of attached gingiva [3]. A variety of vestibuloplasty techniques have been advocated in literature such as Edlanplasty, Kazanjian vestibuloplasty, etc. Most of these techniques have been used as pre prosthetic procedures to enhance the vestibular depth related to edentulous denture bearing areas [4-7].

Clark's vestibuloplasty came into vogue and was more popular in enhancing the vestibular depth and also quite effective in addressing the mucogingival problem associated with the dentition [4]. Major drawbacks of these conventional vestibuloplasty procedures were the severe pain and discomfort and the delayed healing with the high chances of relapse making them less acceptable.

Periodontal procedures in the new millennium have moved on from being extensively aggressive to minimally invasive. Lasers have given the necessary impetus for such a shift by providing painless and acceptable procedures. Lasers offer an array of advantages over the traditional scalpel in providing a clean sterile field with excellent hemostasis for the clinician and by providing less pain and swelling postoperatively for the patient [8].

Advent of new technology with introduction of lasers into dentistry has enabled practitioners to use various types of lasers; Erbium: Yttrium-Aluminum-Garnet (Er: YAG), Neodymium: Yttrium-Aluminum-Garnet (Nd: YAG) and diode for vestibuloplasty

procedure [9,10]. The diode laser has been an effective choice for most clinicians worldwide owing to its compact size and affordability. Diode Lasers are semiconductor lasers with a wave length between 805 and 980nm. They are used either in continuous or pulsating modes with fiber- optic surgical tips [8,10].

## AIM

The aim of our present clinical study was to evaluate the patient perceptions and healing outcomes in the treatment of inadequate vestibular depth either with the diode laser or the scalpel.

## MATERIALS AND METHODS

### Subject Population

A total of 20 systemically healthy patients (11 males and 9 females), aged between 21 and 40 years with a mean age of  $31.42 \pm 1.56$  years were included in the study. The patients with inadequate vestibular depth and insufficient attached gingiva in the mandible which was revealed by a tension test being positive on clinical examination were included in the study. Patients with systemic diseases which compromised the normal wound healing mechanism (e.g. autoimmune disorders, diabetes etc.); smokers, pregnant and lactating mothers and patients with poor oral hygiene were excluded from the clinical study. The patients were randomly assigned to either the laser or the scalpel group. Prior to the surgical procedure, patients were explained the merits and demerits and a signed informed consent was taken.

### Study Design

The clinical study was designed and conducted at the Department of Periodontics, Maitri Dental College, Chhattisgarh from June 2014 to September 2014. The study design was in accordance with the Declaration of Helsinki and adhered to the guidelines for biomedical research on human subjects issued by Indian Council of Medical Research, New Delhi. The study design and protocol were approved by the concerned college Ethical Committee. The study protocol was appraised among the investigators.

### Criteria for Evaluation

#### Analysis of Wound Healing

Clinical evaluation of the surgical area was performed by three different investigators to analyse the wound healing by utilizing a three point scale prepared by Amorim et al., to score healing of the surgical wound at the 1<sup>st</sup>, 3<sup>rd</sup>, 7<sup>th</sup> and on the 21<sup>st</sup> day [11].

Score +1: Indicating superior healing of laser-treated wounds compared to control sites.

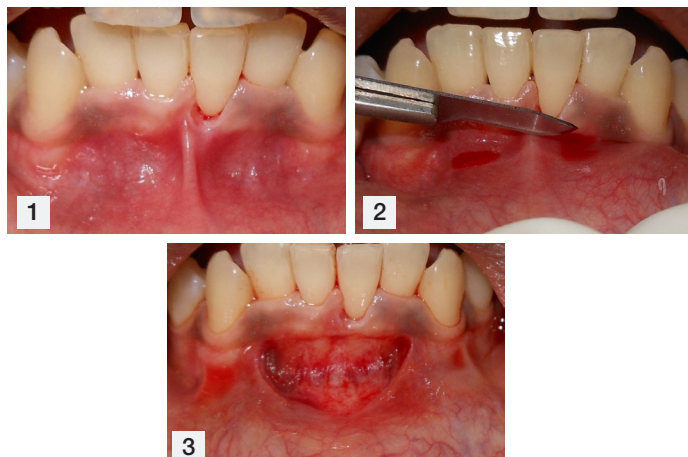
Score 0: Indicating that laser-treated test sites and control sites exhibited the same degree of healing response.

Score -1: Indicating that control exhibited superior healing when compared to laser-treated test sites.

#### Scoring Patient Perceptions

A Visual Analog Scale (VAS) was used to score the patient's perceptions related to pain and discomfort after the completion of the vestibuloplasty procedure. VAS scale comprised of a 100mm scale with "no pain" represented as "0" on the left side and 100 on the right side representing "plenty" of pain. The patient was briefed that the scores between 1 and 30 were to be recorded as slight pain and scores between 31 and 60 were presumed as moderate pain whereas scores from 61-100 perceived as severe pain [12].

VAS score for discomfort (related to regular functions like chewing and talking) was represented in a similar way like the VAS scale for pain; by "no discomfort" on the left and "plenty of discomfort" to the right. Patients in both the groups were instructed to mark between these two end points on both the scales on the 1<sup>st</sup> day as well as on the 3<sup>rd</sup> and the 7<sup>th</sup> day postoperatively.



**[Table/Fig-1]:** Inadequate vestibular depth and keratinized gingiva in the lower arch of case 1 **[Table/Fig-2]:** Incision with the scalpel to relieve the muscle fibers. **[Table/Fig-3]:** Immediate postoperative picture after scalpel vestibuloplasty.

Postoperative bleeding, swelling and any infection were assessed by a telephonic interview the day after surgery.

### Surgical Procedure

#### Clark's Vestibuloplasty

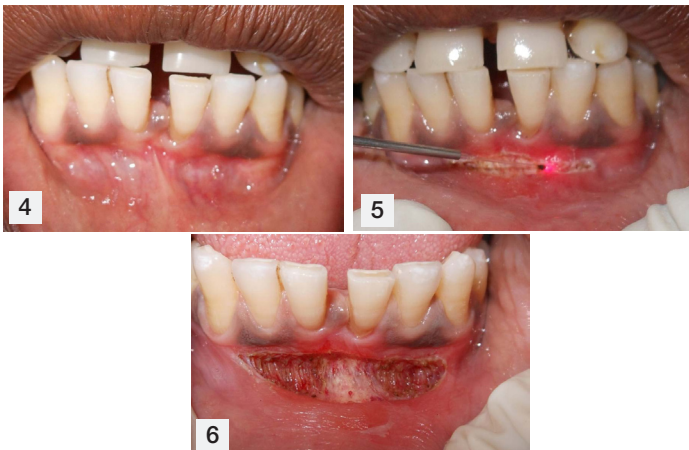
After the phase I therapy, all the necessary oral hygiene instructions were given with emphasis on proper plaque control. Prior to the procedure, width of attached gingiva and vestibular depth were recorded. Local anaesthesia was administered with 1:80,000 adrenaline bilaterally by a mental nerve block. After adequate local anaesthesia was achieved, a horizontal incision was given in the mucous membrane at the mucogingival junction with a scalpel blade no. 15. The incision was extended with sharp dissection resecting all the muscle fibers over the periosteum [Table/Fig-1-3]. After the supraperiosteal dissection, the mucosal flap was sutured at the depth of the vestibule. The periosteal surface was properly evaluated for any residual muscle and soft tissue attachments. Surgical area was properly cleaned through saline irrigation and assessment of bleeding was done before discharging the patient.

Necessary postoperative instructions were given to the patients. Antibiotics; Amoxicillin 500 mg three times a day was given for five days along with analgesics, Ibuprofen 400 mg twice daily. Plaque control was supplemented by the use of chlorhexidine rinse (0.2%) twice daily for three weeks postoperatively.

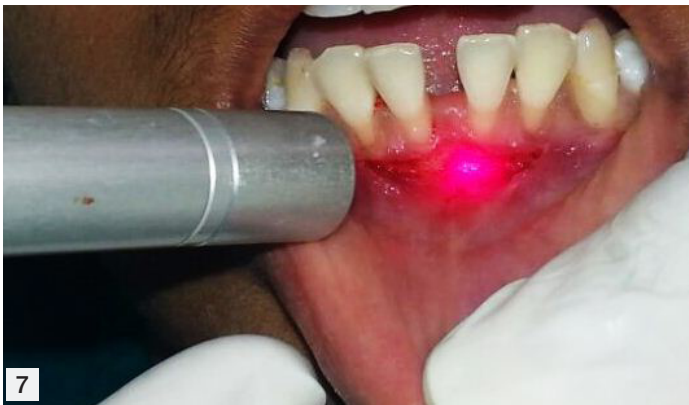#### Laser-Assisted Vestibuloplasty

Initial therapy was completed for all the patients and necessary oral hygiene instructions were given. Necessary laser protective equipment comprising of the laser safety glasses were worn by the clinician and the patient and proper precautions were taken. After application of topical anaesthetic gel and adequate anaesthesia was attained with a local infiltration anaesthesia, a 808 nm wave length diode laser (SUNNY™, MSI, Bangalore ) with 400  $\mu$ m surgical tip was used with the following settings; 1 to 1.5W in a continuous mode using an initiated tip. Ablation with the laser tip was initiated at the mucogingival junction with a horizontal stroke directing the laser parallel to the bone slowly relieving the muscle fibers till the desired depth [Table/Fig-4-6]. Tension was placed by retracting the patient's lip to enable the laser assisted excision of the muscle fibers. After a sufficient vestibular depth was established, the lip was once again pulled to assess for any residual muscle fibers and if any fibers were noticed, they were excised with the laser tip.

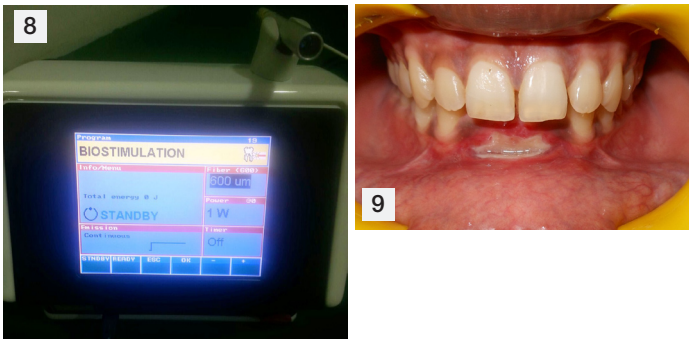
Considering the vast wound area post the vestibuloplasty procedure, Low Level Laser Therapy (LLLT) was used to enhance



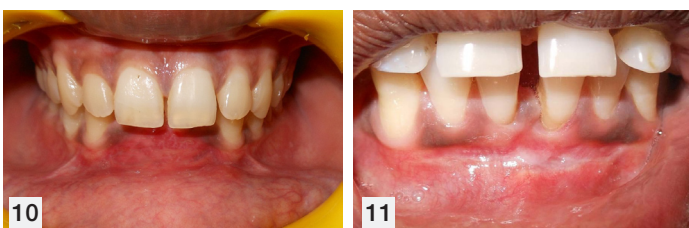
**[Table/Fig-4]:** Pre-operative view showing inadequate vestibular depth of case 2.  
**[Table/Fig-5]:** Intraoperative view during the procedure.  
**[Table/Fig-6]:** Laser assisted vestibular deepening immediate postoperative.



**[Table/Fig-7]:** LLLT used over the wound bed to enhance wound healing.



**[Table/Fig-8]:** Laser settings for biostimulation or low level laser therapy.  
**[Table/Fig-9]:** Clinical appearance after 2 weeks with noticeable slough.



**[Table/Fig-10]:** Clinical appearance after 4 weeks with enhanced vestibular depth.  
**[Table/Fig-11]:** Clinical appearance after 4 weeks with enhanced vestibular depth.

the wound healing by using a special LLLT hand piece (SUNNY™, MSI, Bangalore) with a beam diameter of 600µm provided by the company. The hand piece was used in a biostimulation mode with a power setting of 1 Watt in a defocused mode starting at a distance of 6-8 mm away from the wound area and slowly approaching within a distance of 2-3mm in a scanning motion covering the entire wound bed for a period of 30 seconds [Table/Fig-7&8]. LLLT was performed on three visits starting immediate postoperatively and on the 3<sup>rd</sup> and the 7<sup>th</sup> day. Adequate plaque

control was reinforced for patients in both the groups with the use of Chlorhexidine (0.2%) mouth rinse twice daily for three weeks postoperatively. The patients were recalled after 10 days to assess the plaque control and to reinforce any plaque control measures if necessary.

The patients in the scalpel group were recalled after 10 days for suture removal [Table/Fig-9]. Final recall for patients in both the groups was after three weeks to evaluate the final healing. Examination revealed augmentation of keratinized gingiva with establishment of a proper vestibular depth in both the groups [Table/Fig-10&11]. No periodontal dressing was given for patients in both the groups.

### STATISTICAL ANALYSIS

Statistical analysis was performed using IBM Statistical Program for Social Sciences Version 20.0 (SPSS INC., Chicago Illinois, USA). An independent t-test was used to analyse the intergroup comparison, whereas a paired t-test was used for the intragroup comparison to assess the statistical significance for pain and discomfort scores. The test values were considered significant at  $p < 0.05$

### RESULTS

Twenty one patients with inadequate vestibular depth were initially screened and 20 among them were enrolled and completed the follow up. Demographic data concerning patient's gender is represented in [Table/Fig-12].

	Scalpel	Laser
No of Subjects	10	10
Males	5	6
Females	5	4

**[Table/Fig-12]:** Demographic data for both the groups.

[Table/Fig-13] analyses the intragroup comparison of pain and discomfort VAS scores within the scalpel group. The VAS scores of pain and discomfort on the 3<sup>rd</sup> day did not show any significant difference as compared with those on the 1<sup>st</sup> day. However, when the scores from the 7<sup>th</sup> day were compared with those on the 3<sup>rd</sup> and the 1<sup>st</sup> day, a highly significant difference was found ( $p < 0.001$ ).

[Table/Fig-14] analyses a related comparison within the laser group. However, within the laser group, the difference in the VAS scores of pain and discomfort on the 1<sup>st</sup>, 3<sup>rd</sup> and the 7<sup>th</sup> day, when compared with one another, were found to be highly significant ( $p < 0.001$ ).

Comparison of the mean VAS scores of the levels of pain, for both the groups, observed on the 1<sup>st</sup>, 3<sup>rd</sup> and the 7<sup>th</sup> day of the study is summarized in [Table/Fig-15]. When both the treatment methods were compared it showed that there was a significant difference ( $p < 0.05$ ) in VAS scores of pain, on the 1<sup>st</sup>, 3<sup>rd</sup> and the 7<sup>th</sup> day, with the laser group displaying significantly lower VAS scores. Comparison of the mean VAS scores for discomfort associated with chewing and speaking, for two groups, observed on the 1<sup>st</sup>, 3<sup>rd</sup> and the 7<sup>th</sup> day of the study are briefed in [Table/Fig-15]. Further analysis suggested that there was a significant difference of the VAS scores of discomfort associated with chewing and speaking between both the groups on the 1<sup>st</sup>, 3<sup>rd</sup> and the 7<sup>th</sup> days, with the laser group displaying significantly lower VAS scores.

Analysis of wound healing utilizing the three point scale revealed that on the 1<sup>st</sup>, 3<sup>rd</sup> and on the 7<sup>th</sup> days the test sites scored '+1' but on the 21<sup>st</sup> day the test site was scored as '0' indicating that the laser assisted procedure had a better healing till the 7<sup>th</sup> day whereas on the 21<sup>st</sup> day both the groups presented a similar pattern of healing.



Scalpel group	Pain	Comparison	p-value	Discomfort	Comparison	p-value
1 <sup>st</sup> day	83.6±4.51	1 <sup>st</sup> day versus 3 <sup>rd</sup> day	0.107#	79.72±4.96	1 <sup>st</sup> day versus 3 <sup>rd</sup> day	0.109#
3 <sup>rd</sup> day	76.6±6.99	3 <sup>rd</sup> day versus 7 <sup>th</sup> day	0.001*	73.40±4.22	3 <sup>rd</sup> day versus 7 <sup>th</sup> day	0.001*
7 <sup>th</sup> day	35.0±4.51	1 <sup>st</sup> day versus 7 <sup>th</sup> day	0.001*	18.1±1.61	1 <sup>st</sup> day versus 7 <sup>th</sup> day	0.001*

**[Table/Fig-13]:** Intragroup comparison of VAS scores of pain and discomfort in scalpel group.

\* The p-value was set as significant at p<0.05

Laser group	Pain	Comparison	p-value	Discomfort	Comparison	p-value
1 <sup>st</sup> day	63.5±4.3	1 <sup>st</sup> day versus 3 <sup>rd</sup> day	0.001*	52.1±4.8	1 <sup>st</sup> day versus 3 <sup>rd</sup> day	0.001*
3 <sup>rd</sup> day	36.2±4.5	3 <sup>rd</sup> day versus 7 <sup>th</sup> day	0.001*	29.3±5.6	3 <sup>rd</sup> day versus 7 <sup>th</sup> day	0.001*
7 <sup>th</sup> day	18.0±2.0	1 <sup>st</sup> day versus 7 <sup>th</sup> day	0.001*	6.2±4.5	1 <sup>st</sup> day versus 7 <sup>th</sup> day	0.001*

**[Table/Fig-14]:** Intragroup comparison of VAS scores of pain and discomfort in laser group.

\* The p-value was set as significant at p<0.05 significant

	Pain			Discomfort		
	Scalpel	Laser	p-value	Scalpel	Laser	p-value
1 <sup>st</sup> day	83.6±4.51	63.5±4.3	0.002*	79.72±4.96	52.1±4.8	0.002*
3 <sup>rd</sup> day	76.6±6.99	36.2±4.5	0.005*	73.40±4.22	29.3±5.6	0.005*
7 <sup>th</sup> day	35.0±4.51	18.0±2.0	0.042*	18.1±1.61	6.2±4.5	0.04*

**[Table/Fig-15]:** Intergroup comparison of VAS scores of pain & discomfort.

\* The p-value was set as significant at p<0.05 significant

## DISCUSSION

Evidence from the literature substantiates the role played by various lasers like; Co<sub>2</sub>, Nd: YAG, Er, Cr: YSGG, Er: YAG and diodes in enhancement of predictable clinical outcomes related to numerous procedures in periodontal treatment [13,14]. Diode lasers owing to their compact size and affordability are used for laser assisted periodontal procedures worldwide. Literature is abundant on the use of diode lasers for various soft tissue procedures from frenectomy, gingivectomy, crown lengthening, gingival depigmentation and gingival troughing to name a few [13,15]. Our clinical study aims at evaluating patient's perceptions and the healing outcomes post vestibuloplasty either with the diode laser or the scalpel.

Various surgical techniques such as Edlanplasty, Kazanjian vestibuloplasty and Corn's periosteal separation vestibuloplasty have been used to deepen the vestibule with varying success. The major drawbacks associated with these procedures was the extent of surgical manipulation along with the necessity of suturing which leads to severe postoperative discomfort associated with swelling and pain leading to an increased morbidity and decreased acceptance of these procedures [4-7].

Lasers on the other hand had some better advantages. Unlike the amount of anaesthesia requiring a bilateral mental nerve block in a scalpel vestibuloplasty, a laser assisted vestibular deepening was performed with minimal amount of local infiltration anaesthesia. There was great precision in incision and the procedure was completed in less time as lasers permit better visualization of the surgical field by sealing the small blood vessels on contact, establishing an effective hemostasis by enhanced stimulation of factor VII for clotting, reducing the need for suturing [14,16].

Diode lasers with an effective penetration depth of 2mm in the tissues seal the small lymphatic vessels minimizing edema post surgically [15]. Most of the patients in the laser group were quite comfortable owing to less bleeding and postoperative discomfort associated with the procedure whereas four patients in the scalpel group complained of edema on telephonic interview.

The denuded periosteum in the Clark's vestibuloplasty procedure heals by secondary epithelialization delaying the wound healing [4]. Though the use of a free gingival graft can speed up the healing process; it further increases the patient's morbidity due to a second surgical site. Laser on the other hand have an added advantage in creating asepsis in the surgical field owing to the bactericidal effect of the diode laser which was highlighted in a study by Moritz

et al., who reported a significant reduction in bacteria providing a sterile wound bed with reduced risk of bacteraemia [17]. Laser also enhances wound healing by the formation of a denatured protein coagulum termed as "eschar" or "biological bandage". This layer of protein coagulum protects the wound from bacteria and friction from masticatory forces [8].

The results of our present study revealed that the patients in the laser group experienced less scar formation compared to the scalpel group. Our results take substantial claim from the studies by Nammour et al., and Zeinoun T et al., who had reported that the laser treated wound exhibits less scar formation due to a few number of myofibroblasts resulting in a minimal wound contraction compared with the scalpel wound [18,19]. The added benefit of the laser was evident in our study as it enhances establishment of a good vestibular depth due to less tissue rebound, whereas the patients in the scalpel group exhibited a poor outcome owing to more tissue rebound resulting in a poor vestibular depth post the surgical procedure.

Low level therapy was used over the wound bed post the surgical procedure. The use of low level laser therapy stimulates the production of our body's natural pain killers,  $\beta$ -endorphins and decreases the activity of C fibers, thus providing pain relief [20]. This was evident in the reduced VAS scores for pain and discomfort in the laser group compared to the scalpel group.

LLLT has a bio stimulating property translating into a better healing [21]. Patients in the laser group exhibited less rebound of the muscle attachments compared to the scalpel group. Our results were similar to the findings presented in case reports by Amid et al., and Moghtader et al., who had encouraged the use of laser for better postoperative healing outcomes [22,23]. The three point scale also corroborated our claim that in the initial healing period, laser wound exhibited better healing capabilities compared to the scalpel group. Our results were in accordance with Demir et al., and Neckel et al., who had reported a better wound healing post a vestibuloplasty procedure using a laser when compared to the scalpel group [24,25].

Our present study evaluated the wound healing mechanism through the examination of fibrinous slough which forms in the early phases of wound healing. Both the groups presented a slough formation in the initial 24 to 72 hour postoperative period. Further follow up revealed that the patients in the laser group demonstrated a better healing outcome with less slough formation compared to the scalpel group as evident from the photographs.

Our findings get support from Walsh et al., who had reported that the use of low level laser therapy enhances phagocytic activity by macrophages and also results in mast cell degranulation [20]. These put together result in an effective wound debridement with reduction in the slough.

Our study had considered gender comparison for any significance in VAS scores for pain and discomfort. The results showed that there was no significant correlation between VAS scores and the gender which was in accordance with results reported by Kelly et al., which revealed that the VAS scores for pain were influenced by either the age or the gender [26].

Our experience with previous vestibuloplasty procedures performed with a scalpel highlights the fact that most of the patients were given antibiotics and analgesics to reduce the postoperative infection and pain whereas our clinical study gives merit to the fact that only three patients in the laser group had taken analgesics after the procedure whereas all the patients in the scalpel group had taken analgesics post the procedure.

## LIMITATION

One of the limitations of the present study was the relatively small sample size. Considering it a clinical study with postoperative follow up, it was indeed difficult to recruit patients who satisfied the inclusion criteria. The other limitation was the relatively less time period considered for the postoperative follow up. The study would have gained much significance if the gain in vestibular depth was measured with a sufficient follow up.

## CONCLUSION

The results achieved in our clinical study highlight the laser group demonstrating better patient's perceptions and healing outcome with successful enhancement of the patient's vestibular depth. Though sound evidence based on further research validated by a bigger sample size and protocols are necessary; Lasers prove to be a viable, safe and an alternate option to scalpel in vestibuloplasty procedures.

## REFERENCES

- [1] Melo LG, Almeida AL, Lopes JF, Rezende ML, Neto JS, Ciporkin F, et al. A modified approach for vestibuloplasty in severely resorbed mandible using an implant-retained postoperative stent: A case report. *Oral Surg Oral Med Oral Pathol Oral Radiol Endod.* 2008;106:e7-e14.
- [2] Scheyer ET, Sanz M, Dibart S, Langer L, John V, Greenwell H, et al. Periodontal soft tissue non- root coverage procedures: a consensus report from the AAP regeneration workshop. *J Periodontol.* 2015;86:S73-S76.
- [3] American Academy of Periodontology. Glossary of periodontal terms. 4<sup>th</sup> ed. Chicago: *American Academy of Periodontology.* 2001;55-56.
- [4] Froschl T, Kerscher A. The optimal vestibuloplasty in preprosthetic surgery of the mandible. *J Craniomaxillofac Surg.* 1997;25:85-90.
- [5] Edlan A, Mejchar B. Plastic surgery of the vestibulum in periodontal therapy. *Int Dent J.* 1963;13:593-96.
- [6] Kazanjian VH. Surgical operations as related to satisfactory dentures. *Dent Cosmos.* 1924;66:387-91.
- [7] Corn H. Periosteal separation-its clinical significance. *J Periodontol.* 1962;33:140-53.
- [8] Parker S. Lasers and soft tissue: 'fixed' soft tissue surgery. *Br Dent J.* 2007;202:247-53.
- [9] Gordana K, Georgi T, Petar B, Aleksandar K, Vesna A. Er: YAG Laser assisted vestibuloplasty: a case report. *Journal of Surgery.* 2013;1:59-62.
- [10] Yilmaz E, Ozcelik O, Comert M, Ozturan S, Seydaoglu G, Teughels W, et al. Laser-assisted laterally positioned flap operation: a randomized controlled clinical trial. *Photomed Laser Surg.* 2014;32:67-74.
- [11] Amorim JC, de Sousa GR, de Barros Silveria L, Prates RA, Pinotti M, Riberio MS. Clinical study of the gingiva healing after gingivectomy and low-level laser therapy. *Photomed Laser Surg.* 2006;24:588-94.
- [12] Lagdive S, Doshi Y, Marawar PP. Management of gingival hyperpigmentation using surgical blade and diode laser therapy: a comparative study. *J Oral Laser Applications.* 2009;9:41-47.
- [13] Cobb CM. Lasers in periodontics: a review of the literature. *J Periodontol.* 2006;77:545-64.
- [14] Coleton S. Lasers in surgical periodontics and oral medicine. *Dent Clin North Am.* 2004;48:937-62.
- [15] Pirnat S. Versatility of an 810 nm diode laser in dentistry: an overview. *J Laser Health Acad.* 2007;4:1-9.
- [16] Goharkhay K, Moritz A, Wilder-Smith P, Schoop U, Kluger W, Jakolitsch S, et al. Effects on oral soft tissue produced by a diode laser in vitro. *Lasers Surg Med.* 1999;25:401-06.
- [17] Moritz A, Schoop U, Goharkhay K, Schauer P, Doertbudak O, Wernisch J, et al. Treatment of periodontal pockets with a diode laser. *Lasers Surg Med.* 1998;22:302-11.
- [18] Nammour S, Gerges E, Bou Tayeh R, Zeinou. Oral crest lengthening for increasing removable denture retention by means of CO<sub>2</sub> laser. *Scientific World Journal.* 2014;2014:738643
- [19] Zeinoun T, Nammour S, Dourov N, Aftimos G, Luomanen M. Myofibroblasts in healing laser excision wounds. *Lasers Surg Med.* 2001;28:74-79.
- [20] Walsh LJ. The current status of low level laser therapy in dentistry. Part 1. Soft tissue applications. *Aust Dent J.* 1997;42:247-54.
- [21] Pourreau-Schneider N, Ahmed A, Soudry M, Jacquemier J, Kopp F, Franquin JC, et al. Helium-neon laser treatment transforms fibroblasts into myofibroblasts. *Am J Pathol.* 1990;137:171-78.
- [22] Amid R, Mahdi K, Hemmatzadeh S, Refoua S, Iranparvar P, Shahi A, et al. Using diode laser for soft tissue incision of oral cavity. *J Lasers Med Sci.* 2012;3:36-43.
- [23] Moghtader D. Up-to-date vestibuloplasty at the age of implant dentistry. *Laser.* 2012;3:30-35.
- [24] Demir T, Kara C, Ozbek E, Kalkan Y. Evaluation of neodymium-doped yttrium aluminium garnet laser, scalpel incision wounds, and low-level laser therapy for wound healing in rabbit oral mucosa: a pilot study. *Photomed Laser Surg.* 2010;28:31-37.
- [25] Neckel CP. "Vestibuloplasty: a retrospective study on conventional and laser operation techniques", Proc. SPIE 3593, *Lasers in Dentistry.* 1999;76:18-23. doi:10.1117/12.348330
- [26] Kelly AM. Does the clinically significant difference in visual analog scale pain scores vary with gender, age, or cause of pain? *Acad Emerg Med.* 1998;5:1086-90.

### PARTICULARS OF CONTRIBUTORS:

1. Faculty, Department of Preventive Dental Sciences, AlFarabi Colleges, Riyadh, KSA.
2. Faculty, Department of Periodontics, Maitri Dental College, Chhattisgarh, India.
3. Faculty, Department of Preventive Dental Sciences, AlFarabi Colleges, Riyadh, KSA.
4. Faculty, Department of Preventive Dental Sciences, AlFarabi Colleges, Riyadh, KSA.
5. Faculty, Department of Oral and Maxillofacial surgery, Sri Sai College of Dental Surgery, Vikarabad, Telangana, India.
6. Faculty, Department of Periodontics, Sri Sai College of Dental Surgery, Vikarabad, Telangana, India.
7. Faculty, Department of Prosthodontics, Sri Sai College of Dental Surgery, Vikarabad, Telangana, India.
8. Faculty, Department of Oral and Maxillofacial Sciences, AlFarabi Colleges, Riyadh, KSA.

### NAME, ADDRESS, E-MAIL ID OF THE CORRESPONDING AUTHOR:

Dr. Butchibabu Kalakonda,  
Faculty, Department of Preventive Dental Sciences, Al Farabi Colleges, Riyadh, KSA.  
E-mail: docbutchi@gmail.com

Date of Submission: **Nov 01, 2015**

Date of Peer Review: **Jan 05, 2016**

Date of Acceptance: **Jan 29, 2016**

Date of Publishing: **May 01, 2016**

FINANCIAL OR OTHER COMPETING INTERESTS: None.