

Odontogenic Myxoma of Mandible with Unusual (Sunburst) Appearance: A Rare Case Report

SWATI GOEL¹, MANISH GOEL², AJIT D. DINKAR³

Keywords: Benign odontogenic tumor, Mandible, Multilocular radiolucency

An 18-year-old female patient presented with complaint of swelling on the lower right side of the face since six months. Swelling was initially small but gradually increased in size up to the present dimension within four months. Since two months there was no increase in the size of the swelling. There was no history of trauma, paresthesia, pain or fever. Patient was having difficulty in mastication. On general physical examination, the patient was well nourished and her vital signs were normal. The past medical history was non-contributory.

Extraoral examination revealed facial asymmetry due to swelling on the right body of the mandible which measured about 8cm X 6cm extending antero-posteriorly from right parasymphysis to the angle of mandible and inferiorly involving the inferior cortex and extending into the submandibular region crossing the midline. Skin over the swelling was normal and surface was smooth [Table/Fig-1]. On palpation, site, size and extent of swelling was confirmed. Swelling was firm in consistency and was tender on palpation.

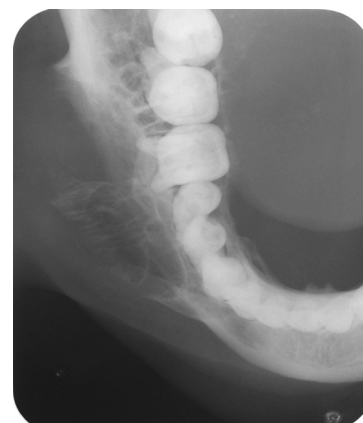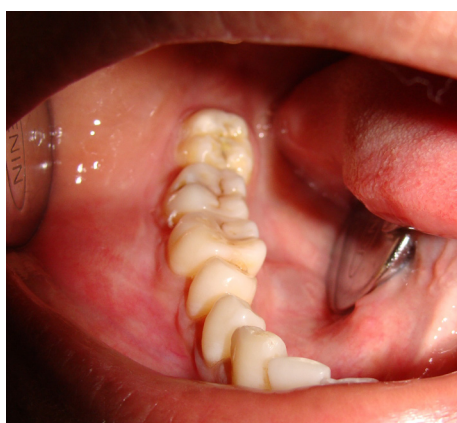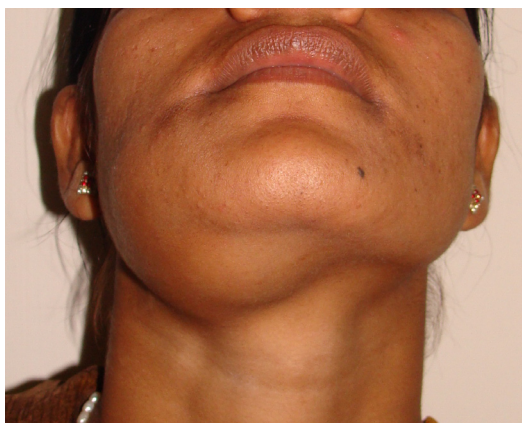On intraoral examination, the right mandibular region showed a swelling extending from tooth # 43 to tooth # 47. It measured about 6cm X 2cm, obliterating the buccal sulcus. It was firm in consistency and was tender on palpation. The mucosa overlying the area was intact. On the lingual side too, there was swelling in the premolar and molar region which was firm and smooth [Table/Fig-2]. Teeth # 43 to 48 and # 33 to 38 tested positive for pulp vitality. Provisional diagnosis of benign odontogenic tumor was given. Patient was advised hematological and biochemical laboratory tests, panoramic radiograph, mandibular right lateral occlusal radiograph and CT scan. Hematological and biochemical laboratory tests were within normal limits.

A mandibular right lateral occlusal radiograph revealed single large multilocular radiolucent lesion extending from distal surface of lower right lateral incisor to the lower right third molar extending to involve buccal and lingual cortices. Multiple thin straight septae were seen in the molar region and curved septae were seen in the anterior region [Table/Fig-3].

Panoramic radiograph revealed single large multilocular osteolytic radiolucent lesion involving the right body and inferior half of the ramus extending from midline. Superiorly extending to involve the crestal bone and inferiorly closely approximating the inferior cortex. The lesion was not well defined. The internal structure was radiolucent with thick radiopaque curved septae seen in the body region and thin straight septae seen in the crestal bone. Widening of periodontal space was seen uniformly, involving first, second and third molar. Root resorption was seen till apical third of mesial root of first molar and distal root of second molar. There was marked resorption of the inferior cortex with Sunburst Periosteal reaction in relation to right mandibular body [Table/Fig-4].

CT scan of mandible and neck showed that there was destruction of the right body and ramus of the mandible with associated soft tissue component containing bony spicules within the mass extending medially, displacing the mylohyoid muscle and the tongue towards the opposite side [Table/Fig-5]. Anteriorly the mass extended into the soft tissue of the cheek. Periosteal reaction was observed with sunburst appearance [Table/Fig-6].

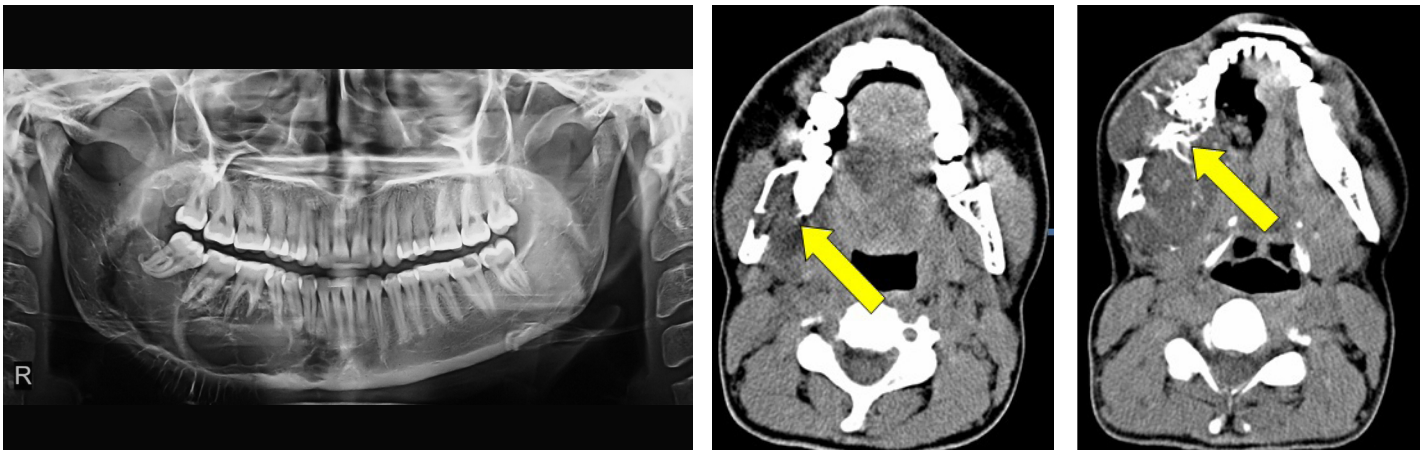
The differential diagnosis considered was osteosarcoma, ameloblastoma and odontogenic myxoma. Incisional biopsy was performed under local anesthesia and subjected to histopathological examination.



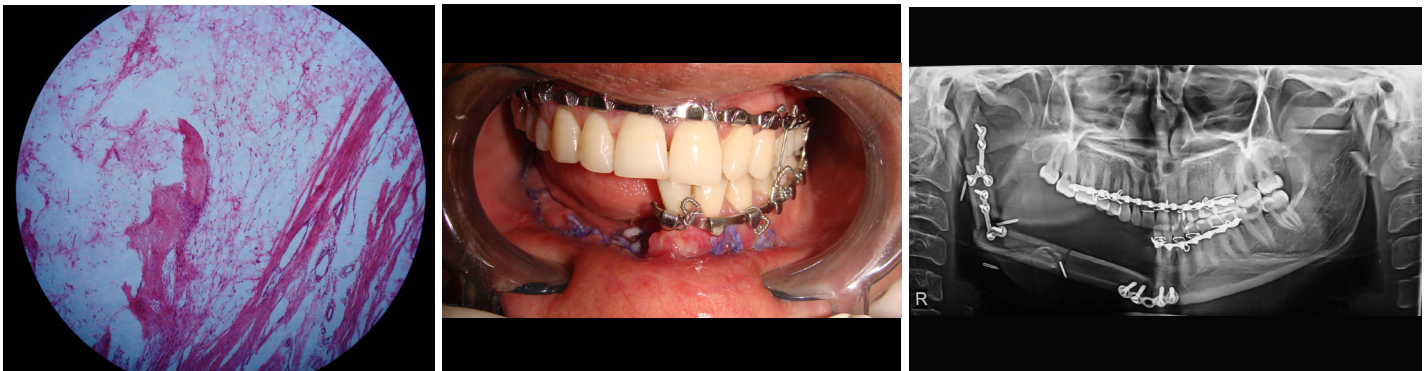[Table/Fig-1]: Extraoral photograph showing swelling on the right side of the body of the mandible crossing the midline and extending to the submandibular region.

[Table/Fig-2]: Intraoral photograph of the mandibular right quadrant showing buccal and lingual swelling / cortical expansion in the premolar and molar region.

[Table/Fig-3]: Right mandibular lateral occlusal view shows single large multilocular radiolucent lesion extending from distal surface of lower right lateral incisor to the lower right third molar involving buccal and lingual cortices.



[Table/Fig-4]: Panoramic radiograph shows single large multilocular radiolucent osteolytic lesion extending from the midline involving the right body and inferior half of the ramus with a marked scalloped shaped resorption of the inferior cortex that presents a sunburst periosteal reaction. **[Table/Fig-5]:** CT Scan of the mandible shows an osteolytic lesion on the right side involving the body and ramus with mild expansion and destruction of the medial cortex. **[Table/Fig-6]:** CT Scan of the mandible shows a sunburst periosteal reaction.



[Table/Fig-7]: H & E section shows a loose myxomatous stroma. **[Table/Fig-8]:** Post-operative intraoral photograph shows Vicryl sutures placed over the surgical site of the hemisectioned right half of the mandible with intermaxillary fixation done on the left side. **[Table/Fig-9]:** Post-operative radiograph shows resection of mandible on the right side with preservation of condyle and coronoid process and placement of an 'L' shaped reconstruction graft fixed with three bone plates one in the anterior region and two in the ramus region.

On microscopic examination, the stained H & E section showed a loose myxomatous stroma. The stroma made up of stellate shaped cells with long cytoplasmic processes anastomosing with each other. Each cell has a prominent darkly staining nucleus. A few fibroblasts and collagen fibers were seen in between the myxoid stroma. The histopathology report was suggestive of a diagnosis of odontogenic myxoma [Table/Fig-7].

The patient was admitted for surgery. Hemi-mandibulectomy of the right side was done preserving the condyle and coronoid process of the mandible and primary reconstruction was done by taking graft from the fibular region. Maxillomandibular fixation was maintained for 45 days [Table/Fig-8,9]. Microscopic examination of the surgical specimen confirmed the diagnosis of Odontogenic Myxoma. During the one year post-surgical follow up, there was no evidence of any recurrence.

DISCUSSION

Thoma and Goldman first described Odontogenic Myxoma (OM) in 1947. It accounts for 3-6% of all odontogenic tumors. OM usually occurs in second and third decade of life in young adults with marked female predilection. The majority of these tumors occur in the mandible, followed by the maxilla [1].

OM is considered a slow-growing, non-metastasizing tumor characterized by asymptomatic expansion of the jaw. Its aggressive nature causes bone perforation, root resorption, tooth displacement, and mobility. Production of a mucoid ground substance by the stellate tumor cells causes rapid growth of the tumor [2].

These tumors usually show variable radiographic features ranging from small unilocular lesion to large multilocular lesions, which often displace the teeth or resorb the roots. Various descriptions

given for the multilocular trabecular pattern are honeycomb, soap bubble, tennis racket, wispy and spider web in appearance. Our case presented with a multilocular radiolucency involving the right body of the mandible extending to the inferior half of the ramus. The inferior border of the mandible showed decreased density of cortical bone bordered with radiopaque spike like projections extending to the surface giving a sunburst type of periosteal reaction that is extremely rare. A CT Scan confirmed these findings [3]. Case reports by Chuchurru et al., and Kidwai et al., also featured sunburst appearance of odontogenic myxoma [4,5]. The dentists should be aware of this unusual radiographic presentation so that a misdiagnosis of malignant bone tumor is not made [3].

Differential diagnosis of OM includes other benign tumors like ameloblastoma, central giant cell granuloma, central hemangioma and odontogenic keratocyst amongst the cystic lesions [6].

Recurrences are quite common with a reported rate of 25% in treated patients. This behavior is due to tendency of OM to spill into the surrounding marrow spaces [6]. The prognosis of OM of the jaw is generally good after complete removal. With adequate surgical excision, long-term survival without recurrence can be anticipated [3]. Long term follow-up helps to confirm disease free status [2].

REFERENCES

- [1] Chavan S, Prabhune S, Pawar R, Deshmukh R, Nagpal D. Odontogenic myxomas with an unusual presentation in the anterior mandible: a case report. *Indian Journal of Mednodent and Allied Sciences*. 2014; 2:115-18.
- [2] Higo M, Kasamatsu A, Ogawara K, Shiiba M, Uzawa K, Tanzawa H. A case of a rapidly expanding odontogenic myxoma of the mandible. *Oral Science International*. 2015; 12:22-26.
- [3] Vijayalakshmi D, Murali S, Sekar B. Odontogenic myxoma—an unusual presentation. *Journal of Indian Academy of Dental Specialists*. 2011; 2:48-51.

- [4] Chuchurru Jorge A, Ricardo L, Cornicelli Juan C, Dominguez Francisco V. Myxoma of the mandible with unusual radiographic appearance. *Journal of Oral and Maxillofacial Surgery*. 1985;43:987-90.
- [5] Kidwai SM, Mohan RS, Wadhwan V, Kamarthi N, Goel S, Gupta S. Sunburst appearance in odontogenic myxoma of mandible: a radiological diagnostic challenge. *J Oral Maxillofac Radiol*. 2016; 4:18-21.
- [6] Wood NK, Goaz P, Kallal RH. Multilocular radiolucencies. In: Differential diagnosis of oral and maxillofacial lesions. 5th ed. St. Louis, Missouri: Mosby Elsevier, 2007; pp 342-43.

PARTICULARS OF CONTRIBUTORS:

1. Senior Lecturer, Department of Oral Medicine, Diagnosis and Radiology, Eklavya Dental College and Hospital, Jaipur, India.
2. Research Officer, Department of Pulmonary Medicine, All India Institute of Medical Sciences, New Delhi, India.
3. Professor and Head, Department of Oral Medicine, Diagnosis and Radiology, Goa Dental College & Hospital, Goa, India.

NAME, ADDRESS, E-MAIL ID OF THE CORRESPONDING AUTHOR:

Dr. Swati Goel,
Pocket C-60A, Gangotri Enclave, Alaknanda, New Delhi-110019, India.
E-mail: swatigarg610@gmail.com

Date of Submission: **Mar 13, 2016**

Date of Peer Review: **Apr 13, 2016**

Date of Acceptance: **Apr 18, 2016**

Date of Publishing: **May 01, 2016**

FINANCIAL OR OTHER COMPETING INTERESTS: None.