

# ST-Elevation Myocardial Infarction 33 Days after Lung Transplant in a Patient with Non-Significant CAD before Transplantation: A Case Report

SAEED ALIPOUR PARSA<sup>1</sup>, ISA KHAHESHI<sup>2</sup>, AMIR DOUSTI<sup>3</sup>, FARAH NAGHASHZADEH<sup>4</sup>, BAHAR ATAENIA<sup>5</sup>

## ABSTRACT

Acute myocardial infarction after lung transplantation is not well illustrated in the literature. We present a patient with documented non significant Coronary Artery Disease (CAD) in coronary angiography before lung transplant who was referred to our hospital with acute Myocardial Infarction (MI) 33 days following lung transplantation.

**Keywords:** Air embolism, Acute myocardial infarction, Coronary artery disease, Lung transplantation

## CASE REPORT

A 52-year-old gentleman with history of cigarette smoking (90 packs/year) and severe COPD underwent successful lung transplantation due to clinical deterioration despite optimal medical therapy and rehabilitation. He had no other coronary risk factors, history of premature myocardial infarction in his family or history of substance abuse.

His medications before myocardial infarction were prednisolone 30 mg/daily, cyclosporine 100/twice daily, mycophenolate mofetil 2 gm/twice daily, trimethoprim 160 mg, Sulfamethoxazole 800 mg/ twice daily, itraconazole 200 mg/daily, and ipratropium bromide inhalation 2 puff per 12 hours. Also, he was not on home O<sub>2</sub> therapy after lung transplantation.

Only 33 days after transplantation, he was referred to our hospital with complaint of crushing chest pain and cold sweating accompanied with extensive ST elevation in ECG (Electro Cardio Graphy).

Coronary angiography performed 56 days before lung transplantation revealed moderate stenosis of proximal LAD (Left Anterior Descending Coronary Artery) [Table/Fig-1a]. Also, his transthoracic echocardiography before transplantation showed ejection fraction of 55% and mild tricuspid regurgitation.

By the time he was referred to our hospital, his haemodynamic status was stable and heart and lung examination was unremarkable except for hearing S4 in heart auscultation. A 12 leads ECG revealed ST-elevation in precordial leads (V1-V6) and leads I and aVL with biphasic T wave pattern. Transthoracic echocardiography showed 40% ejection fraction with severe hypokinesia of the anterior, anterolateral and apical walls.

The patient was immediately scheduled for emergent coronary angiography, which showed severe stenosis at proximal portion of Left Anterior Descending (LAD) artery [Table/Fig-1b]. So, urgent Percutaneous Coronary Intervention (PCI) was performed with one drug eluting stent (Xience 3.5mm\*28mm) [Table/Fig-1c].

The patient was haemodynamically stable and had no complaints after angioplasty. He was returned to referring hospital on third day after PCI on Acetyl Salicylic Acid (ASA) 80 mg daily, Clopidogrel 75 mg daily and Atorvastatin 40 mg daily in addition to previous medications. Then, he was advised for pulmonology and cardiology follow-up in near future. An informed consent was signed by the patient.

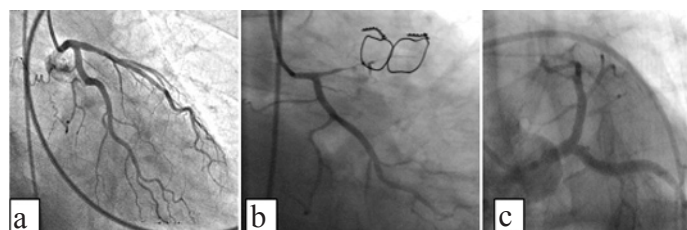
## DISCUSSION

Acute myocardial infarction after lung transplantation is not well described in the literature but it is showed that acute myocardial infarction after organ transplant is related to age, CAD risk factors and co-morbidities [1,2]. In the case that we presented, the patient had severe COPD due to smoking in the past which may be related to occurrence of acute myocardial infarction.

Acute myocardial infarction was reported as a complication of lung transplantation due to air embolism because of bronchial fistula to pulmonary veins and bubble passage to left atrium and then emboli into the coronary arteries [3]; however, in our case, coronary angiography showed stenotic plaque in LAD artery, which was managed by primary PCI.

All transplanted patients have an elevated risk of myocardial infarction. Thrombosis can be the consequence of surgery or immune related inflammation and immunosuppressive therapy that may lead to metabolic and haemostasis imbalance. This effect can also be more obvious in patients who are already at higher risks, like patients with well-known atherosclerosis [4-7].

To our knowledge, this is the first report of acute ST-elevation myocardial infarction in a very short period of time after lung transplantation, who had documented non-significant CAD. The role of high dose immunosuppressive therapy has been previously established in the pathogenesis of MI. Immunosuppressive and corticosteroid regimes may explain the rapid progression of coronary artery plaque. Exacerbation of traditional risk factors by immunosuppressive drugs and nontraditional risk factors related to immunosuppressive agents should be considered more judiciously [8,9].



**[Table/Fig-1]:** A: coronary angiography before lung transplantation showing no significant coronary artery disease. B: emergent coronary angiography 33 days after lung transplantation which revealed very tight stenosis at proximal portion of Left Anterior Descending (LAD) artery with poor antegrade run off. C: final result after stenting of LAD.

## CONCLUSION

This case report emphasizes that a comprehensive risk factors modification including traditional and nontraditional risk factors is so imperative in patients following lung transplantation.

## REFERENCES

- [1] Arcasoy SM, Kotloff RM. Lung transplantation. *N Engl J Med*. 1999;340:1081-91.
- [2] Lentine KL, Brennan DC, Schnitzler MA. Incidence and predictors of myocardial infarction after kidney transplantation. *J Am Soc Nephrol*. 2005;16:496-506.
- [3] Johnston SL, Halabi S, Cohoon K, Alex C, Hutchens K, Leya F. Stroke and myocardial infarction as late complications of lung transplantation. *J Heart Lung Transplant*. 2007;26(10):1065-68.
- [4] Cosio FG, Kudva Y, van der Velde M, Larson TS, Textor SC, Griffin MD, et al. New onset hyperglycaemia and diabetes are associated with increased cardiovascular risk after kidney transplantation. *Kidney Int*. 2005; 67:2415-2421.
- [5] Wilkinson A, Davidson J, Dotta F, Home PD, Keown P, Kiberd B, et al. Guidelines for the treatment and management of new-onset diabetes after transplantation. *Clin Transplant*. 2005;19:291-98.
- [6] Kasiske BL, Maclean JR, Snyder JJ. Acute myocardial infarction and kidney transplantation. *J Am Soc Nephrol*. 2006;17:900.
- [7] Ojo AO. Cardiovascular complications after renal transplantation and their prevention. *Transplantation*. 2006;82:603.
- [8] Taylor DO, Edwards LB, Boucek MM, Trulock EP, Aurora P, Christie J, et al. Registry of the International Society for Heart and Lung Transplantation: twenty-fourth official adult lung and heart-lung transplantation report-2007. *J Heart Lung Transplant*. 2007;26:769-81.
- [9] Lyu DM, Zamora MR. Medical complications of lung transplantation. *Proc Am Thorac Soc*. 2009;6(1):101-07.

### PARTICULARS OF CONTRIBUTORS:

1. Associated Professor, Cardiovascular Research Center, Department of Cardiology, Modarres Hospital, Shahid Beheshti University of Medical Sciences, Tehran, Iran.
2. Assistant Professor, Cardiovascular Research Center, Department of Cardiology, Modarres Hospital, Shahid Beheshti University of Medical Sciences, Tehran, Iran.
3. Resident of Cardiology, Cardiovascular Research Center, Department of Cardiology, Modarres Hospital, Shahid Beheshti University of Medical Sciences, Tehran, Iran.
4. Associated Professor, Lung Transplantation Research Center, National Research Institute of Tuberculosis and Lung Disease (NRITLD), Department of Cardiology, Shahid Beheshti University of Medical Sciences, Tehran, Iran.
5. Student of Medicine, Students' Scientific Research Center (SSRC), Department of Cardiology, Tehran University of Medical sciences, Tehran, Iran.

### NAME, ADDRESS, E-MAIL ID OF THE CORRESPONDING AUTHOR:

Dr. Isa Khaheishi,  
Assistant Professor, Cardiovascular Research Center, Department of Cardiology, Modarres Hospital,  
Shahid Beheshti University of Medical Sciences, Tehran, Iran.  
E-mail: isa\_khaheishi@yahoo.com

FINANCIAL OR OTHER COMPETING INTERESTS: None.

Date of Submission: **Jan 12, 2016**

Date of Peer Review: **Feb 11, 2016**

Date of Acceptance: **Feb 22, 2016**

Date of Publishing: **May 01, 2016**