

Fatal Nevirapine-Induced Toxic Epidermal Necrolysis in a HIV Infected Patient

SABYASACHI PAIK¹, SUKANTA SEN², NIKHIL ERA³, BIBHUTI SAHA⁴, SANTANU KUMAR TRIPATHI⁵

ABSTRACT

Stevens-Johnson Syndrome (SJS) and Toxic Epidermal Necrolysis (TEN) are the most Severe Cutaneous Adverse Reactions (SCARs) which mainly caused by exposure to drugs and having significant morbidity and mortality. TEN represents an immunologic reaction to a foreign antigen and is most often caused by drugs. Nevirapine (NVP), a non-nucleoside reverse transcriptase inhibitor (NNRTI) is an important component of Highly Active Antiretroviral Therapy (HAART). It is sometimes associated with life-threatening adverse reactions. Here, we report the fatal case of 72-year-old male who developed TEN secondary to intake of nevirapine. This fatal case report will increase awareness among treating physicians for careful monitoring of patients on NNRTI-based antiretroviral therapy and better counseling of the patient on NVP regimen for early identification and reporting of SCARs so that fatalities due to adverse drug reactions can be prevented with timely intervention.

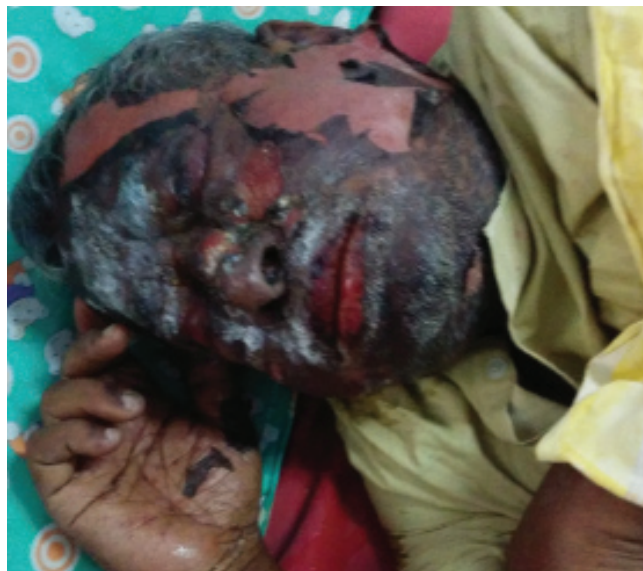Keywords: Severe adverse cutaneous drug reactions, Stevens–Johnson syndrome

CASE REPORT

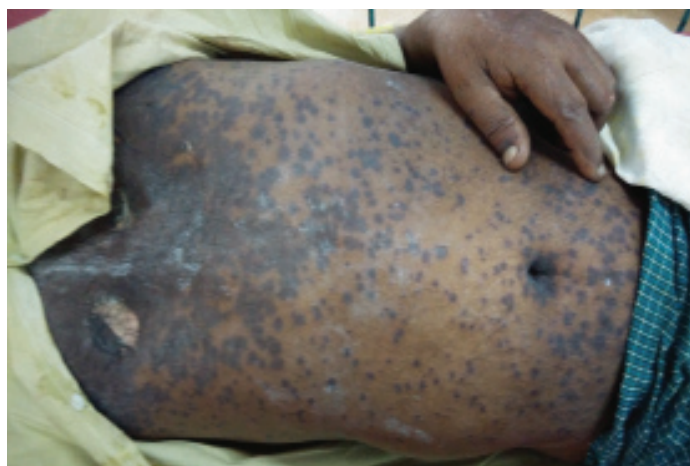A case of 72-year-old HIV sero-positive man who was admitted in the emergency with sudden development of diffuse, erythematous skin rash all over the body and difficulty in intake of food since four days following three weeks treatment of a triple combination: Zidovudine (300 mg) + lamivudine (150 mg) and nevirapine (200 mg). NVP was started as 200 mg tablet once daily for 2 weeks and then was increased to twice a day over next 2 weeks. He initially developed itching with maculopapular rash over face, upper portion of chest and trunk. Eight days later, he presented to us with a severe maculopapular rash all over the body with targetoid lesions over the limbs [Table/Fig-1]. Physical examination on admission revealed erythematous and maculopapular skin rash all over the body including involvement of eye and lips [Table/Fig-2] with body temperature of 38°C.

The entire skin covering the face and anterior parts of trunk was denuded and peeled off with minor manipulation and appeared blackish in colour [Table/Fig-3]. Multiple oral ulcers were seen. Haemorrhagic crusting of the lips was also noted [Table/Fig-3]. Ophthalmic examination revealed conjunctivitis. There was also involvement of skin over genital regions. There was no previous history of drug allergy with same drug or others.

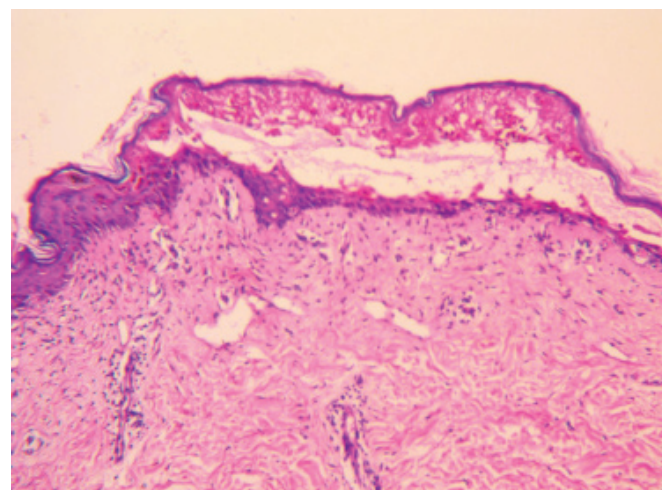
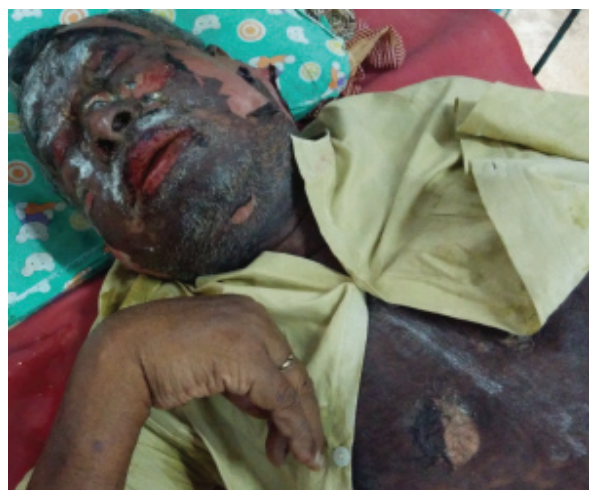The body surface area involvement of the patient at the time of presentation was approximately 35%. Over the next four days, he developed severe bullous lesions and extensive exfoliation involving more than 60 percent of the body surface, including the palms and soles. A diagnosis of nevirapine-induced TEN was made on the basis of temporal relationship, positive drug history, associated clinical symptoms and signs, positive Nikolsky's sign and full-thickness epidermal necrolysis on histopathology report [Table/Fig-4]. Serum transaminases (ALT and AST) and other haematological investigations were deranged. Their values were aspartate aminotransferase (1235 U/L) and alanine aminotransferase (790 U/L). There was hyponatraemia (129mEq/L) and hypokalaemia (3.2mEq/L). Blood culture was negative. Serological tests for HSV, HBV and HCV were negative. Other relevant laboratory tests done in hospital (serum urea, glucose and bicarbonate) along with clinical factors gave a SCORTEN of 5 [Table/Fig-5] [1] with a predictive mortality of 90%.



[Table/Fig-1]: Haemorrhagic crusting of the lips and multiple erythematous papules, plaques were present all over the body



[Table/Fig-2]: Targetoid lesions over the face, trunk and abdomen as initial manifestation



[Table/Fig-3]: Body surface skin over face and trunk denuded and peeled off with minor manipulation (positive Nikolsky sign) and appeared blackish in colour (TEN)

[Table/Fig-4]: Histopathology of NVP induced toxic epidermal necrolysis

Prognostic factors	Points	SCORTEN (sum of individual scores)	Predicted mortality (%)	Score in present case
Age > 40	Yes = 1, No = 0	0-1	3.2%	1
Heart rate >120/min	Yes = 1, No = 0	2	12.1%	1
Cancer or haematologic malignancy	Yes = 1, No = 0	3	35.8%	0
>10% body surface area	Yes = 1, No = 0	4	58.3%	1
Serum urea >10mm/L	Yes = 1, No = 0	>5	90%	1
Serum bicarbonate <20mm/L	Yes = 1, No = 0			1
Serum glucose >14mm/L (1 mmol/L of Glucose = 18.02 mg/Dl)	Yes = 1, No = 0			0
				Total score= 5

Criterion	Values Rules to apply	Score in the present case
Delay from initial drug intake to onset of reaction (index day)	Suggestive +3 From 5 to 28 days Compatible +2 From 29 to 56 days Likely +1 From 1 to 4 days Unlikely -1 >56 Days Excluded -3 Drug started on or after the index day In case of previous reaction to the same drug, only changes for: Suggestive: +3: from 1 to 4 days Likely: +1: from 5 to 56 days	Suggestive +3
Drug present in the body on index day	Definite 0 Doubtful -1 Excluded -3	Definite: 0
Prechallenge/rechallenge	Positive specific for disease and drug: 4 Positive specific for disease or drug: 2 Positive unspecific: 1 Not done/unknown: 0 Negative -2	Not done: 0
Dechallenge	Neutral 0 Drug stopped (or unknown) Negative -2 Drug continued without harm	Neutral: 0
Type of drug (notoriety)	Strongly associated 3 Drug of the "high-risk" list according to previous case-control studies Associated 2 Drug with definite but lower risk according to previous case-control studies Suspected 1 Several previous reports, ambiguous epidemiology results (drug "under surveillance") Unknown 0 All other drugs including newly released ones Not suspected -1 No evidence of association from previous epidemiology study with sufficient number of exposed controls	Associated: 3
Other cause	Possible -1 Rank all drugs from highest to lowest intermediate score If at least one has an intermediate score >3, subtract 1 point from the score of each of the other drugs taken by the patient (another cause is more likely)	0

[Table/Fig-5]: Severity-of-illness assessed by using the SCORTEN criteria

[Table/Fig-6]: Assessment of causality by using the algorithm of drug causality for epidermal necrolysis (ALDEN). (Interpretation: <0, Very unlikely; 0-1, unlikely; 2-3, possible; 4-5, probable; ≥6, very probable) Total score in present case=6, means "very probable"

On hospitalization ART was stopped and patient was put on intravenous immunosuppressant (cyclosporin/CsA), intravenous antibiotic, intravenous paracetamol (as when required, topical antiseptic, anti-histamine, topical lubricants, fluid therapy and parenteral nutrition. The patient was started on immunosuppressant ciclosporin (CsA) at a dosage of 5 mg/kg daily given in 2 divided doses. Wounds were treated conservatively, without skin debridement. Treatment of skin lesions by the topical application of mupirocin, 0.9% NaCl and 0.5% AgNO₃ three times a day was done. Despite meticulous supportive care and withdrawal of all suspected drugs, patient's condition worsened and he died after 7 days of hospital admission.

The causality assessment as per the Naranjo algorithm [2] and WHO- UMC criteria [3] revealed the ADR to be "Probable" (Naranjo score 8). Assessment of causality by using the algorithm of drug causality for epidermal necrolysis (ALDEN) [Table/Fig-6] [4] was also used.

DISCUSSION

Adverse Drug Reactions (ADRs) become a matter of concern as these are one of the leading causes of morbidity and at times mortality among hospitalized patients. Approximately 8% cases among all hospital admissions are due to ADRs as per reports published in different studies [5]. The international classification of SJS/TEN is based on the body surface area (BSA) involved:

Based on BSA insolvent the SCARs are mainly divided into three main categories. By definitions SJS involves <10% of BSA; TEN involves >30%; and overlap syndrome with involvement of 10-30%. [6] Common causes of death include septic shock,

hypovolaemic shock, acute renal failure, fulminant hepatitis and multi-organ involvement [6]. Previous studies has shown that most common drugs implicated are sulphonamide antibiotics (38%) and nevirapine (20%) [7]. Antiretrovirals as a group, is important for developing drug induced cutaneous drug reactions [8]. Usually a

gap of 4-28 days between beginning of drug use and onset of the adverse reaction is the most suggestive timing for supporting drug causality in SJS or TEN. Study has shown that greatest risk of SCARs with NVP treatment mainly occurred during the first few weeks of treatment initiation [8]. It is the duty of the healthcare provider (s) to counsel patient on HAART therapy regarding early identification and reporting of any kind skin rashes on initiation of therapy.

Diagnosis is challenging as clinical picture ADRs may vary from mild rashes to severe reactions such as SJS or TEN. Toxic Epidermal Necrolysis (TEN) is one of such ADRs which create great threat on public health due to its severe morbidity and mortality. The pathogenesis of SJS/TEN is not fully understood but is believed to be immune-mediated [5]. On histopathology, present case showed extensive keratinocyte apoptosis followed by necrosis. This is the pathogenic basis of the widespread epidermal detachment observed in TEN lesions.

The pathogenesis of SJS/TEN is thought to be a 2-staged process in which the first stage (initiation stage) involves non-inflammatory apoptosis of keratinocytes and the second stage is the amplification phase [9]. In the initiation phase, drug metabolites are thought to mediate CD95 ligand (Fas ligand) and Tumour necrosis factor α (TNF- α) systems stimulating apoptosis. The amplification stage involves inflammatory cells in which TNF- α and IL-2 act as chemotactic cytokines, recruiting CD41 T lymphocytes in the dermis and CD81 cells in the epidermis. During this stage, TNF- α and IL-2 also act as messengers by stimulating the release of chemotactic factors that recruit natural killer lymphocytes and macrophages into the epidermis. The hallmark of the amplification phase of TEN is massive destruction of the epidermis [10].

Nevirapine, a dipyrindo-diazepinone, is a Non-Nucleoside Reverse Transcriptase Inhibitor (NNRTI). Nevirapine is an important component of HAART regimen and have been widely used in resource limited countries because of its efficacy, accessibility and comparatively low cost.

The common adverse drug reactions (ADRs) observed with NVP includes skin rashes and hepatotoxicity [11].

Newer pharmacotherapy regimen, specific treatment of opportunistic infections and modified lifestyle has prolonged the life span of HIV infected patients. But adverse drug reactions to Anti-Retroviral Therapy (ART) continue to be a matter of concern, as they inflict significant morbidity and mortality. In present case, the patient suffered severe cutaneous adverse reaction to

nevirapine, whose course and morphology gradually evolved from maculopapular rash to targetoid lesions, to extensive erosions of the skin, leading to TEN along with hepatotoxicity and ultimately fatal outcome.

Animal model of NVP induced skin rash demonstrated that 12-hydroxylation metabolic pathway is responsible for developing rash [12]. Previous study it was observed that the CD4+ T cells depletion reduces as well as delays the severity of NVP induced skin rash. Factors may play role in the development and clinical outcome of SJS/TEN are as follows: HIV infection, CD4+ count, causative drug, age, gender, co-medication and use of steroids during the acute stages.

This case report also illustrates the importance of early suspicion of SJS when an HIV-infected patient treated with nevirapine presents with maculopapular rash. The salient features of the earlier published cases have been compared with the present case report in [Table/Fig-7] [13-18].

Patient information, early identification, close observation, timely intervention with meticulous medical and nursing care and support are essential steps for management of TEN. As mortality is high in TEN, clinician must have to be extra cautious in managing HIV infection with ART particularly during the initial two months of treatment to prevent such serious life threatening reactions. A strict vigilance on part of treating physician or health care provider(s) for the initial 2 months is utmost important to prevent such adverse events. Application pharmacogenomics knowledge based on their diverse genetic make-up will define the particular population or a person, who responds differentially to a particular drug.

CONCLUSION

A 72-year-old male developed TEN secondary to intake of nevirapine. Despite meticulous supportive care and withdrawal of all drugs, his situation worsened and died after 7 days of hospital admission. This simply signifies the chances fatality of nevirapine induced SJS-TEN. For this reason, prompt identification and withdrawal of the culprit drug(s) with early diagnosis, evaluation of the severity and prognosis of disease, rapid initiating supportive care and definite treatment in an appropriate setting is the mainstay for the management of SJS/TEN. Patients should be educated on potential danger symptoms and signs of SJS/TEN when they taking high-risk medicines.

The fatal outcome in this case raises questions regarding the initiation of ART in patients with similar presentations and approach

Author	Gender/ Age	Onset of illness (SCARs)	Findings	Outcome
Budamakuntla L et al., [13]	Male/ 44y	20 days	Patient developed Toxic Epidermal Necrolysis (TEN), leucopenia and hepatotoxicity secondary to intake of nevirapine.	Recovered completely after 1 month
Claes P et al., [14]	Male/ 49 y	13 days	TEN or Lyell's syndrome, complicated by a toxic hepatitis with severe stomatitis	Recovered completely with a combination of intravenous immunoglobulins and N-acetylcysteine
Zingela Z et al., [15]	Male/ 28y	21 days	Fatal nevirapine-induced Stevens-Johnson syndrome with HIV-associated mania	Stevens-Johnson syndrome (SJS), which progressed to toxic epidermal necrolysis (TEN) and death over a period of 26 days.
Patel K et al., [16]	Male/ 46 y	2 months	Nevirapine and/or co-trimoxazole induced Stevens Johnson syndrome in HIV infected patient	Patient died despite stopping of all medications
Mohamed Cissé et al., [17]	Female /28y Female /26y	15 days 20 days	Two cases of nevirapine induced TEN with fatal outcome in two pregnant women having received it in the context of prevention of mother to child transmission of HIV.	The patients died on Day 9 (D9) and at Day 2 (D2) of hospitalization respectively.
Patel IB et al., [18]	Male/ 27	10 days	Patient had multiple hemorrhagic lesions present over trunk, upper and lower limb, purpura present over palms, soles, legs, and toes	Recovered completely
Present Case	Male/ 72 y	25 days	Patient presented to us with a severe maculopapular rash all over the body with targetoid lesions over the limbs with extensive exfoliation involving more than 60 percent of the body surface areas. SCORTEN score was 5.	Died after 7 days of hospital admission

[Table/Fig-7]: Salient features of already published cases as compared with the present case report.

of their management. This case emphasizes the need for further research in Indian patients into these factors to aid clinicians in decision making when it comes to safe options for starting treatment HIV infected patient.

REFERENCES

- [1] Bastuji-Garin S, Fouchard N, et al. SCORTEN: a severity-of-illness score for toxic epidermal necrolysis. *J Invest Dermatol*. 2000;115:149-53.
- [2] Naranjo CA, Busto U, Sellers EM, Sandor P, Ruiz I, Roberts EA, et al. A method for estimating the probability of adverse drug reactions. *Clin Pharmacol Ther*. 1981;30:239-45.
- [3] The use of the WHO-UMC system for standardised case causality assessment. Available from: <http://www.WHO-UMC.org/graphics/4409.pdf>. (Last accessed on 2014 Sept 30).
- [4] Sassolas B, Haddad C, Mockenhaupt M, Dunant A, Liss Y, Bork K, et al. ALDEN, an algorithm for assessment of drug causality in Stevens-Johnson Syndrome and toxic epidermal necrolysis: comparison with case-control analysis. *Clin Pharmacol Ther*. 2010;88:60-68.
- [5] Lazarou J, Pomeranz BH, Corey PN. Incidence of adverse drug reactions in hospitalized patients: A meta-analysis of prospective studies. *JAMA*. 1998;279:1200-05.
- [6] Mockenhaupt M. The current understanding of Stevens-Johnson syndrome and toxic epidermal necrolysis. *Expert Rev Clin Immunol*. 2011;7(6):803-15.
- [7] Saka B, Barro-Traoré F, Atadokpédé FA, et al. Stevens-Johnson syndrome and toxic epidermal necrolysis in sub-Saharan Africa: A multicentric study in four countries. *Int J Dermatol*. 2013;52(5):575-79.
- [8] Paquet P, Jacob E, Damas P, et al. Analytical quantification of the inflammatory cell infiltrate and CD95R expression during treatment of drug-induced toxic epidermal necrolysis. *Arch Dermatol Res*. 2005;297:266-73.
- [9] Sanmarkan AD, Sori T, Thappa DM, Jaisankar TJ. Retrospective analysis of Stevens-Johnson syndrome and toxic epidermal necrolysis over a period of 10 years. *Indian J Dermatol*. 2011;56:25-29.
- [10] Frisch PO, Ruiz-Maldonado R. Erythema multiforme, Stevens Johnson syndrome and toxic epidermal necrolysis. In: Freedberg IM, Eisen AZ, Wolff K, Austen KF, Goldsmith LA, Katz SI, editors. *Fitzpatrick's dermatology in general medicine*, 6th edn. New York: McGraw-Hill; 2003. Pp. 543-57.
- [11] Sabbatani S, Manfredi R, Biagetti C, Chiodo F. Antiretroviral therapy in the real world: population-based pharmaco-economic analysis of administration of anti-HIV regimens to 990 patients. *Clin Drug Investig*. 2005;25:527-35.
- [12] Chen X, Tharmanathan T, Mannargudi B, Gou H, Uetrecht JP. A study of the specificity of lymphocytes in nevirapine-induced skin rash. *J Pharmacol Exp Ther*. 2009;331:836-41.
- [13] Budamakuntla L, Loganathan E, Suryanarayan S, Abhishek K, Sarvajnamurthy S. Nevirapine induced toxic epidermal necrolysis and non-Hodgkin lymphoma in a Human Immunodeficiency Virus positive patient. *Indian Dermatol Online J*. 2014;5:179-81.
- [14] Claes P, Wintzen M, Allard S, Simons P, De Coninck A, Lacor P. Nevirapine-induced toxic epidermal necrolysis and toxic hepatitis treated successfully with a combination of intravenous immunoglobulins and N-acetylcysteine. *Eur J Intern Med*. 2004;15(4):255-58.
- [15] Zingela Z, Bronkhorst A, Qwasha WM, Magigaba BP. Fatal nevirapine-induced Stevens-Johnson syndrome with HIV-associated mania. *Southern African Journal of HIV Medicine*. 2014;15(2):65-66.
- [16] Patel K, Panchasara A, Purohit B, Tripathi CB. Nevirapine and/or co-trimoxazole induced Stevens Johnson syndrome in HIV infected patient--a case report. *Curr Drug Saf*. 2013;8(1):72-74.
- [17] Cissé M, Soumah MM, Tounkara TM, Diané BF, Sack FB, Baldé H, et al. Lyell Syndrome with Fatal Outcome in Two Pregnant Women Receiving Antiretroviral Therapy in Guinea Conakry. *Journal of Cosmetics, Dermatological Sciences and Applications*. 2013;3:135-38.
- [18] Patel IB, Adiga S, Shetty DJ, Bairy KL. Nevirapine induced Stevens-Johnson syndrome: a case report. *Int J Basic Clin Pharmacol*. 2014;3:401-02.

PARTICULARS OF CONTRIBUTORS:

1. Post Graduate Trainee, Department of Clinical & Experimental Pharmacology, Calcutta School of Tropical Medicine, Kolkata, India.
2. Associate Professor, Department of Pharmacology, ICARE Institute of Medical Sciences & Research, Haldia, India.
3. Post Graduate Trainee, Department of Clinical & Experimental Pharmacology, Calcutta School of Tropical Medicine, Kolkata, India.
4. Professor, Department of Tropical Medicine, Calcutta School of Tropical Medicine, Kolkata, India.
5. Professor, Department of Clinical & Experimental Pharmacology, Calcutta School of Tropical Medicine, Kolkata, India.

NAME, ADDRESS, E-MAIL ID OF THE CORRESPONDING AUTHOR:

Dr. Sukanta Sen,
Associate Professor, Department of Pharmacology, ICARE Institute of Medical Sciences & Research,
Haldia-721645, India.
E-mail: drsukant@gmail.com

FINANCIAL OR OTHER COMPETING INTERESTS: None.

Date of Submission: **Aug 19, 2015**
Date of Peer Review: **Sep 19, 2015**
Date of Acceptance: **Jan 07, 2016**
Date of Publishing: **Mar 01, 2016**