

# Versatility of the Use of Collagen Membrane in Oral Cavity

N. POORNIMA SOWJANYA<sup>1</sup>, NAGAMALLESWARA RAO<sup>2</sup>, N.V.V. SATYA BHUSHAN<sup>3</sup>, GOKKULA KRISHNAN<sup>4</sup>

## ABSTRACT

**Introduction:** Bovine derived collagen membrane is usually and regularly used as a temporary cover or dressing for the extra oral wounds and for the burns on the body. It has wide applications because of its usefulness and biocompatibility. This has provoked us to do a study with the use of collagen membrane even for the intraoral minor surgical defects.

**Aim:** The study was conducted to evaluate the clinical efficacy of collagen membrane as a biological dressing material for intraoral wounds, to check for haemostasis, pain control, granulation tissue formation, rapid re-epithelialization and minimal contracture.

**Materials and Methods:** A total of 30 patients 19 male, 11 female were taken for excision of various intraoral lesions like leukoplakia patches, mucocele, epulis growths, irritational fibroma, frenectomy and the surgical defects were closed with collagen membrane. Postoperatively healing was assessed by taking five

clinical parameters of Haemostasis, Pain, Granulation tissue, Epithelialization, Contracture.

**Results:** Among 30 patients, haemostasis score was found to be good in 28 cases, fair in two cases. Pain relief score was good in seven cases, fair in 19 cases, poor in four cases. Granulation tissue formation score was good in eight cases, fair in 13 cases, poor in nine cases. Epithelialization score was good in 19 cases, fair in seven cases, poor in four cases. Contracture score was good in six cases, fair in 16 cases, poor in eight cases. Total score of all the five parameters, which was rated as effectiveness score, was calculated by using a standard scale. Final scoring was very effective in six cases, effective in 20 cases, ineffective in four cases.

**Conclusion:** Reconstituted bovine derived collagen membrane used in our study was found to be an effective intraoral wound dressing material for faster uneventful healing of intraorally also.

**Keywords:** Contracture, Epithelialization, Granulation tissue formation, Haemostasis, Pain, Wound dressing

## INTRODUCTION

The healing of wound is a sequence of cellular and biochemical activities, which aim towards restoring tissue integrity and functional capacity after injury [1]. Healing usually takes place uneventfully without any complications in most of the cases, but various intrinsic and extrinsic factors can affect the process.

Oral and maxillofacial surgical procedures often produce open wounds. A dressing material should cover these wounds to prevent microbial infection, foreign material contamination, wound contracture, and improve healing. The existence of a variety of wound types with varied healing modes and phases led to the evolution of different types of wound dressings.

Wound dressings before 1960s, were considered passive products that had a minimum role in the healing process [1]. Currently, oral mucosa or skin grafts are used as dressings; however, both these dressings have disadvantages in intraoral use like limited availability and presence of adnexal structures, abnormal tissue texture interfering with function respectively [1].

Therefore, there is search for an ideal dressing material to cover these defects. One such product is bovine derived collagen, a biologic material, which can be moulded into desired form and used in many clinical conditions as temporary dressing materials with favourable results [2-6]. Tolerance of xenogenous collagen by host tissue and its successful use as a temporary cover for raw areas in oral cavity was assessed.

## MATERIALS AND METHODS

This study of clinical evaluation of use of collagen membrane in intraoral defects was done in the Department of Oral and Maxillofacial Surgery; GITAM Dental College and Hospital, Visakhapatnam, Andhra Pradesh. Ethical committee clearance was obtained for doing the study with the use of bovine derived collagen membrane.

A total of 30 patients between 20-60 years, with ASA - grade 1 who requires intraoral dressing for the raw surfaces resulting from excision of premalignant lesions like leukoplakia, irritational growths, mucocele and pre-prosthetic surgical procedures were included in the study. Patients below 20 years and above 60 years of age, evidence of systemic or oral infection, uncontrolled systemic disorders i.e., ASA grade ii-vi are excluded from the study.

The collagen used in this study is a purified bovine reconstituted collagen. Reconstitution was done to remove atelocollagen component, which lowers its antigenicity. This reconstituted collagen is cross-linked with tanning agents like glutaraldehyde or chromium sulphate; to improve its tensile strength, to decrease its rate of resorption. Collagen membrane which comes in varying dimension of 5x5 cm, 10x10 cm and 25x25 cm, with thickness of 0.6mm, produced by EUCARE pharmaceuticals.

## Surgical Procedure

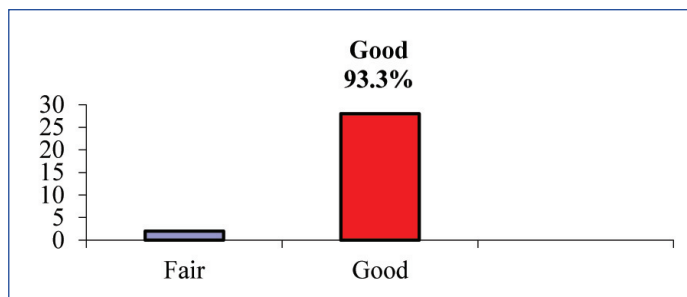
Relevant history was taken from the patients and careful clinical examination was done. Appropriate patient's consent was taken. Surgical excision of the intraoral lesion was done under local anaesthesia by following aseptic precautions. After surgical excision, haemostasis was attained. Collagen membrane is thoroughly washed in sterile saline solution (in order to remove the preserving medium). Membrane was trimmed according to wound size and quilting/nicks given to the membrane to facilitate drainage. It was stabilized and sutured to the edges of the wound. A few sutures were also given in the centre of the defect for appropriate membrane adaptation and drainage of the collected fluid below the membrane through the holes created in taking the bite for placing sutures.

## Parameters Assessed

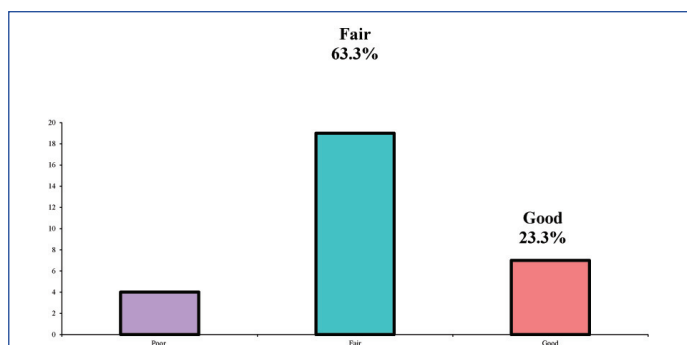
1. Haemostasis achieved by the membrane was assessed and scored on the day of surgery:

- 2 - GOOD - no bleeding or when bleeding stops with in 5 min
  - 1 FAIR -slight bleeding or no intervention required or haemostasis achieved after prolonged period i.e., more than 5 min
  - 0 - POOR -bleeding that required intervention for achieving haemostasis
2. Pain being subjective, assessed on the 4<sup>th</sup> postoperative day, based on patients own words:
    - 2 - GOOD (none to mild)
    - 1 - FAIR (moderate)
    - 0 - POOR (severe)
  3. Presence of granulation tissue noted at the end of two weeks as:
    - 2 - GOOD (entire wound)
    - 1 - FAIR (nearly the entire wound)
    - 0 - POOR (inadequate)
  4. Epithelialization noted at the end of the month as:
    - 2 - GOOD (entire wound)
    - 1 - FAIR (nearly the entire wound)
    - 0 - POOR (inadequate)
  5. Contracture of the wound at the end of the month was recorded:
    - 2 - GOOD (<25%)
    - 1 - FAIR (25 to 50%)
    - 0 - POOR (severe i.e. >50%)

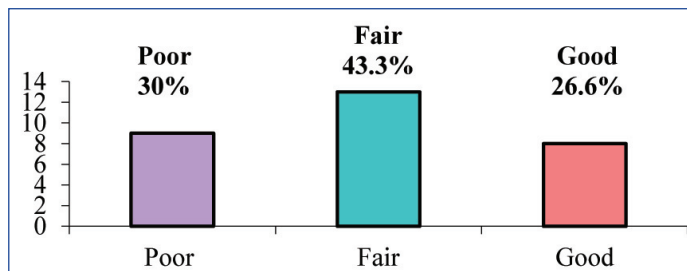
- [Table/Fig-6,7] shows total score of all the five parameters which is rated as effectiveness score .
  - Total score is 8-10 in 6 cases (20 %) - very effective,
  - Total score is 5-7 in 20 cases (66.6 %) - effective,
  - Total score is 0-4 in 4 cases (13.3%) - ineffective.



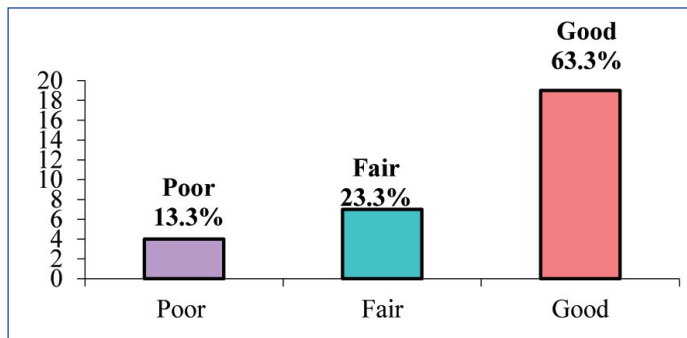
[Table/Fig-1]: Distribution of samples by Haemostasis.



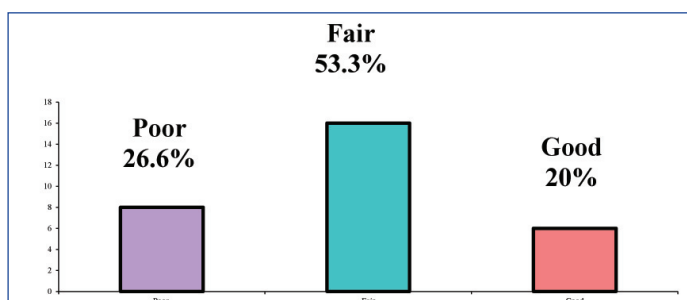
[Table/Fig-2]: Distribution of samples by pain.



[Table/Fig-3]: Distribution of samples by granulation tissue



[Table/Fig-4]: Distribution of samples by Epithelialization



[Table/Fig-5]: Distribution of samples by Contracture.

**Additional Paramaters Assessed:**

6. Conformability of the collagen sheet i.e. dressing ability.
7. Infection present or absent during the period of healing.
8. Adherence based on the ability of collagen to adhere to the wound after irrigating the area with sterile saline was recorded after suture removal.

The criteria for judgement of collagen dressing membrane with respect to the results obtained is based on the scoring pattern which was used by Bessho k et al., in their study of a new bi-layer artificial dermis for vestibular extension [5]. Using this scoring pattern effectiveness of collagen membrane was evaluated.

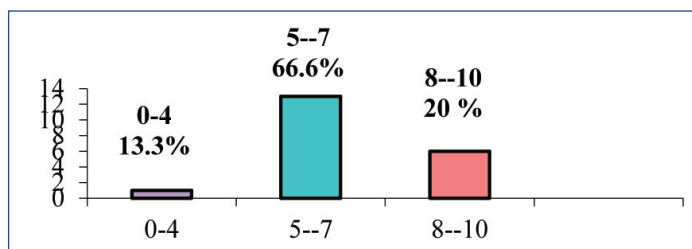
Effectiveness of the membrane was obtained by adding the scores of haemostasis, pain relief, granulation, epithelialization and contracture of the wound as:

- If total score is 8-10 - very effective
- If total score is 5-7 - effective
- If total score is 0-4 - in effective (bessho k et al., [5])

**RESULTS**

Collagen membrane was used as a dressing material for 30 intra oral raw wounds among which excision of epulis growths-4, mucocele-2, pyogenic granuloma-2, irritational firoma-6, leukoplakia patches-9, frenectomies-7.

- [Table/Fig-1] shows GOOD haemostasis in 28 cases (93.3%), FAIR in two cases (6.6%).
- [Table/Fig-2] shows pain relief is GOOD in seven cases (23.3%), FAIR in 19 cases (63.3%), POOR in 4 cases (13.3%).
- [Table/Fig-3] shows granulation is GOOD in eight cases (26.6%), FAIR in 13 cases (43.3%), POOR in 9 cases (30%).
- [Table/Fig-4] shows epithelialization is GOOD in 19 cases (63.3%), FAIR in 7 cases (23.3%), POOR in four cases (13.3%).
- [Table/Fig-5] shows contracture is GOOD in six cases (20%), FAIR in 16 cases (53.3%), POOR in eight cases (26.6%).



[Table/Fig-6]: Distribution of samples by effectiveness scores

Effectiveness	No of Samples	% of Samples
8-10(very effective)	6	20
5-7(effective)	20	66.6
0-4(in effective)	4	13.3
Total	30	100.0

[Table/Fig-7]: Distribution of Samples by Effectiveness Scores

## DISCUSSION

The raw wounds of the oral cavity, as any other wound heals by granulation and epithelialization as the oral environment is always moist with contamination from saliva and food, compounded by constant movements of cheek and tongue [2]. The risk of infection in the oral cavity is also quite high, which may result in scarring and contraction. The oral cavity is highly sensitive to any residual scarring, which may undergo ulceration and could be a constant source of irritation to patients wearing dentures. It has been well documented that the incidence of infection & degree of contraction are considerably reduced when wounds dressed rather than left exposed. Experiments have shown that dressings create physiological interface between the wound surface, environment and permits repair [2].

An ideal soft tissue dressing should promote haemostasis, prevent infection, reduce pain, promote granulation tissue formation, rapid re-epithelialization, reduces contracture and avoids the donor site morbidity [7]. With this view in mind, raw wounds in orofacial region were covered with skin graft, mucosal graft [8].

Collagen can be used as an alternative to the above mentioned graft materials to cover the intraoral surgical defects. As there is a large body of evidence that collagen is a common denominator in all stages of wound healing it serves as the key extracellular component for repair and remodelling [9]. Unique features of collagen membranes include guiding function, chemotactic property, haemostatic property and can resist masticatory forces for sufficient time and allows granulation tissue to form. Bovine xenogenous collagen membrane is easily obtainable which does not require second operation and its associated morbidity [7]. Abundant availability of the material does not impose dimensional limitations to the surgical site and immediate availability. Collagen dressings are found to have significantly fastened the healing process as collagen serves as the most important element in all stages of wound healing according to Paul US et al., [9].

A clinical study of 30 patients where the raw areas resulting from excision of epulis growths (8), mucocele (2), irritational fibromas (10), leukoplakia (4), pyogenic granuloma (2), frenectomies (11) were covered with collagen membrane. The parameters studied are haemostatic effect, pain relief, granulation tissue formation, re-epithelialization and the contracture of the wound.

Collagen membrane has a inherent property of haemostatic effect as it is a specific activator of platelets and helps in their adhesion to collagen fibre, aggregation. Study showed good haemostatic effect in 28 cases out of 30 (93.3%) and fair in two cases (6.6%) which is

in accordance with the study conducted by Zucker et al., mannai et al., which stated that collagen produces rapid haemostasis and strengthens the clot. In the ultra structural study, interactions of platelets with microfibrillar collagen is studied, the platelet adherent to collagen appeared to undergo an actual sequential morphologic change. Collagen acts as chemotactic factor for platelets, influencing their adhesion, aggregation, and release reaction according to the co-stasis multi-centric collaborative writing committee [10].

Collagen when used to cover the raw area provides the coverage for sensitive nerve endings thereby diminishing degree of pain. As collagen is a natural substrate of extracellular matrix, is chemotactic to various cell types such as endothelial cells, fibroblasts there by leading to reduced inflammatory process which contributes to reduced pain and burning sensation. Pain relief was not achieved in four cases, wherein the collagen membrane was lost during early phase of healing. In rest of the cases the pain relief was rated as good in seven cases (23.3%) and fair in 19 cases (63.3%). This result is in accordance with the study conducted by Raghavendra Reddy et al., Paul US et al., Shobha Natraj et al., [3,9,11].

Collagen dressings encourage wound healing through early deposition and organization of granulation tissue. It facilitates migration of fibroblasts in to the wound bed, encourages the metabolic activity of granulation tissue. Results showed as good in 8 cases (26.6%), fair in 13 cases (43.3%), poor in 9 cases (30%) which are in accordance with the studies of Onkar Singh et al., K Bessho and Muramaki et al., Shobha Natraj et al., [3-5].

Collagen membrane is known to stabilize the coagulum and enhances the early epithelial proliferation from the surrounding tissues. Good epithelialization was achieved in 19 cases (63.3%), fair in seven cases (23.3%), poor in four cases (13.3%) which are in accordance with the studies of Thoma et al., K Bessho and Shobha Nataraj et al., [3,4,12]. Faster re-epithelialization achieved with better colour match to the adjacent normal tissues.

The most important method for controlling scarring is by controlling infection and fastening re-epithelialization, collagen fulfils these goals, there by prevents scar contracture (Sanjay Rastogi [2]), contracture is found to be good in six cases (20%), fair in 16 cases (53.3%), poor in eight cases (26.6%). The results achieved are similar to that of the results of Masaki Fujioka et al., S Wakami et al., Herford et al., Shobha Nataraj et al., [3,7,13,14].

In our study collagen dressings showed accelerated healing process in accordance with the studies of M Shanmugam et al., Thoma et al., Omkar Singh, this may be explained through the formation of a gelatinized coagulum containing abundant amount of fibrinogen and fibronectin which contains high concentrations of chemo attractants, growth factors help in deposition and organization of freshly formed fibres [4,12,15]. Granulation tissue facilitates migration of fibroblasts in to the wound bed. Tissue biopsy with detailed histopathological study at frequent intervals is necessary to establish the fact that initial adherence and faster uneventful healing is possible by the use of collagen membrane for intraoral wounds, which is lacking in our study and is recommended in future studies.

Collagen membrane is supple & adapted to the wound no matter what the contour is. It was observed that membrane had good adherence to mucosa and wound bed. The adherence of collagen membrane is initially due to fibrin collagen interaction & later due to fibro vascular in growth into the collagen membrane [1,15]. This study had no histological study conducted to prove this fact.

Collagen membrane was robust enough to resist masticatory forces for certain time, to allow granulation tissue to form, later it underwent collagenolysis. The preparation of stents for larger defect is necessary to hold the collagen membrane close to the tissues

until the initial phase of healing occurs, but for practical purpose it becomes difficult to fabricate, adapt and secure the stent in the intraoral region, for this reason it may be suggested that reinforced collagen membranes can be used in the areas where the wound bed is mobile i.e., buccal and labial mucosa and the normal collagen membrane can be used where the wound bed is stable like alveolus and palate.

Collagen appears to be biocompatible with no significant immune rejection with biodegradable characteristics in accordance to Marvin p levin, y Raghavendra reddy et al., David J Mishkin et al., AK Schlegel et al., K Bessho and Shobha Nataraj et al., Sanjay Rastogi et al., Omura et al., [2,3,6,11,16-18]. None of the case showed adverse or allergic reaction to the collagen proving its safety as a biological dressing. This result is in accordance with Y Raghavendra Reddy et al., [11].

## LIMITATION

Limitations in this study are that in four cases of our study, (one on palate, second one in retro molar area) there was loss of collagen membrane because of continuous movements of tongue and membrane in the line of occlusion. Stabilization of the membrane to the surgical defect in this present study was done by suturing the membrane to the edges of the defect, which was a time taking and delicate procedure. It should be done without damaging the membrane. It can be recommended that the use of biological glue such as cyanoacrylates for this purpose can be tried in future study.

## CONCLUSION

Reconstituted bovine derived, collagen membrane used in our study was found to be a useful dressing material to cover the raw areas of the oral cavity secondary to surgical excision of small lesions and where the base of the defect is immobile. Simple chair side application, ease of availability, no donor site morbidity, biocompatibility and better cosmesis makes the collagen membrane an ideal intraoral wound dressing material for faster uneventful healing.

## REFERENCES

- [1] Purna Sai K, Babu M. Collagen based dressings-a review. *Burns*. 2000;26:54-62.
- [2] Rastogi S, Modi M, Sathian B. The efficacy of collagen membrane as a biodegradable wound dressing material for surgical defects. *Journal of Oral and Maxillofacial Surgery*. 2009;67:1600-06.
- [3] Natraj S, Guruprasad Y, Jaya Shetty PN. A Comparative clinical evaluation of buccal fat pad and collagen in surgical management of OSMF. *Archives of Dental Sciences*. 2011;2(4):17-24.
- [4] Singh O, Gupta SS, Mosses S, Shukla S. Collagen dressing versus conventional dressings. *Journal of Cutaneous and Aesthetic Surgery*. 2011;4(1):12-6.
- [5] Bessho K, Muramaki K, Iizuka T. The use of a new bilayer artificial dermis for vestibular extension. *British Journal of Oral and Maxillofacial Surgery*. 1998; 36:457-59.
- [6] Schlegel AK, Mohler H, Busch F, Mehl A. Pre clinical and clinical studies of a collagen membrane. *Journal of Biomaterials*. 1997;18:535-38.
- [7] Herford AS, Akin L, Cicciu M, Maiorana C. Use of porcine collagen matrix as an alternative to autologous tissue for oral soft tissue defects. *Journal of Oral and Maxillofacial Surgery*. 2010;68(7):1463-70.
- [8] Izumi K, Feinberg SE. Skin and Oral Mucosal Substitutes. *Oral Maxillofacial Surg Clin N Am*. 2002;14:61-71.
- [9] Paul US, Singh RK, Mohamad S, Rajesh kumar Yadav. Use of collagen in extra oral wounds. *Journal of Maxillofacial Oral Surgery*. 2008;3:261-64.
- [10] Costasis Multi-centre Collaborative Writing Committee. A Novel collagen-based composite offers effective hemostasis for multiple surgical indications: Results of a randomized controlled trial. *Surgery*. 2001;129:445-50.
- [11] Raghavendra Reddy Y, Srinath N, Nandakumar H, Rajini Kanth M. Role of collagen impregnated with dexamethasone and placetrin in patients with oral submucous fibrosis. *J Maxillofac Oral Surg*. 2012;11(2):166-70.
- [12] Thoma DS, Sancho-Puchades M, Ettlin DA, Hämmerle CHF, Jung RE. Impact of collagen matrix on early healing, aesthetics and patient morbidity in oral mucosal wounds. *Journal of clinical periodontal- a randomized study in humans*. *Journal of Clinical Periodontology*. 2012;39(2):157-65. 10.1111/jcpe.
- [13] Fujioka M, Fuji T. Maxillary growth following atelocollagen implantation on mucoperiosteal denudation of the palatal process in young rabbits: implications for clinical cleft palate repair. *Cleft Palate-Craniofacial Journal*. 1997;34(4):292-96.
- [14] Wakami S, Harada T, Muraoka M. Rectangular mucosal flap with artificial dermis grafting for vermilion deformity in cleft lips. *Journal of Plastic, Reconstructive, Aesthetic Surgery*. 2010;63:22-27.
- [15] Shanmugam M, Kumar TSS, Arun KV, Arun R. Clinical and histological evaluation of two dressing materials in the healing of palatal wounds. *Journal of Indian Society of Periodontology*. 2014;14(4):241-44.
- [16] Levin MP, Tsakins PJ, Cutright DE. Healing of the oral mucosa with the use of collagen artificial skin. *J periodontol*. 1979;50(5):250-53.
- [17] Mishkin DJ, Davis MA, Neville BW. Use of solubilized bovine derived collagen as a xenogenic grafting material. *Journal of Prosthetic Dentistry*. 1985;54(2):290-96.
- [18] Omura S, Mizuki N, Horimoto S, Kawabe R, Fujita K. A newly developed collagen/silicone bilayer membrane as a mucosal substitute: a preliminary report. *British Journal of Oral and Maxillofacial Surgery*. 1997;35:85-91.

### PARTICULARS OF CONTRIBUTORS:

1. Assistant Professor, Department of Oral and Maxillofacial Surgery, Vishnu Dental College and Hospital, Bhimavaram, Andhra Pradesh, India.
2. Assistant Professor, Department of Oral and Maxillofacial Surgery, KIMS Dental College and Hospital, Amalapuram, Andhra Pradesh, India.
3. Professor and Guide, Department of Oral and Maxillofacial Surgery, GITAM Dental College and Hospital, Vishakapatnam, Andhra Pradesh, India
4. Professor and Head, Department of Oral and Maxillofacial Surgery, GITAM Dental College and Hospital, Vishakapatnam, Andhra Pradesh, India.

### NAME, ADDRESS, E-MAIL ID OF THE CORRESPONDING AUTHOR:

Dr. N. Poornima Sowjanya,  
Assistant Professor, Department of Oral and Maxillofacial Surgery, Vishnu Dental College and Hospital,  
Bhimavaram, Andhra Pradesh, India.  
E-mail: dr.soujanyaomfs@gmail.com

FINANCIAL OR OTHER COMPETING INTERESTS: None.

Date of Submission: **Aug 04, 2015**

Date of Peer Review: **Sep 27, 2015**

Date of Acceptance: **Oct 31, 2015**

Date of Publishing: **Feb 01, 2016**