

# Heterogeneity of Nasolabial Flap- Role in Prevention of Morbidity Associated with Reconstruction of Orofacial Defects

ROSHNI ABIDA<sup>1</sup>, MUHAMED SAJID AYYALLIL<sup>2</sup>

## ABSTRACT

Reconstructive technique after surgical excision of malignancy in orofacial region should be planned in preoperative period itself. Surgery is the preferred modality of treatment if the tumour is small and located in an accessible area. Nasolabial flap is a versatile flap which is well suited to cover small defects in maxillofacial region. Nasolabial flap can be used as an alternative to other distant pedicled flaps in selected cases. A retrospective analysis of 12 cases of oral cancer treated with primary excision and reconstruction using nasolabial flap was done. Patients who underwent resection of tumour and reconstruction with nasolabial flap in selected cases reduced the morbidity associated with Distant pedicled flaps. Two selected cases are described in detail.

**Keywords:** Axial pattern flap, Facial artery, Local flap, Orofacial malignancy

## CASE REPORT 1

A 67-year-old patient presented with lesion in the posterior part of anterior two thirds of the tongue [Table/Fig-1a]. Clinically this was a T2 lesion with no significant lymph node in the neck. Lesion was biopsied and reported as well differentiated squamous cell carcinoma. Trans oral resection was done via mandibulotomy incision with Clearance [Table/Fig-1b]. Flap outlined [Table/Fig-1c], and following this inferiorly based nasolabial flap was tunneled into oral cavity and sutured to cover the defect [Table/Fig-1d] Postoperative follow up done [Table/Fig-1e]. Patient was send for adjuvant therapy (radiotherapy) after complete wound healing.

## CASE REPORT 2

A 59-year-old male patient with lesion on the right nasal ala which was diagnosed as basal cell carcinoma clinically. Lesion was biopsied and the diagnosis was confirmed [Table/Fig-2a]. Wide excision of the lesion was done, A defect of about 2.5 × 2 cm was noted [Table/Fig-2b]. Nasolabial flap was outlined [Table/Fig-2c] and rotated and sutured to the defect [Table/Fig-2d]. Wound healed satisfactory [Table/Fig-2e]. Postoperative followup upto one year did not show any recurrence.

## SURGICAL TECHNIQUE

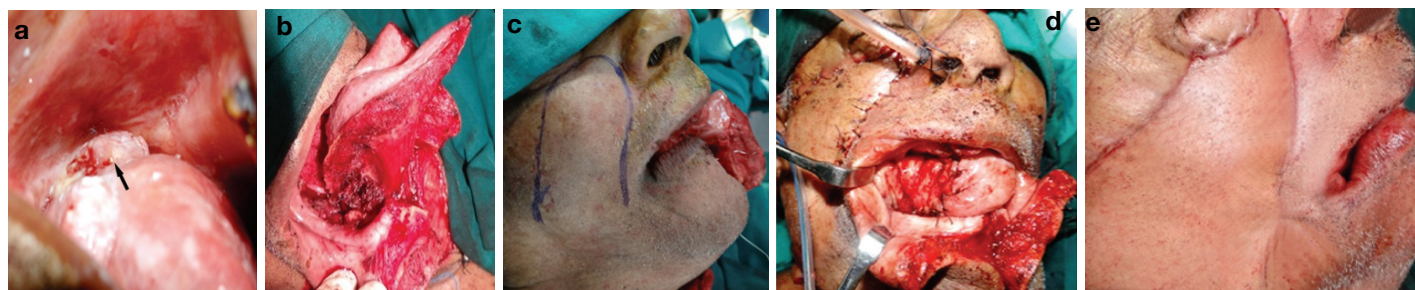
The lesion is excised. Flap is designed based on position of blood vessel. The skin incision is deepened through dermis and subcutaneous fat to

the level of underlying facial muscles. The flap can be elevated upwards from base, lateral to angle of mouth and superficial to facial muscle. Flap should stop short of canthal area so as to avoid ectropion. In case of lesions on face the flap is rotated to cover the defect.

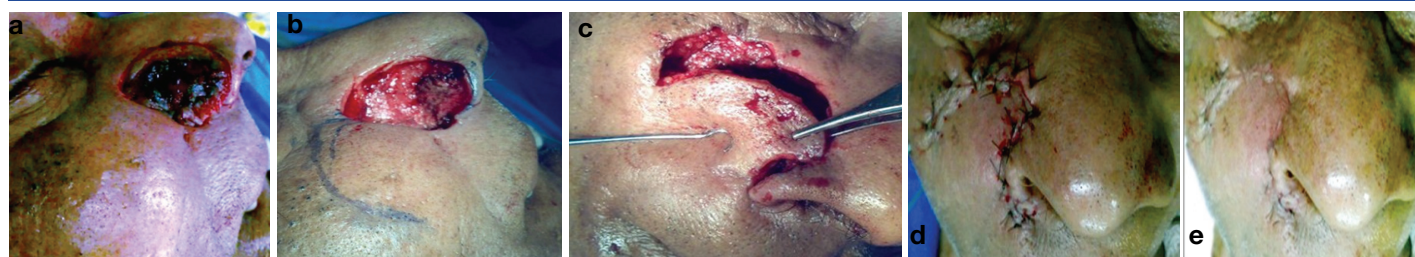If the lesion is in the intraoral region, after excision of lesion flap is designed and a tunnel can be made through soft tissue in the cheek area, near the base of the flap. Through this tunnel the flap is brought into the oral cavity. Tunnel should be adequately wide to accommodate the flap. Then the flap can be sutured to the defect in the oral cavity. The flap is usually divided at the end of three weeks. If inseting of flap is done it should be done as a second stage procedure. In a single stage surgical procedure the flap can be deepithelialized.

## DISCUSSION

Squamous cell carcinoma is the most common malignancy involving the oral cavity. The highest number of oral squamous cell carcinoma cases is seen in Indian subcontinent due to habits like chewing tobacco, betel quid and areca nut [1]. Squamous cell carcinoma is managed by various treatment modalities like surgery, radiation and chemotherapy in combination or as single modality of treatment (surgery or radiotherapy). When surgery is the initial treatment Modality especially for early stages (T stage), nasolabial flaps can be used for reconstruction after resection of tumour. This is a reliable flap with minimum donor defect. Nasolabial flap is an axial pattern flap which can be used unilaterally or bilaterally with arterial



[Table/Fig-1]: (a) Lesion on the tongue (b) Lesion excised (c) Flap outlined (d) Nasolabial flap sutured to tongue (e) Postoperative photo



[Table/Fig-2]: (a) Lesion on the nose (b) Lesion excised (c) Nasolabial flap rotated into the defect (d) Nasolabial flap sutured (e) Postoperative

supply from facial artery or superficial temporal artery depending on the need for inferior or superior based flaps [2]. Inferiorly based nasolabial flaps can be tunnelled intraorally to reconstruct defects in the floor of mouth [3]. Superiorly based flaps can be used in reconstruction of extra oral defects.

A total of 12 patients with orofacial malignancy underwent resection of tumour and reconstruction using nasolabial flap during 2011 to 2014. Age of the patient's ranged from 48 to 67 years. Primary tumour was located in tongue, anterior floor of mouth, nasal region and cheek area. Patient details including age, sex, aetiology and history of habits were documented [Table/Fig-3]. Nine cases were squamous cell carcinoma while the other three cases were reported as basal cell carcinoma. Four cases were of squamous cell carcinoma involving anterior two thirds of tongue. Three cases of squamous cell carcinoma involved anterior part of floor of mouth. Out of the three malignancy involving the cheek two were squamous cell carcinoma while one involved skin of the cheek which was basal cell carcinoma. Other two cases of basal cell carcinoma were seen on the nose. In all the cases a prior biopsy was taken and histopathologically proved to be malignant. A retrospective data analysis was performed using data collected from patients operating records including the pathology of the lesion and size of the defect. This was a retrospective study and was exempted from institutional review board, but a written informed was taken from the patient to utilise the data and photographs for publication.

To prevent cancer is to reduce the incidence of disease by early detection of cancer and preventive protocols like health education campaigns [4]. A careful yearly examination of mouth in all persons above 40 years especially with high risk behaviour will help in early detection of oral cancer [5]. The aim of surgical treatment in orofacial cancer is to eradicate the disease, prevent recurrence and most importantly restoration of form and function of excised region.

	Number
<b>Gender</b>	
Male	9
Female	3
<b>Age</b>	
Range	48 -67
Mean	57.5
<b>Disease</b>	
Squamous cell carcinoma	9
Basal cell carcinoma	3
<b>Donor site</b>	
Left	7
Right	5
<b>Site of the defect</b>	
Tongue	4
Anterior floor of mouth	3
Nasal region	2
Cheek	3

**[Table/Fig-3]:** Characteristics of patient who underwent reconstruction with nasolabial flap

## PLANNING OF TREATMENT

Once diagnosis is confirmed it is very important for good outcome. Based on clinical stage of disease the treatment modalities may be surgery, radiotherapy, chemotherapy and targeted therapy in combination or as a single modality of treatment [6].

Surgery is preferred for small to moderate defects after excision of tumour located in an accessible area [7].

For small to moderate defects in orofacial region after resection of malignant tumour, nasolabial flap can be utilised [8]. Nasolabial flaps are shown to give good aesthetic result and less morbidity to donor site. Flap is easy to raise and minimizes the problems related to speech and swallowing to greater extent. Flaps can be selected depending on various factors like the defect size and site [9]. Small defects by excision of tumour can be closed by local flaps [10]. Studies by Maurer et al., on 23 patients who had prosthetic rehabilitation after nasolabial flap reconstruction found functional and esthetical superiority compared to free tissue transfer [11]. Varghese et al., in the series of 238 patients showed loss of flap only in 6.3% [2]. Inset of flap as a second procedure is not a necessity in nasolabial Flap reconstruction. A significant advantage with nasolabial flap is reduction in morbidity compared with distant pedicled flap or free flap. Reduction in morbidity as well as cost in addition to decreased operating Time are key factors that weigh the balance towards the use of nasolabial flap [12]. Other advantages of nasolabial Flap include reasonable thickness which will fit well with the defect in oral cavity [13].

## CONCLUSION

With its easiness to design, constant vascularity, matching tissue thickness and nearness to selected defects nasolabial flaps remain a good alternative to distant pedicled or free flaps. In era of cost effectiveness nasolabial flap in ideal cases reduces the morbidity and hospital stay. Thus based on our experience we conclude that nasolabial flap is a reliable reconstructive modality for small to moderate sized defects in orofacial region.

## REFERENCES

- Attar E, Dey S, Hablas A, Seifeldm IA, Ramadan M, Rozek LS, et al. Head and neck cancer in a devolving country: A population based perceptive across 8 yrs. *Oral Oncology*. 2010;46(8):591-95.
- Varghese BT, Sebastin P, Cherian T, Mohan PM, Ahmed I, Koshy CM, et al. Nasolabial flap in oral reconstruction an analysis of 224 cases. *Brit J Plast Surg*. 2001;54:499-503.
- Ikedo C, Katakura A, Yamamoto N, Kamiyama I, Shibahara T, Onodo N, et al. Nasolabial reconstruction of floor of mouth. *Bull Tokyo Dent coll*. 2007;48:187-92.
- Peterson PE. Oral cancer prevention and control :The Approach of world health organisation. *Oral Oncology*. 2009;45(4):454-60.
- Neville BW, Day TA. Oral cancer and precancerous lesions. *CA A Cancer Journal of Clinicians*. 2002; 5:195-215.
- Rapidis AD, Gullane P, Langdon JD, Lefebvre JL, Scully C, Shah JP. Major Advances in Knowledge and Understanding of epidemiology, Aetiopathogenesis, Diagnosis, Management and Prognosis of oral cancer. *Oral Oncology*. 2009;45(6):299-300.
- Rodriguez EA, Carretero JLC, Moran MJ. Versatility of nasolabial flap in oral cavity reconstruction. *Med Oral Patol Oral Cir Bucal*. 2014;19(5):525-30.
- Heller L, Cole P, Kaufman Y. Cheek reconstruction: Current concepts in managing facial soft tissue loss. *Semin Plast Surg*. 2008;22(4):294-305.
- Multani JS, Nagi GS, Bajwa BB. Local and locoregional Flaps in head and neck defects. *Journal of Evolution of Medical and Dental Science*. 2015;4(1):12-6.
- Druz AK, Chaukar D, Gupte T. Guide lines for head and neck cancer: Evidence based management of cancer in india. *Tata Memorial Centre*. 2012;11:15-6.
- Maurer P, Eckert AW, Schubert J. Functional rehabilitation following resection of floor of mouth: the nasolabial flap revisited. *J Craniomaxillofac Surg*. 2002;30:369-72.
- Braasch DC, Lam D, Soh E. Maxillofacial reconstruction with nasolabial and facial artery musculomucosal flaps. *Oral and Maxillofacial Surgery Clinics*. 2014;26(3):327-33.
- Mukul SK, Weihsin H, Ranjan S, Pandey S. Inferiorly based nasolabial flap as a back up flap: A surgical case report. *International Journal of Clinical Dental Sciences*. 2012;3(2). 44-48.

### PARTICULARS OF CONTRIBUTORS:

- Professor, Department of Oral and Maxillofacial Surgery, Mes Dental College and Hospital, Perinthalmanna- Malapuram, Kerala, India.
- Professor, Department of General Surgery, Mes Dental College and Hospital, Perinthalmanna- Malapuram, Kerala, India.

### NAME, ADDRESS, E-MAIL ID OF THE CORRESPONDING AUTHOR:

Dr. Roshni Abida,  
No.25, Gift, Belhaven Gardens, Kawdiar- Trivandrum, Kerala-695003, India.  
E-mail: roshnidr2015@gmail.com

**FINANCIAL OR OTHER COMPETING INTERESTS:** None.

Date of Submission: **Apr 29, 2015**

Date of Peer Review: **Jun 04, 2015**

Date of Acceptance: **Jul 15, 2015**

Date of Publishing: **Sep 01, 2015**