

Intra-Arterial Angiolymphoid Hyperplasia with Eosinophilia: A Rare Case Report of Peripheral Medium Sized Muscular Artery Involvement

ASHIMA AMIN¹, T. UMASHANKAR², CHRYSSELLE OLIVE DSOUZA³

ABSTRACT

Angiolymphoid hyperplasia with eosinophilia (ALHE) is an uncommon benign vasoproliferative disease with distinct clinical and histopathological features. The most common clinical presentation is dermal and subcutaneous painless nodules in the head and neck region. The involvement of medium sized peripheral muscular artery is uncommon. It predominantly affects Caucasian adults during the third and fourth decades, but is also known to occur in Asians and it very rarely occurs in children. We here by present a case of intravascular ALHE in a 46-year-old female presenting with subcutaneous forearm nodule clinically diagnosed as ulnar artery thrombosis.

CASE REPORT

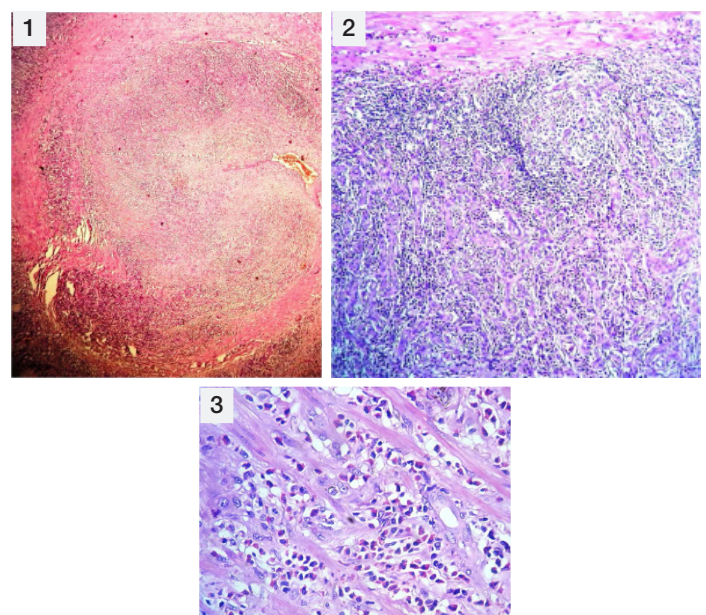
A 46-year-old female patient presented with painless swelling over the volar aspect of distal 1/3rd of right forearm from one and half month duration. It was insidious in onset and gradually progressive. Patient gave a past history of eosinophilia. However, her pre surgery complete blood counts were within normal limits and did not reveal any eosinophilia. There was no history of fever or trauma. On examination, the swelling was non tender, 3 x 4 cm and was parallel to the long axis of the forearm. There was no local rise of temperature. It was not attached to bone and the overlying skin was normal without any scars, sinuses or wounds. The radial and ulnar artery pulsations were normal and there were no distal motor or sensory deficits. There was no evidence of lymphadenopathy or hepatosplenomegaly. Ultrasonography, revealed a well defined, solid vascular lesion in the right lower 1/3rd of the forearm and an impression of possibility of pseudoaneurysm of ulnar artery with haematoma and recanalization was given. Clinically, a provisional diagnosis of right ulnar artery thrombosis was done. Complete surgical excision of the 1 cm segment of the artery was performed with end repair using a venous graft. The excised segment was sent for histopathological examination. Grossly the thickened ulnar arterial segment measured 3.5 cm in length. Cut section showed thickened wall with stenosed lumen. Microscopy showed thickened and distorted tunica media and adventitia with proliferation of small sized capillaries lined by epithelioid endothelial cells surrounded by stromal lymphoid aggregates, eosinophils and multinucleate giant cells. A few reactive lymphoid follicles were also seen. No mitoses or atypical cells were observed [Table/Fig-1-3].

On post surgery follow up, the patient was free of symptoms.

DISCUSSION

ALHE was first described by Wells and Whimster in 1969 [1]. The other names given to this entity are pseudo or atypical pyogenic granuloma, subcutaneous angioblastic lymphoid hyperplasia with eosinophilia, inflammatory angiomatous nodules, epithelioid haemangioma and papular angioplastia. ALHE is more common in young to middle aged females and is known to be more common in Asians and Caucasians. One-fifth of the patients have peripheral blood eosinophilia and lymphadenopathy [2]. Jeon et al., reported a case of ALHE in a two-year-old Korean boy possibly induced by

Keywords: Forearm nodule, Vasoproliferative, Ulnar artery



[Table/Fig-1]: Scanner view of the stenosed artery (H&E x40)

[Table/Fig-2]: Low power view showing proliferated blood vessel lined and reactive lymphoid follicles (H&E x 100)

[Table/Fig-3]: High power view showing epithelioid endothelial cells and a eosinophil rich infiltrate (H&E x400)

vaccination [3]. It presents as subcutaneous nodules or papules, especially in the head and neck region [4]. ALHE has also been reported in the scalp, lip, tongue, scrotum, breast, orbits and the conjunctiva. Although the presence of a medium sized artery near ALHE is not uncommon, the development of ALHE inside a muscular artery is rarely seen. ALHE has been reported in muscular arteries which include the temporal artery, radial artery, facial artery, post auricular artery, popliteal artery, brachial artery, occipital artery, ulnar artery and axillary artery [5].

Histologically, the lesions comprise of reactive proliferation of thin and thick walled blood vessels often surrounding a muscular artery with a peripheral inflammatory infiltrate in which lymphoid aggregates occasionally forming germinal centres and eosinophils are conspicuous. The blood vessels are lined by epithelioid endothelial cells. The more actively proliferating lesions appear an-gioendo

the liomatous with atypical features leading to false diagnosis of malignant angio-endothelioma. ALHE can cause considerable difficulty which can lead to repeated biopsies. Parasites or other organisms have not been demonstrated despite the presence of eosinophilia in the blood and tissues [6].

Kimura's disease and organized thrombosis should be put into the differential diagnosis of ALHE. Due to the similarities between Kimura disease and ALHE, they were previously considered to be a part of single disease spectrum. However, Rosai et al., [7] recognized that Kimura's disease and ALHE different in terms of their histopathological features and they suggested that they are distinct entities. Kimura disease is usually located in the subcutaneous tissue of the head and neck, with systemic lymphadenopathy, marked eosinophilia, and elevated serum immunoglobulin E level.

Histopathology shows eosinophil and lymphocyte infiltration with obvious lymphoid follicle distinct eosinophilic microabscesses and a lack of epithelioid endothelial cell proliferation. Organized thrombosis implies a vessel that has been obstructed by connective tissue composed of numerous neovessels with varying degrees of recanalization.

The pathogenesis of ALHE is unknown. It has been considered to be a vascular neoplasm of unknown aetiology. Trauma as an initiating factor was suggested by Morton et al., [8]. Mast cells expressing interleukin-5 and vascular endothelial growth factor may play a role in the development of ALHE.

CONCLUSION

Angiolymphoid hyperplasia with eosinophilia involving the ulnar artery can be mistaken for a thrombotic lesion. The diagnosis is often challenging and an accurate histopathological diagnosis can prevent unnecessary rebiopsies.

REFERENCES

- [1] Wells GC, Whimster IW. Subcutaneous angiolymphoid hyperplasia with eosinophilia. *Br J Dermatol.* 1969;81:1-14.
- [2] Kempf W, Haeffner AC, Zepter K, Sander CA, Flaig MJ, Mueller B, et al. Angiolymphoid hyperplasia with eosinophilia: evidence for a t-cell lymphoproliferative origin. *Human Pathology.* 2002;33:1023-29.
- [3] Jeon EK, Cho AY, Kim MY, Lee Y, Seo YJ, Park JK, et al. Angiolymphoid hyperplasia with eosinophilia that was possibly induced by vaccination in a child. *Ann Dermatol.* 2009;21(1):71-74.
- [4] Reed RJ, Terazakis N. Subcutaneous angioblastic lymphoid hyperplasia with eosinophilia (Kimura's disease). *Cancer.* 1972;20:489-97.
- [5] Hsiao HT, Wu YH. Intra-arterial angiolymphoid hyperplasia with eosinophilia of the temporal artery: Report of two cases and review of the literature. *Dermatologica Sinica.* 2012;30:79-100.
- [6] Saxe N, Norma LB. Angiolymphoid hyperplasia with eosinophilia report of 3 cases. *South Afr Med J.* 1977;52:454-57.
- [7] Rosai J, Gold J, Landy R. The histiocytoid hemangiomas. Aunifying concept embracing several previously described entities of skin, soft tissue, large vessels, bone and heart. *Human Pathol.* 1979;10:703-30.
- [8] Morton K, Robertson AJ, Hadden W. Angiolymphoid hyperplasia with eosinophilia: report of a case arising from radial artery. *Histopathology.* 1987;11:963-69.

PARTICULARS OF CONTRIBUTORS:

1. Assistant Professor, Department of Pathology, Father Muller Medical College and Hospita, Kankanady, Mangalore, Karnataka, India.
2. Professor, Department of Pathology, Father Muller Medical College and Hospital, Kankanady, Mangalore, Karnataka, India.
3. Postgraduate Student, Department of Pathology, Father Muller Medical College and Hospital, Kankanady, Mangalore, Karnataka, India.

NAME, ADDRESS, E-MAIL ID OF THE CORRESPONDING AUTHOR:

Dr. Ashima Amin,
Department of Pathology, Father Muller Medical College and Hospital, Kankanady,
Mangalore, Karnataka-575002, India.
E-mail: dr_ashim13@yahoo.com

FINANCIAL OR OTHER COMPETING INTERESTS: None.

Date of Submission: **Jan 23, 2015**
Date of Peer Review: **Apr 28, 2015**
Date of Acceptance: **May 29, 2015**
Date of Publishing: **Aug 01, 2015**