

JOURNAL OF CLINICAL AND DIAGNOSTIC RESEARCH

How to cite this article:

PANDEY P, DIXIT A, KAUR S. MIXED ENDOMETRIAL STROMAL TUMOR WITH SMOOTH MUSCLE DIFFERENTIATION: A REPORT OF TWO CASES. Journal of Clinical and Diagnostic Research [serial online] 2010 February [cited: 2010 February 1]; 3:2071-2075.

Available from

http://www.jcdr.net/back_issues.asp?issn=0973-709x&year=2010 &month=February &volume=4&issue=1&page=2071-2075 &id=529

CASE REPORT

Mixed Endometrial Stromal Tumor With Smooth Muscle Differentiation: A Report Of Two Cases

PANDEY P*, DIXIT A**, KAUR S***

ABSTRACT

Endometrial stromal tumours (ESTs) are the second most common mesenchymal tumours of the uterus, even though they account for < 10% of all such tumours. Their characteristic feature is that of uniform small cells closely resembling proliferative endometrial stromal cells. If sizable smooth muscle differentiation is present (one third or more of the tumour mass), the neoplasm is referred to as combined smooth muscle-stromal tumour or nodular stromomyoma. Endometrial stromal tumours (ESTs) are diagnosed in most instances by light microscopy. Often, the greatest challenge is to distinguish between different subtypes of these tumours. In this article, we report the morphological features of two cases of endometrial stromal nodule, presenting as fibroid uterus in a hysterectomy specimen.

Key Words: Endometrium, Stromal tumour, Smooth muscle differentiation

*,*** Dept. Of Pathology,**Dept.of Pharmacology
M M Institute of Medical Sciences
& Research, Mullana, Ambala.(India)
Corresponding Author:
Dr. Pinki Pandey
D-71, MMIMSR Campus,
M M University, Mullana
AMBALA. -133203
Mobile: 09416825149
E mail: alkdxt@yahoo.co.in

Introduction

Endometrial stromal tumours (ESTs) are the second most common mesenchymal tumours of the uterus, even though they account for < 10% of all such tumours[1]. In the latest World Health Organization classification [2] of 2003, ESTs are classified as:

- a) Endometrial stromal nodule (ESN)
- b) Low grade endometrial stromal sarcoma (ESS)
- c) Undifferentiated endometrial sarcoma (UES)

ESTs occur in middle aged woman (average age - 45 yrs.) and often present with vaginal

bleeding [3]. Uterine tumours which are composed of a prominent component of smooth muscle and endometrial stroma (so called stromomyoma) have received little attention in the literature.

Endometrial stromal tumours (ESTs) are diagnosed in most instances by light microscopy. Often, the greatest challenge is to distinguish between the different subtypes of these tumours viz highly cellular leiomyoma, low grade endometrial stromal sarcoma and uterine tumours resembling sex cord tumours.

We are reporting here the morphological features of two cases of endometrial stromal nodules.

Case Report

Case Number 1

A 42 year old female patient was admitted for the complaints of mass abdomen and polymenorrhagia of two years duration. On clinical examination, the uterus was found to be bulky and firm. Ultrasound scan of the abdomen revealed a fundal leiomyoma (4 x 4 cms.). Based on these features, a clinical diagnosis of fibroid uterus was made. Total abdominal hysterectomy with one sided salpingo-oophorectomy was performed. The postoperative course was uneventful.

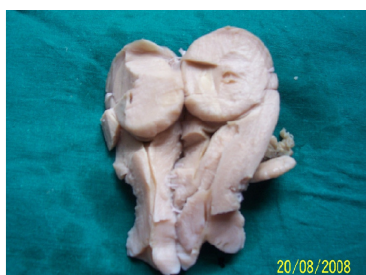Case Number 2

A 45 year old female presented with abdominal pain and menorrhagia of 9 months duration. A clinical diagnosis of dysfunctional uterine bleeding was made and she underwent total abdominal hysterectomy and unilateral salpingo-oophorectomy. Peroperatively, a diagnosis of intramural fibroid was made. The postoperative course was uneventful.

Pathological Findings

Macroscopic Description

Case 1: The hysterectomy specimen was received, measuring 11x6x4 cms. The cut section revealed that the endometrial cavity was pushed to one side by an intramural tumour measuring 4 x 4 cms. The tumour was well circumscribed, non-encapsulated with pushing margins, solitary, soft yellowish white in colour and bulging above the surrounding myometrium [Table/Fig 1].



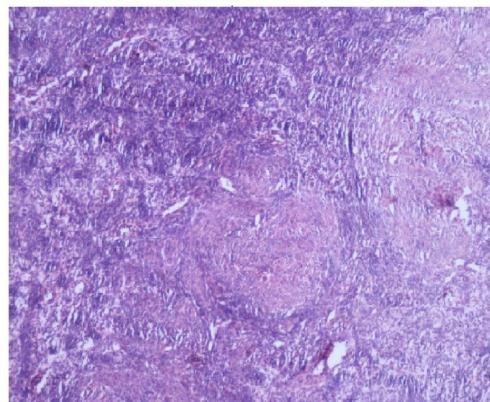
(Table/Fig 1) Gross photograph of the cut section of uterus showing a large well-circumscribed intramural yellowish white tumor (case 1)

Case 2: Grossly, the uterus contained a well circumscribed intramural tumour measuring 3 x 3 cm, which on cross-section showed

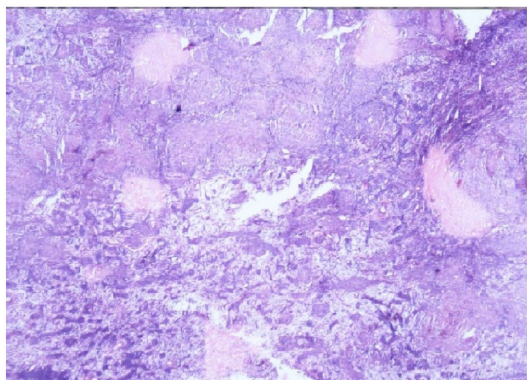
homogenous yellowish white soft to firm areas.

Microscopic Description

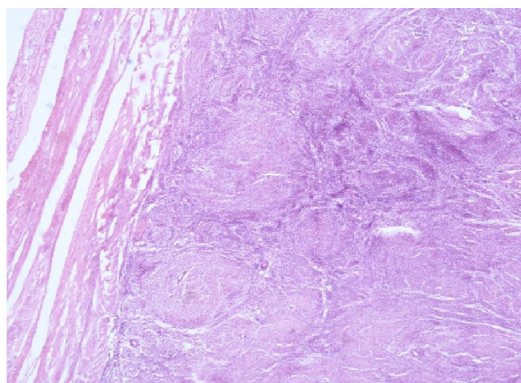
For light microscopy, conventional hematoxylin and eosin (H andE) stained slides were examined. Histopathological examination of the uterine tumour showed a well- circumscribed tumour having a typical nodular appearance. In the centre were present light staining aggregates of spindle cells with bland nuclei and scant to moderate cytoplasm with indistinct cytoplasmic borders arranged concentrically around small blood vessels resembling spiral arterioles. Surrounding these cells, were present 'small darkly staining cells' resembling endometrial stroma. Foci of hyalinization and scattered collection of foam cells were also noted [Table/Fig 2] [Table/Fig 3]. The tumour had a well delineated margin and did not show infiltration into the adjacent myometrium [Table/Fig 4] (Fig. 4). Reticulin stain demonstrated reticulin fibers around individual endometrial stromal cells.



(Table/Fig 2) Photomicrograph showing small uniform cells with oval nuclei and scant cytoplasm arranged concentrically around arterioles, surrounding these are present small darkly staining cells of endometrial stroma. (H&E, 10X)



(Table/Fig 3) Photomicrograph showing central area of hyalinization (starburst pattern), which in turn merge with immature bundles of smooth muscle. Note the scattered collection of foam cells. (H&E, 10X)



(Table/Fig 4) Photomicrograph showing a well circumscribed tumor composed of smooth muscle and endometrial stroma abutting the surrounding myometrium. (H&E, 10X)

Discussion

The term stromomyoma was proposed to designate a peculiar uterine tumour with the ultra structural characteristic of both endometrial stromal and smooth muscle cells. Endometrial stromal tumours (ESTs) have been classified according to the type of margin as benign (endometrial stromal nodule), having pushing margins and malignant (endometrial stromal sarcoma), having infiltrating margins [4]. Endometrial stromal nodules (ESNs) appear grossly as solitary, sharply circumscribed masses of soft consistency, with the characteristic yellow to orange colour and tend to bulge above the surrounding myometrium. They do not invade veins, lymphatics or the myometrium. Microscopically, these tumours are composed of cells that closely resemble normal proliferative phase endometrial stromal cells, with uniform,

small darkly staining round or oval nuclei, finely granular chromatin, occasional mitosis and scant cytoplasm. The stromal nodules are highly vascular, with small arterioles distributed throughout them. Extensive hyalinization is a common feature in most of these tumours. The prognosis is excellent, with no recurrences [5].

Focal areas of smooth muscle differentiation are commonly observed in ESTs, but tumours with extensive areas of both smooth muscle and endometrial stromal differentiation are rare. A certain number of mesenchymal uterine tumours show features of both endometrial stromal and smooth muscle differentiation. To establish the diagnosis of mixed endometrial stromal tumour with smooth muscle differentiation, the smooth muscle component should occupy at least 30% of the neoplasm, as seen by hematoxylin and eosin staining [6]. The smooth muscle component characteristically shows nodules with central hyalinization (starburst pattern) as seen in our cases, which merge with disorganized short fascicles or long mature fascicles of the smooth muscle, a feature which is almost never encountered in conventional smooth-muscle tumours [7]. Behaviourally, these tumours seem to be closer to endometrial stromal than smooth muscle tumour and on the whole, very indolent. Hysterectomy is thus the appropriate therapy and the periphery of the tumour must be thoroughly evaluated to be certain that it is completely circumscribed and non-invasive.

A study of 15 cases of stromomyomas by Oliva et al [6] showed that the endometrial stromal component was mainly desmin negative, while the smooth muscle component was strongly desmin positive. Tavassoli and Norris[5] suggested restricting the diagnosis of combined smooth muscle-stromal neoplasm to those tumours, in which each component accounts for at least one third of the tumour on light microscopy.

The differential diagnosis of this benign neoplasm includes low-grade endometrial

stromal sarcoma (ESS) and highly cellular leiomyoma. Microscopically, the most important single criterion for the diagnosis of ESN is a non infiltrative border of the tumour. Focal irregularities in the form of lobulated or finger like projections into the adjacent myometrium that are not ≥ 3 mm. and are not >3 in number may be seen; which contrasts with the permeative invasion of the myometrium as well as the myometrial vessels seen in low-grade ESS [8]. From the prognostic point of view, it is extremely important to distinguish between these two tumours, as ESNs do not relapse and low-grade ESSs have a low malignant potential characterized by late recurrences. Hence, extensive sampling of the tumour-myometrial interface should be done. This is to evaluate the degree of infiltration of the tumour into the myometrium and to detect vascular invasion, which is extremely important to distinguish the two. Highly cellular leiomyomas are composed of cells with spindle shaped nuclei with a fascicular growth pattern, thick muscular-walled blood vessels, cleft like spaces and show focal merging with the adjacent myometrium [6],[9]. In our cases, the tumour did not exhibit any of the above mentioned features.

Differentiating highly cellular leiomyoma from ESN is important in a curettage or myomectomy specimen, if a spindle cell cannot be classified into that of smooth muscle or stromal cell origin. In cases where the diagnosis is difficult to be established by light microscopy, immunohistochemical analysis may be helpful in arriving at the correct diagnosis, which is crucial, owing to the differences in treatment and prognosis [9]. A panel of antibodies including desmin, h-caldesmon, CD10 and inhibin may be very useful in such a scenario, since cellular leiomyomas express h-caldesmon in addition to desmin, while CD10 and inhibin expression is a feature of stromal cells [10]. Finally, oxytocin receptor, a neurohypophysial peptide which is associated with muscle contraction during labour, stains all conventional leiomyomas and highly cellular leiomyomas as well as

leiomyosarcomas, but is not expressed in ESTs [11]. However, this antibody is not used in daily practice at present. In the above mentioned cases, since the characteristic morphological features of the stromal cells were identified by light microscopy, expensive IHC studies were not performed. Further, the gross appearance and well defined non infiltrative microscopic tumour margins emphasized the benign nature of these lesions.

In summary, we have described an uncommon, benign mesenchymal uterine tumour, i.e. ESN with smooth muscle differentiation, which needs to be distinguished from tumours with similar morphological features i.e. low-grade ESS and highly cellular leiomyomas. These cases are being reported because of their rare occurrence and to create awareness amongst pathologists about these lesions regarding their differential diagnosis.

Acknowledgement

We are grateful of Dr. N C Mahajan, Head of department and department of pathology, M M Institute of medical science and research, Mullana for providing us support and facility.

References

- [1] Moinfar F, Kremser M L, Man Y G, et al. Allelic imbalances in endometrial stromal neoplasms : frequent genetic alterations in the nontumorous normal- appearing endometrial and myometrial tissues. *Gynecol Oncol* 2004; 95:662-71.
- [2] Hendrickson M R, Tavassoli FA, Kempson R L, et al. Mesenchymal tumors and related lesions. Pathology and genetics of tumors of the breast and female organs. Lyon: IARC Press, 2003:233-6.
- [3] Fekete P S, Ve llios F. The clinical and histologic spectrum of endometrial stromal neoplasm. A report of 41 cases. *Int J Gynecol Pathol* 1984; 3:198-212.
- [4] Norris H J, Taylor H B. Mesenchymal tumors of the uterus. A clinical and pathological study of 53 endometrial and stromal tumors. *Cancer* 1996; 19:755-766.
- [5] Tavassoli FA, Norris H J. Mesenchymal tumours of the uterus. A clinicopathological

- study of 60 endometrial stromal nodules. *Histopathology* 1981; 5:1-10.
- [6] Clement P B. The pathology of uterine smooth muscle tumours and mixed endometrial stromal- smooth muscle tumors: a selective review with emphasis on recent advances. *Int J Gynecol Pathol* 2000; 19:39-55.
- [7] Oliva E, Clement P B, Young R H et al. Mixed endometrial stromal and smooth muscle tumors of the uterus: a clinicopathological study of 15 cases. *Am J Surg Pathol* 1998; 22:997-1005.
- [8] Baker P, Oliva E. Endometrial stromal tumours of the uterus; a practical approach using conventional morphology and ancillary techniques. *J Clin Pathol.* 2007; 60:235-243.
- [9] Oliva E, Young R H, Clement P B, et al. Cellular benign mesenchymal tumors of the uterus. A comparative morphologic and immunohistochemical analysis of 33 highly cellular leiomyomas and six endometrial stromal nodules, two frequently confused tumors. *Am J Surg Pathol* 1995; 19:757-68.
- [10] Oliva E, Young RH, Amin MB, et al. An immunohistochemical analysis of endometrial stromal and smooth muscle tumors of the uterus: a study of 54 cases emphasizing the crucial importance of using a panel because of overlap in immunoreactivity for individual antibodies. *Am J Surg Pathol* 2002; 26:403-12.
- [11] Loddenkemper C, Mechsner S, Foss H D, et al. Use of oxytocin receptor expression in distinguishing between uterine smooth muscle tumors and endometrial stromal sarcoma. *Am J Surg Pathol* 2003; 27:1458-62.