

Hand Schuller Christian Disease: A Rare Case Report with Oral Manifestation

CH. LALITHA¹, M. MANJULA², K. SRIKANT³, STUTI GOYAL⁴, SHAHELA TANVEER⁵

ABSTRACT

Langerhan's Cell Histiocytosis (LCH) is disorders which include abnormalities that result from abnormal proliferation of langerhan's cells or their precursors. LCH is clinically classified into three types-eosinophilic granuloma, Hand Schuller Christian disease and Abt-Letterer-Siwe disease. It is usually manifested in childhood as well as in adulthood. The clinical manifestations are the result of the accumulation and infiltration of the langerhan cells in organs and tissues. Here is a rare case report of 6-year-old boy with extraoral manifestation of exophthalmic right eye and oral manifestation of mobility of teeth and with typical radiological findings. Basing on the clinical, radiological and histopathological examination the diagnosis of Hand Schuller Christian Disease was given.

Keywords: Histiocytosis, Hand-schuller-christian disease, Langerhan cell

CASE REPORT

A 6-year-old boy reported along with his mother, to the dental out-patient department of Government Dental College, Hyderabad, India with the chief complain of loosening of lower back teeth since two months. Patient's mother gives the history of gradual increase in mobility of the teeth with subsequent loss of left lower back tooth about 10 d ago. Mother gave no history of trauma, and no association of pain and swelling. Mother further revealed slow growth of the child when compared to his classmates. She also gave history of frequent urination. In the past medical history, patient's mother gives history of right ear infection about three years ago. No relevant dental history.

On general examination, patient appeared tensed but answered all the questions coherently, and was poorly built with reduced height (95 cm) and weight (12 kg) when compared to normal boy of same age (height = 116 cm; weight = 21 kg). On extraoral examination, the patient had brachycephalic skull, with frontal bossing, slight hypertelorism, exophthalmic left eye with pallor in relation to palpebral conjunctiva [Table/Fig-1].

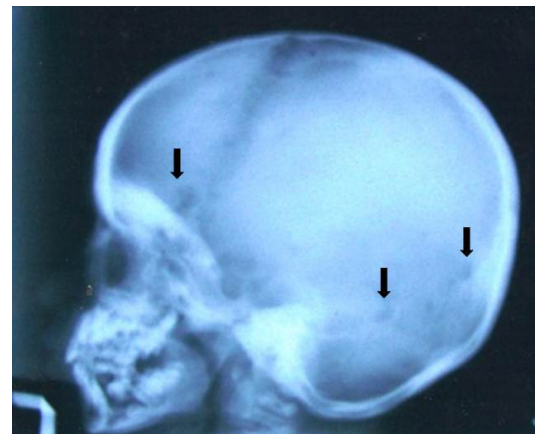
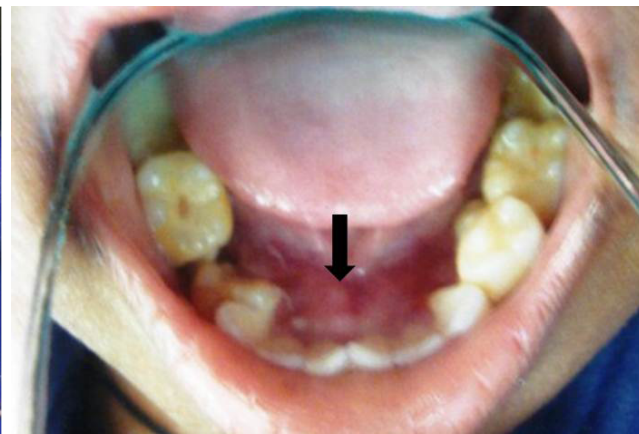
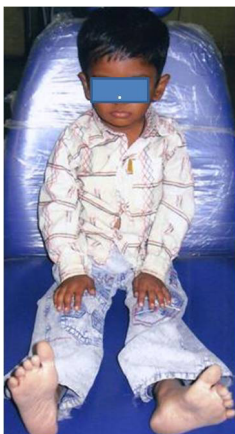Inspection of the specific lesion [Table/Fig-2] revealed, a solitary diffuse swelling in the lingual aspect of mandibular region extending from 73 region to 83 region crossing the midline, mesio-distally and from marginal gingival to the floor of the mouth, superior-inferiorly; measuring approximately 3x1 cm in size. The surface mucosa

appeared slightly reddish in colour. No visible pulsations with normal surrounding mucosa. On palpation, all inspector findings with respect to number, site and shape was confirmed. The swelling was tender to touch and with firm consistency. The swelling was neither reducible nor compressible and was fixed to the underlying structures. No palpable pulsations.

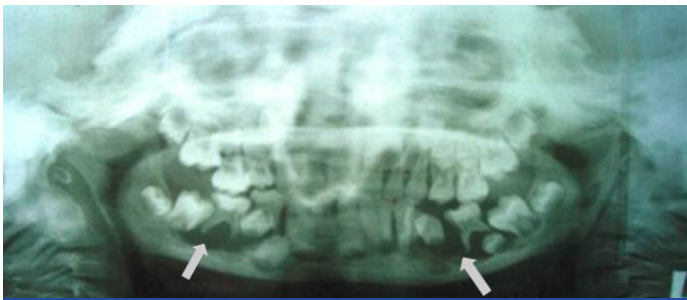
On intraoral examination, the gingiva was erythematous, oedematous and with loss of stippling in relation to 53, 54, 55, 63, 64, 65, 73, 74, 83, 84, 85. Gingival recession was present in relation to 75, 84, 85 exposing the entire roots. 74 were missing. Grade I mobility was present with 54, 55, 64, 65, 71, 72, 73, 75, 81, 82 83, 84, 85.

Based on the case history and clinical examination, a provisional diagnosis of Hand-schuller-christian disease was given. The differential diagnosis of Down's syndrome, cyclic neutropaenia, hypophosphatasia and acute leukaemia's was given, as the entire above are associated with young age, loosening of deciduous dentition and may be associated with stunted growth and hence were considered.

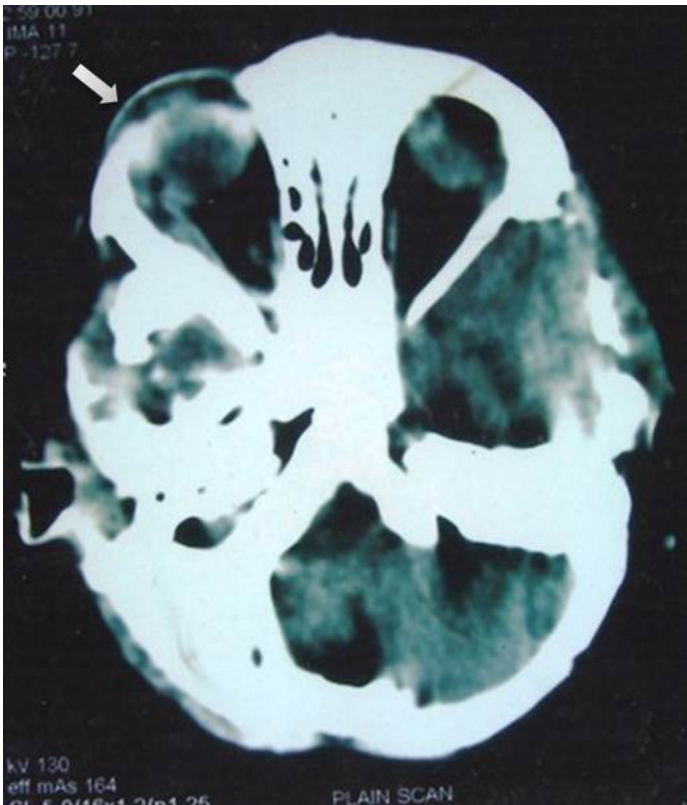
The peripheral blood smear revealed hypochromic microcytic anaemia. The complete urine examination revealed low specific gravity (1002) and daily urine output was about 3.2 litres per day. Lateral skull radiograph revealed multiple well defined punched out radiolucencies [Table/Fig-3], while the orthopantomograph revealed irregular bone destruction in relation to 73, 34, 75, 35, 84, 85 and



[Table/Fig-1]: Patient profile [Table/Fig-2]: Intraoral photograph of the mandibular swelling [Table/Fig-3]: Lateral skull radiograph showing punched out radiolucencies



[Table/Fig-4]: Orthopantomograph showing scooped out appearance of bone loss affecting posterior mandibular alveolus



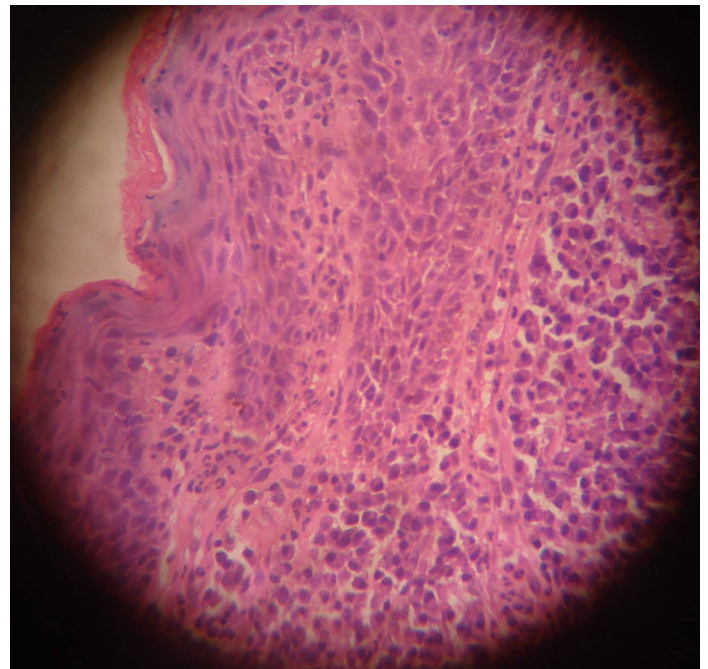
[Table/Fig-5]: Axial computed tomographic section at the level of eye showing exophthalmic right eye

46 region with floating teeth appearance in relation to 34, 35, 75, 45, 84 and 85 [Table/Fig-4]. The computed tomographic scan also revealed similar findings of multiple punched out radiolucencies of the skull, exophthalmic right eye [Table/Fig-5] and alveolar bony destruction of the mandible. The incisional biopsy performed showed, predominant proliferating histiocytes suggestive of langerhan's cell histiocytosis [Table/Fig-6].

Patient had failed to report for the further treatment and sadly two months after the final diagnosis, patient passed away.

DISCUSSION

Langerhans' cell histiocytosis (LCH), formerly called histiocytosis X, comprises a group of conditions that are characterized histologically by a monoclonal proliferation of large mononuclear cells accompanied by a prominent eosinophil infiltrate [1]. It was Lichtenstein, in 1953 who observed cytoplasmic bodies known as X bodies, within the histiocytes from the tissues of the patients suffering with this disease [2]. Bartnick et al., has mentioned that Nezelof has taken out X from the term histiocytosis X by identifying the Langerhans cell as the responsible cell [3]. Historically, histiocytosis X was classified into three distinct clinical forms: (1) single or multiple bone lesions with no visceral involvement (eosinophilic granuloma); (2) a chronic disseminated form (Hand-Schüller-Christian disease) that includes a classic triad of skull lesions, exophthalmos, and diabetes insipidus;



[Table/Fig-6]: Histopathological picture showing proliferating histiocytes

and (3) an acute disseminated form (Letterer-Siwe disease) that affects multiple organs and has a poor prognosis [1].

The aetiology of LCH remains unknown but there are some considerations that suggest that LCH is caused by immunologic dysregulations, with the resultant of accumulation of langerhan's cells. It is assumed to be a deficiency of T-suppressor lymphocytes with an increased CD4:CD8 ratio. Recently it has been shown that LCH represents a clonal proliferation of cells speculating that LCH may represent a neoplastic disorder [4]. LCH usually affects children between 1 and 15 yr old with a peak incidence between 5 and 10 y of age. Among children under the age of 10 y, yearly incidence is thought to be 1 in 2,00,000 [5]. A newly proposed LCH classification creates two categories: nonmalignant disorders, such as unifocal or multifocal eosinophilic granuloma, and malignant disorders, including Letterer-Siwe disease and variants of histiocytic lymphoma [6].

The first case described by Hand in 1893 had bronzed skin, hepatosplenomegaly and poor development, besides exophthalmos and geographic map skull. Vaze AM et al., has mentioned that Schuller and Christian had given attention to this triad [7]. Mathai NM et al., mentioned that Rowland (1929) has given the histological description of this lesion in different organs while Green and Farber (1942) demonstrated that eosinophilic granuloma of bone, Hand Schuller Christian disease and Litterer Siwe syndrome have the same basic pathology [8].

The classical triad of HSC disease – exophthalmos, diabetes insipidus, and calvarial lytic lesions – is seen only in one-third of patients [9]. Skull is the most common site involved and with 50% of cases reporting with diabetes insipidus [10]. HSC is primarily seen in infants and children and is rarely seen in adults. HSC has an incidence of 0.18/1,00,000 with approximately 30% cases occurring in adults [10]. Involvement of facial bones is frequently associated with soft tissue swelling, tenderness, and facial asymmetry. Otitis media is also common. Other bones that are frequently involved are femur, ribs, vertebrae, and pelvis. Sometimes, the skin exhibits papular or nodular lesions [11].

Oral manifestations are the earliest signs in around 5%-75% of patients. These include sore mouth, halitosis, gingivitis, unpleasant taste, loose teeth, and failure of extracted tooth sockets to heal. Loss of supporting bone mimics advanced periodontal disease [12].

Radiographic examination reveals that individual lesions, particularly in the skull, are sharply outlined. Skeletal lesions are usually seen

in membranous bones. Lesions in the long bones involve only the diploe. Epiphyseal involvement is unusual. The large serpiginous punched out calvarial lesions go by the picturesque name "geographic skull" [8]. Radiographically there is scooped out bone loss starting typically at the mid root region, commonly affecting the posterior mandibular alveolus [6]. Sometimes extensive alveolar involvement causes the teeth to appear as if they are "floating in air" [13].

Bone scintigraphy is of limited usefulness. CT may be useful to define the extent of the process. On MRI examination, T1-weighted images reveal a lesion isointense to adjacent tissue and T2-weighted images reveal high signal areas of marrow replacement [14].

Histologically, Hand-Schüller-Christian disease manifests four stages during its progression [11].

- A proliferative histiocytic phase, with collections of eosinophilic leukocytes scattered throughout the sheets of histiocytes
- A vascular granulomatous phase, with persistence of histiocytes and eosinophils; sometimes with aggregation of lipid-laden (cholesterol) macrophages
- A diffuse xanthomatous phase, with an abundance of 'foam cells'
- A fibrous or healing phase

Ultrastructurally, Langerhan cells contain rod-shaped cytoplasmic structures known as Birbeck granules, which differentiate Langerhan cells from other mononuclear phagocytes. Langerhan cells show immunoreactivity to CD-1a or CD-207, the latter marker being especially specific to Langerhan cells. In a few cases, lesional cells have shown immunoreactivity to S-100 protein and peanut agglutinin (PNA) [13]. Lab investigations often reveal anaemia, leukopenia, and thrombocytopenia. The serum cholesterol level is nearly normal, though tissue cholesterol content may be elevated remarkably [11].

The course of this disease is entirely variable; in 35% of patients, it gets burned out while in, 15% of patients, it is fatal [8]. The oral of oral clinician is limited to the treatment of the oral manifestation of this group of diseases. The systemic treatment should be carried out by a specialist. Localized oral lesions may be treated by surgical curettage or excision. Intralesional corticosteroids injection or a low dose regimen of systemic oral corticosteroids (e.g.- prednisolone 20-30mg/day for 2-4 wk and then followed by tapering of the dose). Radiation is an alternative procedure for localized bone lesions.

Multisystemic disease needs systemic chemotherapy. The most common agents used in different combination regimens and several cycles are corticosteroids, vinblastine, etoposide, cytarabine, 6-mercapto purine, methotrexate, 2-chlorodeoxyadenosine, cyclosporine, thalidomide and others [15].

Other therapies include supervoltage therapy, supportive therapy, control of diabetic insipidus and surgery in specific indications [7].

CONCLUSION

This case report highlights one of rare diseases afflicting children with the typical findings of Hand Schuller Christian disease. Prompt diagnosis and treatment of the disease will improve the life expectancy.

REFERENCES

- [1] Greenberg MS, Glick M, Ship JA. *Burket's Oral Medicine*. 11th ed. Hamilton: BC Decker; 2008:144-45.
- [2] Jayachandran S, Balaji N. Langerhan cell histiocytosis. *World Journal of Dentistry*. 2011;2(1):57-62.
- [3] Bartnick A, Friedrich RE, Roeser K, Schmelzle R. Oral langerhans cell histiocytosis. *Journal of Cranio Maxillofacial Surgery*. 2002;30:91-96.
- [4] Putters T, de Visscher JGAM, van Veen A, Spijkervet FKL. Intralesional infiltration of corticosteroids in the treatment of localized Langerhans' cell histiocytosis of the mandible: Report of known cases and three new cases. *Int J Oral Maxillofac Surg*. 2005;34:571-75.
- [5] Alajbeg I, Vucicevic Boras V, Femenic R, Cekic-Arambasin A, Anicic M, Kelecić J, et al. Unrecognized oral manifestations of Langerhans cell histiocytosis which progressed to systemic disease. *Oral Oncology Extra*. 2006;42(1):10-13.
- [6] Pharoah M, White SC, eds. *Oral radiology : principles and interpretation*. 6th edn. St. Louis, Mo.: Mosby, 2009.
- [7] Vaze AM, Koppikar MG, Patel MS, Phadke PP, Nadkarni MM, Bapat RD. Hand Schuller Christian disease. *J Postgrad Med*. 1980;26:138.
- [8] Mathai NM, Nair NS. *Indian J Pediatr*. 1964;31:246.
- [9] Cugati G, Singh M, Pande A, Ramamurthi R, Vasudevan MC. Hand Schuller Christian Disease. *Indian J Med Paediatr Oncol*. 2011;32(3):183-84.
- [10] Mener DJ, Moskowitz HS, Stewart CM. Temporal Bone Involvement in Hand-Schuller-Christian Disease. *Otol Neurotol*. 2014 Mar 6. [Epub ahead of print].
- [11] Shafer WG, Hine MK, Levy BM. Diseases of bone and joints. In: Rajendran R, Shivapathasundaram B, editors. *Shafer's textbook of oral pathology*. 6th ed. Noida: Elsevier; 2009. p. 744-5.
- [12] Bhargava D, Bhargava K, Hazarey V, Ganvir SM. Hand-Schüller-Christian disease. *Indian J Dent Res*. 2012;23:830-32.
- [13] Neville BW, Damm DD, Allen CM, Bouquot JE. Langerhans cell histiocytosis. *Textbook of oral and maxillofacial pathology*. 3rd ed. New Delhi: Elsevier; 2009. pp. 590-92.
- [14] Kransdorf MJ, Jelinek JS, Moser RP Jr. Imaging of soft tissue tumours. *Radiol Clin North Am*. 1993;31(2):359-72.
- [15] Laskaris G. *Treatment of Oral Disease: A Concise Textbook*. Stuttgart, Germany: Thieme; 2006:93-94.

PARTICULARS OF CONTRIBUTORS:

1. Senior Lecturer, Department of Oral Medicine and Radiology, Sri Sai College of Dental Surgery, Vikarabad, Telanagana, India, India.
2. Professor, Department of Oral Medicine and Radiology, Gandhi Hospitals, Hyderabad, India.
3. Senior Lecturer, Department of Oral Medicine and Radiology, Sri Sai College of Dental Surgery, Vikarabad, India.
4. Senior Lecturer, Department of Oral Medicine and Radiology, Sri Sai College of Dental Surgery, Vikarabad, India.
5. Senior Lecturer, Department of Oral Pathology, Sri Sai College of Dental Surgery, Vikarabad, India.

NAME, ADDRESS, E-MAIL ID OF THE CORRESPONDING AUTHOR:

Dr. Ch. Lalitha,
Senior Lecturer, Sri Sai College of Dental Surgery, Vikarabad, Telanagana, India.
E-mail: dr.lalithaomr@gmail.com

Date of Submission: **Aug 27, 2014**

Date of Peer Review: **Oct 06, 2014**

Date of Acceptance: **Nov 09, 2014**

Date of Publishing: **Jan 01, 2015**

FINANCIAL OR OTHER COMPETING INTERESTS: None.