

# Haemangioma, Thrombocytopenia and Coagulopathy- Kasabach Merritt Syndrome: An Appraisal for Anaesthesiologists

BABITA LAHKAR<sup>1</sup>, PRIYAM SAIKIA<sup>2</sup>, BIKASH BHASKAR BORA<sup>3</sup>

**Keywords:** Coagulopathy, Haemangioma, Kasabach-merritt syndrome, Thrombocytopenia

Sir,

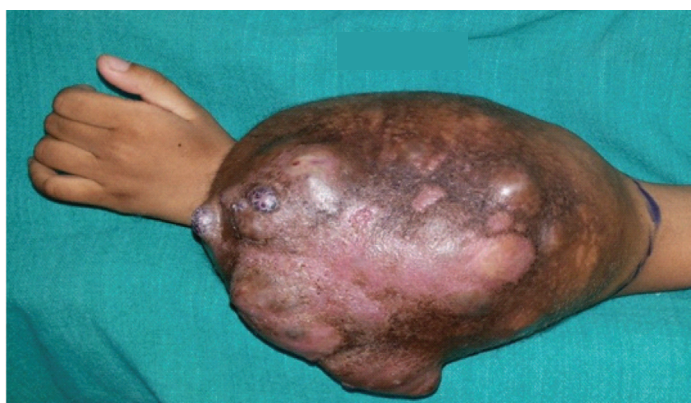Haemangioma is a common type of vascular tumour in paediatric age group [1]. Most of them are benign and non-life threatening [1]. Kasabach Merritt syndrome (KMS) is a combination of giant haemangioma, thrombocytopenia and consumptive coagulopathy [1-5]. It presents with diverse clinical presentation and may be a part of other recognized syndrome [1,2]. KMS is a well-recognized but rare clinical entity that may be life threatening [1- 4] and bears considerable anesthetic implications [3-5].

Here, we would like to report a case of an 11-year-old boy, after obtaining a written permission from parents, who came to us for preoperative evaluation with a haemangioma (15.7×13.3 cm in maximum dimension) involving the left forearm [Table/Fig-1]. It began to appear as a small lesion without causing any associated problem at the age of three years. Though the patient have attended various medical services, he was not provided with any conclusive diagnosis nor there any improvement in his symptomology. During the last eight years it enlarged many folds with destruction of radius, erosion & remodeling of ulna [Table/Fig-2]. As there was profound bonny destruction, an above elbow amputation was planned by his surgical team. His bed side physical examination did not reveal any other significant abnormality. All preoperative lab parameters were normal except for a platelet count of 72,000/ $\mu$ L. A subsequent coagulation profile revealed a prothombin time prolonged by five seconds and international normalized ratio (INR) of 1.52. Considering the possibility of KMS, he was referred to haematology service. He was diagnosed with KMS by the haematology service and no preoperative transfusion was advised. The possibility of massive blood loss and institution of massive blood transfusion protocol was discussed and planned accordingly. He was provided general anaesthesia with endotracheal intubation and mechanical ventilation during the surgery. Total anaesthesia time was 90 min and trachea was extubated at the end of surgery. We did not encounter any reduction of platelet count or deterioration of coagulation profile during the intraoperative period and there was no need of

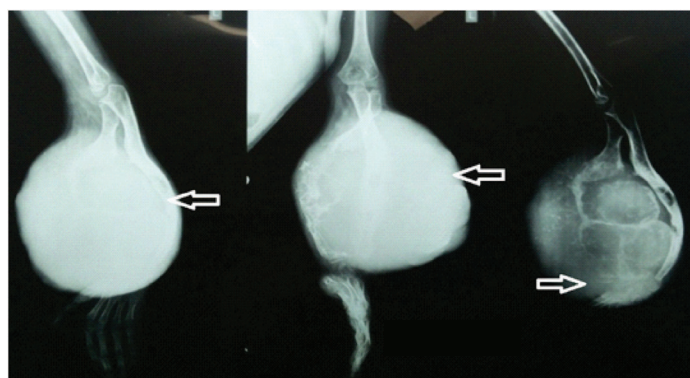
intraoperative blood transfusion. On the 1<sup>st</sup> postoperative day his platelet count raised to 1, 20,000 / $\mu$ L and INR normalized to 1.3. Histology of the resected specimen revealed kaposiform haemangio endothelioma, which is the commonest histological type associated with KMS [1].

A practice derived consensus statement discussing diagnostic workup, surgical and non-surgical treatment modalities of KMS has been published very recently [2]. Apart from the problems associated with anatomic locations of the tumour [1,3] and haematological abnormalities [1-5], cardiac derangement from high-volume arterio-venous shunting is also a concern [2-4]. The anaesthetic implications of pharmacological measures used during the treatment of KMS should also be addressed with assiduity [1-3]. Anaesthesia and surgery may possibly trigger disseminated intravascular coagulation and induce severe bleeding [3]. Although KMS is associated with mortality and morbidity [1,2], case reports of successful perioperative outcome is also available in literature [3,5]. Recently, survival benefit has been documented in patients with traumatic hemorrhage that were managed with hemostatic therapy guided by viscoelastic point-of-care coagulation devices (thromboelastography) [6]. Thromboelastography is also increasingly being used in hemorrhage of non-traumatic origin [7]. In a patient with KMS, FloTrac/Vigileo system was used successfully to guide appropriate resuscitative measures that ensured stable perioperative hemodynamics [5]. Thus, the authors believe that the impact of use of viscoelastic point-of-care coagulation and noninvasive cardiac output monitoring devices on mortality and morbidity of patients with KMS should be evaluated.

Haemangioma is a common condition in pediatric age group [1,2], thus anaesthesiologists are expected to encounter patients with hemangioma frequently. KMS is a rare clinical manifestation in patients with haemangioma, moreover its clinical features are diverse [1-7]. Although this particular case did not pose much challenge in the perioperative period, this discussion should serve to remind anesthesiologists of the possible complications and management issues that may be encountered with KMS.



**[Table/Fig-1]:** Haemangioma involving the left forearm



**[Table/Fig-2]:** X-ray of the left forearm showing a large expansile soft tissue density (arrow mark) lesion in the mid and distal forearm causing profound bone erosion and deformity, especially involving the radius and also the ulna

## REFERENCES

- [1] Hall GW. Kasabach-Merritt syndrome: pathogenesis and management. *Br J Haematol.* 2001;112(4):851-62.
- [2] Drolet BA, Trenor CC 3<sup>rd</sup>, Brandão LR, Chiu YE, Chun RH, Dasgupta R, et al. Consensus-derived practice standards plan for complicated Kaposiform hemangioendothelioma. *J Pediatr.* 2013;163(1):285-91.
- [3] Kumar S, Taneja B, Saxena KN, Kalra N. Anaesthetic management of a neonate with Kasabach-Merritt syndrome. *Indian J Anaesth.* 2013;57(3):292-94.
- [4] Currie BG, Schell D, Bowring AC. Giant hemangioma of the arm associated with cardiac failure and the Kasabach-Merritt syndrome in a neonate. *Journal of Pediatric Surgery.* 1991;26(6):734-37.
- [5] Wakabayashi S, Yamaguchi K, Kugimiya T, Inada E. Successful anesthetic management for resection of a giant hepatic hemangioma with Kasabach-Merritt syndrome using FloTrac system. *Masui.* 2011;60(11):1326-30.
- [6] Schöchl H, Nienaber U, Hofer G, Voelckel W, Jambor C, Scharbert G, et al. Goal-directed coagulation management of major trauma patients using thromboelastometry (ROTEM)-guided administration of fibrinogen concentrate and prothrombin complex concentrate. *Crit Care.* 2010;14(2):R55.
- [7] McDaniel LM, Etchill EW, Raval JS, Neal MD. State of the art: massive transfusion. *Transfus Med.* 2014;24(3):138-44.

### PARTICULARS OF CONTRIBUTORS:

1. Assistant Professor, Department of Anaesthesiology and Critical Care, Gauhati Medical College and Hospital, Guwahati, Assam, India.
2. Assistant Professor, Department of Anaesthesiology and Critical Care, Gauhati Medical College and Hospital, Guwahati, Assam, India.
3. Post-Graduate Trainee, Department of Anaesthesiology and Critical Care, Gauhati Medical College and Hospital, Guwahati, Assam, India.

### NAME, ADDRESS, E-MAIL ID OF THE CORRESPONDING AUTHOR:

Dr. Priyam Saikia,  
Assistant Professor, Department of Anaesthesiology and Critical Care,  
Gauhati Medical College and Hospital, Guwahati, Assam-781032, India.  
E-mail : saikia.priyam80@gmail.com

**FINANCIAL OR OTHER COMPETING INTERESTS:** None.

Date of Submission: **Jun 07, 2014**

Date of Peer Review: **Jul 23, 2014**

Date of Acceptance: **Aug 29, 2014**

Date of Publishing: **Jan 01, 2015**