

Misdiagnosis of Abdominal Pain in Pregnancy: Acute Pancreatitis

P. PALLAVEE¹, SUNITA SAMAL², SHWETA GUPTA³, JASMINA BEGUM⁴, SEETESH GHOSE⁵

ABSTRACT

We report a case of acute pancreatitis in a pregnant woman who presented to our emergency department with complaints of severe abdominal pain, was misdiagnosed as scar dehiscence and underwent emergency repeat caesarean section at 33 wks for fetal distress. The preterm baby developed severe respiratory distress and succumbed on the second postnatal day. Persistent severe pain in the postoperative period in the mother prompted further evaluation which led to a diagnosis of acute pancreatitis. Conservative and supportive management was instituted leading to an eventual favourable maternal outcome.

Keywords: Acute pancreatitis, Management, Pregnancy

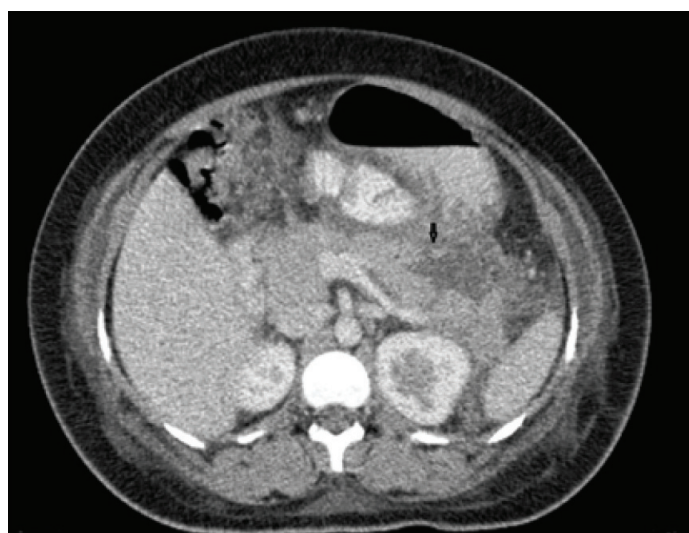
CASE REPORT

A 23-year-old second gravida with one living child presented to the emergency department at 33 wks of gestation with the complaint of severe abdominal pain of acute onset, not associated with nausea or vomiting, no history of fever, leaking or bleeding per vaginum and normal bowel and bladder functions. She had undergone emergency caesarean section in her first pregnancy for second stage arrest of descent and the inter-pregnancy interval was less than six months. At the time of admission patient was conscious, well-oriented, afebrile, diaphoretic, tachycardic with a pulse rate of 120/min and blood pressure 110/80 mm of Hg. Abdominal examination revealed a mildly contracting gravid uterus with a single live fetus in cephalic presentation, corresponding to a gestational age of 32 wks of gestation. There was generalised abdominal tenderness with no guarding or rigidity and bowel sounds were heard. Admission cardiotocograph (CTG) showed persistent fetal bradycardia for which emergency caesarean section was done. The neonate developed respiratory distress requiring ventilator support and expired on 2nd postnatal day due to hyaline membrane disease inspite of surfactant therapy. Patient continued to have severe abdominal pain in the postoperative period with persistent tachycardia and abdominal distension. Trans-abdominal ultrasound was done which revealed multiple gallstones with peri-pancreatic fluid collection and ascites. Hematological investigations showed leucocytosis of 15,800/cu.mm, elevated serum amylase (637U/L) and serum lipase (1630U/L) supporting a diagnosis of acute pancreatitis in our patient. Patient developed respiratory distress and was put under intensive care and managed with intravenous fluids, higher order antibiotics and bowel rest. CT scan done on postoperative day 7 showed partial necrosis of the tail of pancreas with splenic vein thrombosis [Table/Fig-1]. Patient recovered well and was discharged from the hospital on postoperative day 14 with due emphasis on follow-up.

DISCUSSION

The cause of an acute abdomen in a pregnant woman [1] may represent a significant diagnostic challenge. Emergency hospital admission may commonly be required, unless a benign cause has been definitely established in the absence of either maternal or fetal distress. During early gestation, ectopic pregnancy needs to be ruled out prior to considering other aetiologies of acute abdomen. Assessment of an acute abdomen is a lot more complicated during

pregnancy, since the gravid uterus may mask most of the tell-tale signs. Acute appendicitis is the commonest cause of an abdominal pain in a pregnant woman not in labour. Urinary tract infections (UTI) or stones and cholecystitis are also fairly common [Table/Fig-2] [1-3] lists the common aetiologies of acute abdomen in pregnancy. Assessment of the pregnant woman with an acute abdomen needs to begin with eliciting a detailed history focusing on the pain, other abdominal symptoms, fetal movements, an obstetric history, as well as past medical and gynaecological history, medication, allergies and last meal. Examination of such a patient should include a general examination, abdominal and obstetric examination and due consideration being given to whether a pelvic and/or rectal examination is indicated. If placenta previa is considered a probable diagnosis, a pelvic examination should never be attempted, since it could precipitate torrential bleeding. Investigations should be directed at the presumed cause and might include bedside investigations like urine dipstick, urine pregnancy test, bedside glucose monitoring and fetal CTG monitoring, as also laboratory investigations such as blood tests, urine tests, electrocardiogram and ultrasonography, as indicated. Further, if indicated, investigations like chest X-ray, swabs and/or blood cultures, MRI, CT scans, diagnostic laparoscopy or laparotomy may be required. While subsequent management would



[Table/Fig-1]: CT scan abdomen showing partial necrosis of the tail of pancreas (Black arrow)

Obstetric causes	<ul style="list-style-type: none"> Labour pain - premature labour or term. Pre-eclampsia or HELLP syndrome - epigastric or right upper quadrant pain. Placental abruption Uterine rupture Chorioamnionitis Acute fatty liver of pregnancy Acute polyhydramnios Severe uterine torsion- rare; may be due to structural abnormalities in the pelvis.
Gynecological causes	<ul style="list-style-type: none"> Ectopic pregnancy Miscarriage ± septic abortion. Torsion of the ovary or Fallopian tube. Ovarian cysts - torsion, haemorrhage or rupture. Fibroids - red degeneration or torsion. Ovarian hyperstimulation syndrome Salpingitis. Round ligament pain.
'Surgical' causes	<ul style="list-style-type: none"> Acute appendicitis. Cholecystitis and gallstones. Urinary tract - renal calculi, urinary tract obstruction (including acute urinary retention due to retroverted gravid uterus). Intestinal obstruction - most often due to adhesions. Peritonitis from any cause. Abdominal trauma, including domestic violence. Mesenteric adenitis. Meckel's diverticulitis. Peptic ulcer. Inflammatory bowel disease. Abdominal wall - hernias, musculoskeletal pain, rupture of rectus abdominis muscle. Acute pancreatitis - rare and usually due to gallstones. Mesenteric venous thrombosis (rare) - most reported cases have occurred where dehydration complicated an underlying hypercoagulable state. Rupture of visceral artery aneurysm (rare).
'Medical' causes	<ul style="list-style-type: none"> UTI ± pyelonephritis. Constipation. Diabetic ketoacidosis. Sickle-cell anaemia crisis. Lower lobe pneumonia. Venous thromboembolism - deep vein thrombosis or pulmonary embolus may cause lower or upper abdominal pain respectively. Myocardial infarction. Gastroenteritis. Irritable bowel syndrome.
Musculoskeletal causes	<ul style="list-style-type: none"> Round ligament pain - low abdominal or groin pain due to the uterus pulling on the round ligament. General aches - due to uterine enlargement. Rectus muscle haematoma - due to rupture of inferior epigastric vessels in late pregnancy Pelvic girdle pain

[Table/Fig-2]: Common causes of abdominal pain during pregnancy

be dictated by the diagnosis, certain aspects of management would be common for most situations. Rhesus-negative pregnant women should receive anti-D immunoglobulin if indicated. Multi-disciplinary management involving an obstetrician, a surgeon and/or physician would ensure positive outcomes. Indications for emergent surgical

intervention remain the same as for non-pregnant patients. However, if elective surgery is indicated in a pregnant lady, the second trimester would be appropriate for such interventions. Laparoscopy is being increasingly used for diagnosis and management. The incidence of acute pancreatitis during pregnancy has been reported variably in different regions of the world due to variations in the incidence of gall stones, which is one of the commonest causes [4]. Most commonly cited incidence in the world literature is 1 in 1000 to 1 in 12,000 given by Ramin et al., [5]. In our patient, persistent abdominal pain in immediate postoperative period prompted us to re-look for the cause rather than ascribing the pain to surgery, which subsequently led us to an early diagnosis of pancreatitis and appropriate management. The prevalence of this condition varies across the three trimesters of pregnancy, being more common in the second and third trimesters [5,6]. Ramin reported that 19% of acute pancreatitis occurs in the first, 26% in the second, 53% in the third and 2% in the postpartum period [5]. Our patient presented at 33 weeks of gestation with a history of previous caesarean section, a short inter-pregnancy interval of six months, generalised abdominal tenderness and fetal bradycardia, leading to a doubt of scar integrity and emergency repeat caesarean section. In our case, abdominal ultrasound revealed gallstones as well as bile sludge which may have caused the pancreatic attack. Though gall bladder disease can precede the pancreatic inflammation, our patient was completely asymptomatic till the day of admission.

CONCLUSION

Acute pancreatitis complicating pregnancy is a rare but severe condition. There is no consensus in the literature regarding the treatment of acute pancreatitis in the pregnant woman. Although such management has traditionally been conservative, the treatment of biliary lithiasis depends on the symptoms.

A multidisciplinary approach, involving the gastroenterology, intensive care and obstetric teams, appears to be vital in taking appropriate decisions with regard to management of acute pancreatitis during pregnancy. With alterations in food habits and lifestyle, an obstetrician encountering acute pancreatitis during pregnancy will not be uncommon. Imaging the pancreas routinely, during third trimester ultrasound scans, more so in patients complaining of upper abdominal pain should be part of standard obstetric management.

REFERENCES

- [1] Taylor D, Perry RL. Acute abdomen and pregnancy. <http://emedicine.medscape.com>; Updated Mar 28, 2014.
- [2] Sharp HT. The acute abdomen during pregnancy. *Clin Obstet Gynecol.* 2002;45:405-13.
- [3] Stone K. Acute abdominal emergencies associated with pregnancy. *Clin Obstet Gynecol.* 2002;45:553-61.
- [4] Pitchumoni CS, Yegneswaran B. Acute pancreatitis in pregnancy. *World J Gastroenterol.* 2009;15:5641-46.
- [5] Ramin KD, Ramin SM, Richey SD, Cunningham FG. Acute pancreatitis in pregnancy. *Am J Obstet Gynecol.* 1995;173:187-91.
- [6] Hernandez A, Petrov MS, Brooks DC, Banks PA, Ashley SW, Tavakkolizadeh A. Acute pancreatitis and pregnancy: a 10-year single center experience. *J Gastrointest Surg.* 2007;11:1623-27.

PARTICULARS OF CONTRIBUTORS:

1. Associate Professor, Department of Obstetrics & Gynaecology, Mahatma Gandhi Medical College, Puducherry, India.
2. Associate Professor, Department of Obstetrics & Gynaecology, Mahatma Gandhi Medical College, Puducherry, India.
3. Assistant Professor, Department of Obstetrics & Gynaecology, Mahatma Gandhi Medical College, Puducherry, India.
4. Assistant Professor, Department of Obstetrics & Gynaecology, Mahatma Gandhi Medical College, Puducherry, India.
5. Professor and Head, Department of Obstetrics & Gynaecology, Mahatma Gandhi Medical College, Puducherry, India.

NAME, ADDRESS, E-MAIL ID OF THE CORRESPONDING AUTHOR:

Dr. P. Pallavee,
Qr. No. D(II) 18, JIPMER Campus, Dhanvantari Nagar, Puducherry – 605006, India.
E-mail : ppallavee@rediffmail.com

FINANCIAL OR OTHER COMPETING INTERESTS: None.

Date of Submission: **Feb 19, 2014**
Date of Peer Review: **Jun 03, 2014**
Date of Acceptance: **Jun 17, 2014**
Date of Publishing: **Jan 01, 2015**