

# Non Syndromic Familial Bilateral Deciduous Taurodontism – A First Case Report

ANTARMAYEE PANIGRAHI<sup>1</sup>, RAJAT G. PANIGRAHI<sup>2</sup>, SRILATHA K. T.<sup>3</sup>, RUCHI BHUYAN<sup>4</sup>, SANAT K. BHUYAN<sup>5</sup>

## ABSTRACT

Taurodontism is anatomical and morphological alteration in the shape of the tooth. In taurodontism the crowns appear larger and the roots shorter compared to the normal anatomy of the respective tooth. The incidence of taurodontism in deciduous is very low and is also not very common in permanent dentition. The endodontic treatment protocol of taurodontic tooth is challenging. Taurodontic tooth requires a very cautious approach in identifying the root canal orientation and presence of any extra or lateral canals.

**Keywords:** Deciduous teeth, Pulpectomy, Taurodontism

## CASE REPORT

A 4-year-old male child escorted by his mother, elder brother and sister had come to the clinic with the chief complaint of painful decayed teeth in right and left lower jaw since two weeks. Pain was intermittent, mild and non-radiating in nature.

His medical history was non-contributory.

General and intra-oral soft tissue examination revealed normal appearance. Intraoral hard tissue examination revealed the presence of following teeth.

55 54 53 52 51 61 62 63 64 65

85 84 83 82 81 71 72 73 74 75

On clinical examination there was deep carious lesion in relation to 74 and 84 and grossly destroyed 64 and 85. Intraoral periapical radiograph of 74 and 84 revealed radiolucency involving pulp and enlarged pulp chamber with short roots suggestive of taurodontism [Table/Fig-1,2]. The teeth were subjected for clinical tests and diagnosis of chronic irreversible pulpitis was made in relation to 64, 74, 84, and 85. The teeth 74 and 84 were treated by multivisit pulpectomy procedure. Obturation was done with vitapex followed by semi permanent restoration with stainless steel crowns [Table/Fig-3].

Extraction followed by space maintainer was planned for 64 and 85 [Table/Fig-4, 5]. On further examination of the patient's sibling's similar characteristic radiographic finding of taurodontism was discovered. IOPA of 84, 85 region of brother [Table/Fig-6] and IOPA of 84 region [Table/Fig-7] of sister exhibited taurodontic characteristic. Suspecting this the mother was also subjected to radiographic procedure who to our great surprise exhibited taurodontic appearance of a previously endodontically treated 36 [Table/Fig-8].

## DISCUSSION

Taurodontism is an enlargement of the body and the pulp chamber of a multirrooted tooth with apical displacement of the pulpal floor and bifurcation of the roots [1]. This anomaly was first reported in the remnants of prehistoric hominids [2].

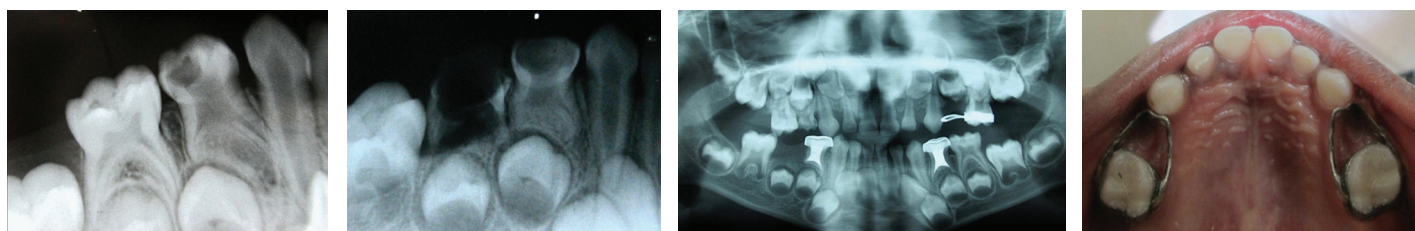
However the term "taurodontism" was first used by to describe the teeth of prehistoric people. He coined this term from the Latin Word tauro (for bull) and Greek term dont (for tooth) because of the morphological resemblance of affected tooth to the tooth of ungulates, especially bulls [3].

In 1928 Shaw classified sub-types of this condition as hypotaurodontism, mesotaurodontism and hypertaurodontism based on the relative displacement of the floor of the pulp chamber [4].

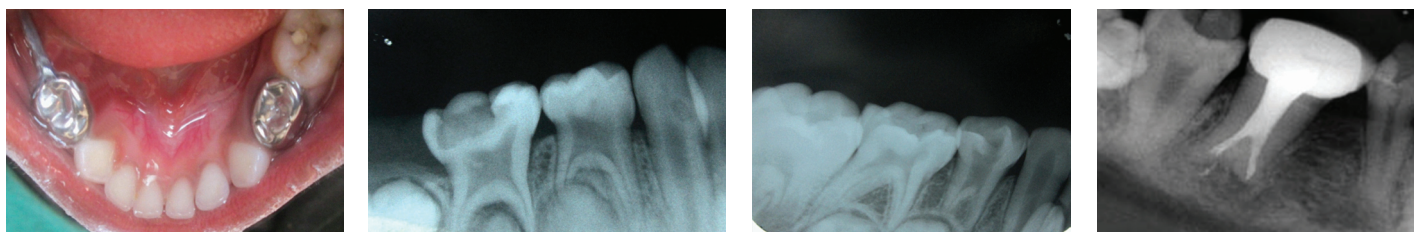
In 1978 Shifman and Chanannel proposed the following criteria for determining the presence or absence of taurodontism. Taurodontism is present, if the distance (a) from the lowest point (A) at the occlusal end of the pulp chamber to the highest point at the apical end of the chamber (B), divided by the distance (b) from the occlusal end of the pulp chamber to the apex (C) is 0.2mm or greater i.e.  $\{A/b=0.2mm\}$  and if the distance from the highest point of the pulp chamber floor to cemento-enamel junction is more than 2.5 mm [5].

Permanent mandibular molars are commonly affected. It has a very low incidence and very few cases are reported in literature in deciduous dentition. Lysell reported a case in the deciduous second molars of a swedish boy. The first molars did not show the trait [6].

To the best of my knowledge it is apparently the first reported case in bilateral familial taurodontism of deciduous first molar teeth along with the mother, elder brother and sister exhibiting similar characteristics of Taurodontism in different tooth.



**Table/Fig-1:** Preoperative IOPA shows large pulp chamber suggesting taurodontism of 74 **Table/Fig-2:** Preoperative IOPA shows large pulp chamber suggesting taurodontism of 84 **Table/Fig-3:** Post treatment OPG of the taurodontism patient **Table/Fig-4:** Intraoral picture showing band and loop space maintainer in 55 and 65



**[Table/Fig-5]:** Intraoral picture showing stainless steel crown in 74 and distal shoe space maintainer in 84, **[Table/Fig-6]:** IOPA shows large pulp chamber suggesting taurodontism of 84, 85 of the patient's 5 year old brother, **[Table/Fig-7]:** IOPA shows large pulp chamber suggesting taurodontism of 84 of the patient's 7 year old sister, **[Table/Fig-8]:** IOPA shows endodontically treated 36 with large pulp chamber of the patient's mother suggestive of taurodontism

Diagnosis is usually made by routine radiographs. Many explanations for the etiopathogenesis of taurodontism have been put forward from time to time. These include: a) an unusual developmental delay; b) delay in calcification of the pulp chamber floor; c) odontoblastic deficiency (d) alteration in Hertwig's epithelial root sheath, with an apparent failure of the epithelial diaphragm to invaginate at the normal horizontal level and e) delayed or incomplete union of the horizontal flaps of the epithelial diaphragm [7].

Usually, it is an isolated anomaly, but can occur in several well-known syndromes such as Down's syndrome, Klinefelter's syndrome, tricho-dento-osseous syndrome, Mohr syndrome, Wolf-Hirschhorn syndrome and Lowe syndrome [7-9].

In the present case systemic diseases or syndromic involvement were absent. However, his mother showed taurodontism of 36, his 9-year-old sister showed taurodontism of 84 and his 5-year-old brother showed taurodontism of 84 and 85, hence suggestive of familial tendency.

Clinically, they appear normal and are diagnosed subjectively from the radiographic appearance. In the present case, it was bilateral hypertaurodontism [5,10,11].

Most important aspect of this rare entity is in view of difficulties encountered in performing endodontic treatment as it shows wide variation in the size and shape of the pulp chamber, varying degrees of obliteration and canal configuration, apically positioned canal orifices and the potential for additional root canal system. Increase in hemorrhage during access cavity preparation may be mistaken for perforation. Since the roots are short and pulpal floor is placed apically, care should be taken to prevent perforation [9,12,13].

Conventional obturating material like Zinc oxide eugenol in bulk may take longer time to resorb which may delay natural exfoliation of the tooth. So, in the present case, Vitapex was used for obturation owing to its resorbing and antibacterial properties. This does not prevent the path of eruption of successor [14].

## CONCLUSION

Although taurodontism is seen as a morphological alteration in the modern humans, but it is widely assumed as a very common finding in the Neanderthal beings. It is imperative for the clinician to be aware of the complications in the treatment procedure. Taurodontism presents difficulty during the whole process of root canal treatment. Cautious approach should be maintained during the instrument selection and the final obturation process.

## REFERENCES

- [1] Witkop CJ. Manifestations of genetic diseases in Human Pulp. *Oral Surgery*. 1971;32:278-83.
- [2] Gorjanovic-Kramberger K. Uber. prismatische molarwurzeln rezenter und diluvaler Mensch. *Anatomischer Anzeiger*. 1908;32:401-30.
- [3] Keith A. Problems relating to the teeth of the earlier forms of prehistoric man. *Journal of the Royal Society of Medicine*. 1913;6:103-10.
- [4] Shaw JC. Taurodont teeth in South African races. *Journal of Anatomy*. 1928;62:476-98.
- [5] Shifman A, Chanannel I. Prevalence of taurodontism found in radiographic dental examination of 1,200 young adult Israeli patients. *Community Dentistry and Oral Epidemiology*. 1978;6:200-03.
- [6] Lysell L. Taurodontism in both dentitions. *Odontology Review*. 1965;16(4):359-62.
- [7] Shafer WG, Hine MK, Levy MB (2005): A Textbook of Oral Pathology 4<sup>th</sup> edition.
- [8] Haskova JE, Gill DS, Figueiredo JA, Tredwin CJ, Naini FB. Taurodontism – a review. *Dental Update*. 2009;36:235-43.
- [9] Bharti Ramesh, et al. Taurodontism" an endodontic challenge: a case report. 2009;51(3):471-74.
- [10] Jaspers MT, Witkop CJ. Taurodontism, an isolated trait associated with syndromes and X- chromosomal aneuploidy. *American Journal of Human Genetics*. 1980;32:396-413.
- [11] Darwazeh AM, Hamasha AA, Pillai K. Prevalence of taurodontism in Jordanian dental patients. *Dentomaxillofacial Radiology*. 1998;27:163-65.
- [12] Joseph M. Endodontic treatment in three taurodontic teeth associated with 48, XXXY Klinefelter syndrome: a review and case report. *Oral Surgery Oral Medicine Oral Pathology Oral Radiology Endodontology*. 2008;105:670-77.
- [13] Manjunath BS. Taurodontism –A Review on its etiology,prevalence and clinical considerations. *J Clin Exp Dent*. 2010;2(4):187-90.
- [14] Bhat SS. Taurodontism in deciduous molars- A case report. *J Indian Soc Pedo Prev Dent*. 2004;3(2)21-23.

### PARTICULARS OF CONTRIBUTORS:

1. Post Graduate, Department of Pedodontics & Preventive Dentistry, J.S.S Dental College, Mysore, Karnataka, India.
2. Assistant Professor, Department of Oral Medicine & Radiology, Institute of Dental Science, Bhubaneswar, Odisha, India.
3. Professor & HOD, Department of Pedodontics & Preventive Dentistry, J.S.S Dental College, Mysore, Karnataka, India.
4. Professor, Department of Oral Pathology, Institute of Dental Science, Bhubaneswar, Odisha, India.
5. Professor & HOD, Department of Oral Medicine & Radiology, Institute of Dental Science, Bhubaneswar, Odisha, India.

### NAME, ADDRESS, E-MAIL ID OF THE CORRESPONDING AUTHOR:

Dr. Rajat G. Panigrahi,  
N – 5 / 24, I.R.C. Village, Bhubaneswar, Odisha-751015, India.  
Phone : +91 789 4444 789, E-mail : emailrajat@gmail.com

FINANCIAL OR OTHER COMPETING INTERESTS: None.

Date of Submission: **Jan 19, 2014**

Date of Peer Review: **Jul 28, 2014**

Date of Acceptance: **Sep 05, 2014**

Date of Publishing: **Dec 05, 2014**